



Discover Generics

Cost-Effective CT & MRI Contrast Agents



WATCH VIDEO

AJNR

WEB in Partially Thrombosed Intracranial Aneurysms: A Word of Caution

G. Anil, A.J.P. Goddard, S.M. Ross, K. Deniz and T. Patankar

AJNR Am J Neuroradiol 2016, 37 (5) 892-896

doi: <https://doi.org/10.3174/ajnr.A4604>

<http://www.ajnr.org/content/37/5/892>

This information is current as of June 25, 2025.

WEB in Partially Thrombosed Intracranial Aneurysms: A Word of Caution

 G. Anil,  A.J.P. Goddard,  S.M. Ross,  K. Deniz, and  T. Patankar



ABSTRACT

SUMMARY: Despite the proved safety and efficacy of Woven EndoBridge (WEB) flow disruption in conventional intracranial saccular aneurysms, the literature on its use in partially thrombosed intracranial aneurysms is scarce. We report a series of 4 patients in whom partially thrombosed intracranial aneurysms were treated with the WEB. The 2 patients who received additional intraluminal treatment with conventional stents made a good clinical recovery. Meanwhile, those patients who were treated with the WEB alone had fatal rupture of the aneurysm at short- to medium-term follow-up. This small, select case series demonstrates that WEB placement with adjunctive stent placement may be an effective treatment in the management of partially thrombosed intracranial aneurysms, which merits further validation. However, exclusive intrasaccular flow disruption may have an adverse influence on the natural history of this disease.

ABBREVIATIONS: WEB = Woven EndoBridge; WEB-DL = Woven EndoBridge Dual-Layer

Partially thrombosed intracranial aneurysms are distinct from conventional saccular aneurysms and difficult to treat. It is generally accepted that exclusive endosaccular treatment of a partially thrombosed intracranial aneurysm without parent vessel occlusion or stent placement has limited value.¹ Nonetheless, there is some evidence that exclusive endosaccular coiling can stabilize the disease process, provide clinical recovery, and reduce the mass effect in some patients.^{2,3} Besides coil embolization, in recent years, intrasaccular flow disruption with the Woven EndoBridge aneurysm embolization system (WEB; Sequent Medical, Aliso Viejo, California) has emerged as a safe and efficient endosaccular technique for treating intracranial aneurysms.⁴ However, literature on its role in the management of partially thrombosed intracranial aneurysm is scarce.⁵

Case Series

Between May 2013 and August 2015, 40 patients underwent WEB flow disruption at a tertiary referral center in United Kingdom. Four (On-line Table) had a saccular partially thrombosed intra-

cranial aneurysm. With approval of the institutional review board, the aneurysm size, location, clinical and procedural details, imaging follow-up, and outcome of treatment in these 4 patients were retrospectively reviewed.

The patients received endovascular treatment following discussion in a multidisciplinary meeting. The circulating lumen of the 4 partially thrombosed aneurysms had a wide neck and morphology as well as dimensions suitable for WEB embolization. None of the patients had previous treatment. WEB flow disruption was performed with the patient under general anesthesia and systemic heparinization through a transfemoral access in 3 patients and a brachial artery access in 1 patient (patient 4). A carefully sized WEB was deployed through an appropriate catheter. All patients had been receiving aspirin for several months before treatment. Patients 1 and 3 have been kept on life-long aspirin therapy, and they received additional clopidogrel for 3 months after stent placement. Meanwhile, in patients 2 and 4, aspirin was continued for 6 weeks post-WEB embolization. All patients received a periprocedural short course of steroids.

Case 1. A 51-year-old man with left arm ataxia for 8 months presented with acute-onset diplopia, left arm weakness, and dizziness (Fig 1). On examination, he had dysconjugate gaze, grade 4/5 power, dysdiadochokinesis, and exaggerated reflexes in the left upper limb and left-sided past-pointing. CT demonstrated a partially thrombosed aneurysm near the basilar termination with hydrocephalus. MR imaging showed edema in the right thalamus and midbrain. There was some clinical recovery after ventriculoperitoneal shunt insertion.

Received August 18, 2015; accepted after revision September 22.

From the Departments of Neuroradiology (G.A., A.J.P.G., T.P.) and Neurosurgery (S.M.R., K.D.), Leeds Teaching Hospitals, National Health Service Trust, Leeds, UK; and Department of Diagnostic Imaging (G.A.), National University Hospital, Singapore.

Please address correspondence to Gopinathan Anil, MD, Department of Diagnostic Imaging, National University Hospital, 5 Lower Kentridge Rd, Singapore 119074; e-mail: ivyanil10@gmail.com



Indicates article with supplemental on-line table.

<http://dx.doi.org/10.3174/ajnr.A4604>

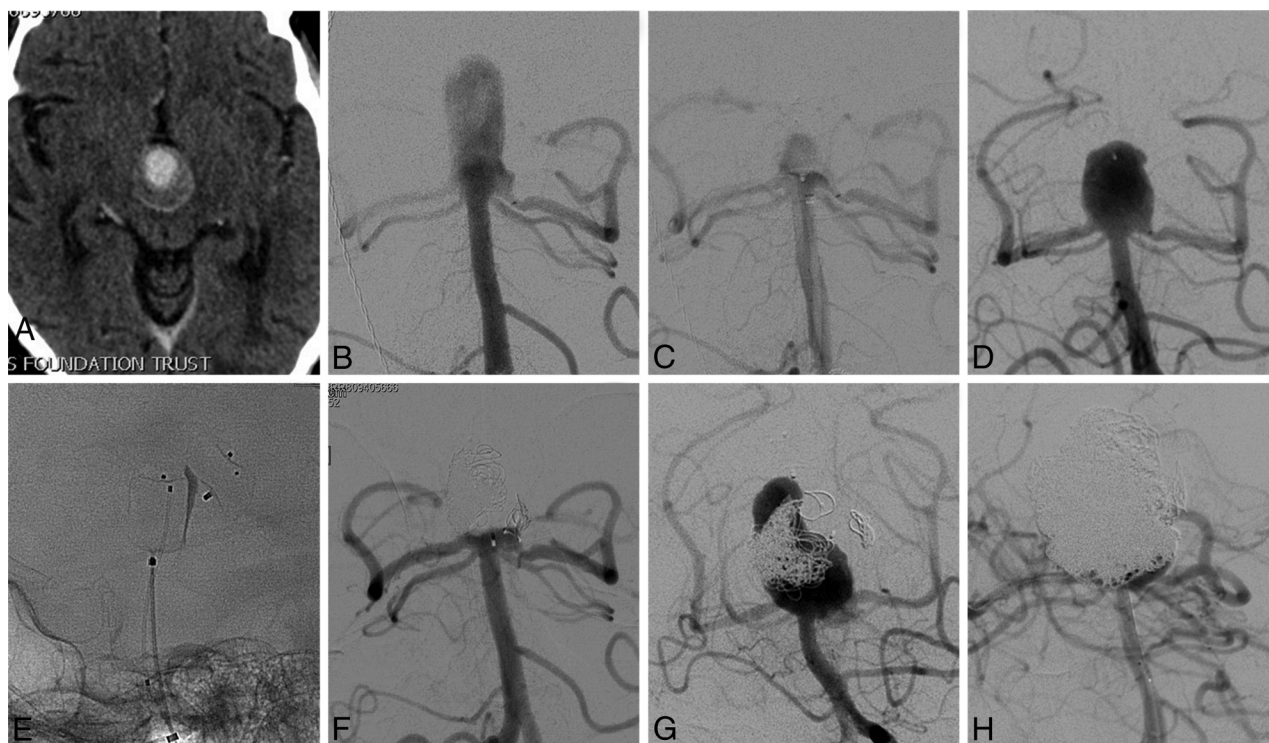


FIG 1. A, Axial CT angiographic image shows a partially thrombosed aneurysm. Pre- (B) and posttreatment (C) angiograms demonstrate technically successful placement of the WEB. D, A large recurrence is seen in this angiogram obtained 9 months following the initial treatment. E, The recurrence is being treated with another WEB device to protect the wide neck, while a microcatheter has been jailed within the aneurysm for coil embolization of the rest of the sac. Note the compaction of the initially deployed WEB. F, Complete occlusion of the recurrence following retreatment with the WEB and coils is seen here. G, The angiogram obtained 4 months later, when the patient presented with subarachnoid hemorrhage, shows a large recurrence with compaction of both the coils and the WEB. H, There is reasonable occlusion of the aneurysm following the second retreatment with balloon-assisted coiling.

Catheter angiography confirmed the aneurysm arising from the proximal P1 segment of the right posterior cerebral artery. The P1 segments were of near-equal size with noncontributory posterior communicating arteries. Angiography after WEB placement showed contrast filling the entire device with marked flow stasis, which continued beyond the venous phase. A small neck residue was not covered by the WEB. Therefore, a stent (LEO Baby; Balt Extrusion, Montmorency, France) was deployed in the right P1 across the neck of the aneurysm. The procedure was uneventful.

Two years from the initial treatment, the thrombosed component of the aneurysm had considerably decreased in size and surrounding edema had nearly resolved. At 28-month angiographic follow up, the residual neck of the aneurysm was stable, with no flow in the aneurysm sac or any thrombotic complications. The neurologic examination findings remained unremarkable.

Case 2. A 62-year-old man with a history of multidrug abuse was transferred to our institute following CT diagnosis of a giant partially thrombosed aneurysm causing triventricular hydrocephalus. He had diplopia and worsening frontal headache. On examination, there was left oculomotor palsy. MRA confirmed the diagnosis. There was extensive perilesional edema in the brain stem and both thalami. Both posterior cerebral arteries arose from the base of the aneurysm with equidominant P1 segments and hypoplastic posterior communicating arteries. A ventriculoperitoneal shunt was placed.

Following successful placement of a WEB within the aneurysm, there was immediate flow stasis with contrast gradually filling up to the proximal two-thirds of the WEB, consistent with satisfactory hemodynamic decoupling of the sac and parent vessel. The aneurysm was stable with minimal filling at the neck on 3-month follow-up MRA. At 6-month follow-up, the aneurysm had circumferentially grown, now measuring $30 \times 29 \times 26$ mm with the WEB eccentrically buried within the thrombus. The recurrent patent sac measured 11×10 mm in width and 15 mm in height with an 8-mm wide neck. The previously deployed WEB was distorted and compacted. The patient refused stent placement. However, he was agreeable to repeat endosaccular treatment.

Retreatment was performed via bifemoral access. Through the left vertebral artery, an 11×9 mm WEB-Dual-Layer (DL) was placed (without detaching) in the proximal sac of the aneurysm, straddling the wide neck, while a microcatheter through the right vertebral artery was jailed in the distal sac. Before the WEB was detached, the patent sac around it was densely packed with coils through the jailed microcatheter. Angiographic exclusion of the aneurysm was complete with no visible intrasaccular flow. MRA performed 2 weeks later showed stable occlusion.

Four months from retreatment, he presented with World Federation of Neurosurgical Societies grade IV SAH. At CT, the aneurysm demonstrated an overall enlargement in size with luminal recurrence. The previously placed coils and WEBs were displaced

and compacted peripherally in the thrombus. Balloon-assisted coiling was performed to secure this acutely ruptured aneurysm. However, due to the wide neck, complete occlusion could not be achieved. The procedure was concluded with the intention of performing a delayed stent-assisted coiling. Unfortunately, his clinical deterioration continued, and 2 weeks later he died following yet another rebleed.

Case 3. A partially thrombosed anterior communicating artery aneurysm was reported in a 56-year-old male patient who had a CT scan for acute delirium. He had a short-term memory deficit. Comorbidities included hypertension, hypertriglyceridemia, peripheral vascular disease, diabetes mellitus, and ischemic heart disease. He was on life-long aspirin therapy.

At angiography, the left anterior cerebral artery supplied both anterior cerebral artery territories with a hypoplastic right A1 segment. The aneurysm was located at the A1 bifurcation, straddling the origin of both A2 segments. The initial WEB placement was slightly oblique to the long axis of the aneurysm, leaving the left edge of the neck uncovered. Further attempts to resheath the WEB not only failed but tilted it more. The device encroached into the proximal right A2 and occluded it. The WEB was deployed in that position. Attempts to cannulate the right A2 for placing a stent failed. The patient was given intravenous aspirin. Although there was no antegrade flow into the right A2, a right carotid angiogram showed modest retrograde filling of the right anterior cerebral artery. At the end of the procedure, there was a small residual neck along the left edge with the WEB satisfactorily occluding the rest of the aneurysm. The patient awoke without new neurologic deficits. He was hypertensive (mean, >120 mm Hg) and was started on clopidogrel besides aspirin. The same evening, he developed right arm sensory and motor weakness with right facial droop. MR imaging revealed multiple small cortical infarcts in the right anterior cerebral artery territory. The right arm weakness fully recovered within 48 hours while the facial weakness improved gradually.

Follow-up MRA, 3 months postprocedure showed an increase in the size of the residual neck, while both A2 segments were patent. The displaced and compacted WEB was more transverse within the thrombus. This early recurrence was successfully treated by stent-assisted coiling with a 3.5×20 mm Acclino-flex (Acandis, Pforzheim, Germany) stent deployed from the right A2 to the left A1. The procedure was uneventful. At the 17-month follow-up MRA, the partially thrombosed intracranial aneurysm had slightly decreased in size with no evidence of intrasaccular flow, while the patient's neurologic function remained stable.

Case 4. A partially thrombosed superior cerebellar artery aneurysm was detected on CT in a 59-year-old woman with multiple episodes of TIA for 2 years. She was started on aspirin therapy and referred to our institution. She had been completely cured of breast cancer 12 years earlier.

The angiographic outcome of the WEB embolization of the aneurysm was excellent. Contrast filled the entire WEB with stasis. There was no flow beyond or around the device and no procedure-related complications. The patient was asymptomatic at 6-week postprocedural clinical evaluation. She defaulted from further follow-up. Thirteen months later, she was admitted to a

peripheral hospital with a World Federation of Neurosurgical Societies grade V SAH and died there. A CT performed following the bleed showed that the treated aneurysm had grown, measuring $23 \times 22 \times 19$ mm with the patent lumen much larger than at the time of presentation. The compacted WEB was lying eccentrically, buried in the mural thrombus.

DISCUSSION

Partially thrombosed intracranial aneurysms are a diverse group associated with organized thrombus formation. The thrombus could be intraluminal or intramural. Intraluminal thrombosis is the function of a critical ratio between the volume of the aneurysm and its neck diameter.⁶ Hence, larger aneurysms are more likely to thrombose. Meanwhile, intramural thrombus is thought to result from recurrent nontransmural dissections that lead to subadventitial bleeding and organized hematoma formation.¹ The adventitial aspect of a partially thrombosed aneurysm is believed to be the epicenter of the pathology.⁷ Partially thrombosed intracranial aneurysms mostly (60%–91%) present with symptoms of mass effect.^{2,8,9} In comparison, embolic phenomena are infrequent.⁹ Several patients had nonspecific symptoms, with headache being most common. Some symptoms mimicked SAH, a presentation postulated to be secondary to intramural dissection.⁸ True SAH is rare with partially thrombosed intracranial aneurysms (0%–10%).^{1,2,8,9}

Complete excision of the lesion and reconstruction of the vessel wall would be the ideal treatment for a partially thrombosed intracranial aneurysm; however, it is seldom feasible. Treatments such as direct clipping of the neck, parent vessel occlusion with or without bypass, endosaccular coil embolization with or without stent placement, and parent vessel flow diversion have been described with variable results.^{8–10} Following occlusion of partially thrombosed aneurysms with exclusive endosaccular coiling, high recanalization rates (60%–75%) and failure of relief from symptoms of mass effect have been reported, often mandating retreatment.^{9,10}

Meanwhile, a few other small case series found these aneurysms to be much less vulnerable to recanalization (approximately 30%) following coil embolization.^{2,8} They also reported relief of symptoms and stabilization of the clinical evolution of the disease after coiling. Surgery was ruled out in our patients with aneurysms in the posterior circulation, due to their location, size, and circumferential thrombus. Meanwhile, in the patient with an anterior circulation aneurysm, the risk of an operation could not justify its use as the first treatment option. Parent vessel occlusion was unacceptable because it would have required sacrifice of the solitary A1 in patient 3 and the distal basilar artery in the remaining patients. We did not use flow diverters due to the high risk of perforator infarcts in the distal basilar artery in patients 1, 2, and 4, and in patient 3, a flow diverter could potentially occlude one of the A2 segments. Intracranial stents with their ability to modify the hemodynamic forces and effect a reconstruction of the parent artery, within certain limits, have been useful in the treatment of partially thrombosed intracranial aneurysms.^{11,12} We had considered this option for all the patients from this series. Patients 2 and 3 with bifurcation aneurysms were potential candidates for double-stent placement in a Y-shaped configuration. However, in

view of patient factors and the clinical scenario, we offered the least aggressive management of exclusively endosaccular treatment and close surveillance as the first option. Patient 2 had refused to consent to stent placement, and he was unlikely to comply with long-term antiplatelet therapy. In patient 3, although the primary aneurysm was at the left anterior cerebral artery bifurcation, the recurrence was eccentric and had a sidewall aneurysm-like configuration. Hence, it could be satisfactorily treated with a single stent-assisted coiling.

In conventional aneurysms, the efficiency and safety of WEB flow disruption is comparable with coil embolization.⁴ Because the aneurysms from our study had a wide neck, complete occlusion with coils was not possible without stent assistance. Conceptually, the WEB combines the advantage of flow diversion (diseased arterial wall treatment and stable occlusion) and selective intrasaccular embolization without the need for long-term antiplatelet therapy.¹³ With the WEB, the surface exposed at the neck is smoother, compared with coils, providing potentially better support for neoendothelialization. These attributes prompted us to use the WEB in partially thrombosed intracranial aneurysms. Because the thrombus toward the luminal aspect in these aneurysms is considered old and organized, we thought it would adequately buttress the WEB. Unfortunately, despite the satisfactory immediate angiographic outcome, exclusive intrasaccular flow disruption did not provide stability to the aneurysm in any of the 3 cases as noted from their early recurrence. The WEB was displaced from its initial position in all of them. This could be secondary to lysis of the thrombus after treatment.¹³ It may be argued that the device displacement would not have happened if we had allowed further oversizing of the WEB. However, the concerns of potential distortion of the device geometry and device protrusion into the parent vessel prevented us from deviating too much from the manufacturer's sizing recommendation.

All the recurrences were in the region corresponding to the previously treated neck and proximal sac that now appeared more bulbous than at the time of treatment. Hence, we believe that early growth at the neck of the aneurysm could have contributed to the recurrence. Before complete thrombosis and neoendothelialization, even a marginal increase in the size of the patent sac can result in loss of wall approximation of the WEB and make it susceptible to migrating into the thrombus with arterial pulsation ("water-hammer effect"). This mechanism of failure of flow disruption due to the movement of the WEB could explain the dismal performance of exclusive endosaccular treatment with the WEB compared with coils.^{8,9} Because the WEB is a single composite plug, loss of wall approximation even over a small area can allow the whole device to move en masse. Meanwhile, a coil mass is made up of several individual coils, with each potentially interacting with the wall of the aneurysm at innumerable points along their lengths. Probably, an increase in the size of the sac has a greater impact on the WEB than on coils.

We are curious about the fatal SAH in both patients who did not receive adjunctive stent placement. Partially thrombosed intracranial aneurysms have a low propensity to bleed, and following treatment, SAH is almost unknown.^{1,2,8,9} Even exclusive coil embolization delivers this favorable effect. On the contrary, our case series seems to suggest that exclusive endosaccular treatment

with the WEB has an unfavorable impact on the natural history of this disease. We suspect the earlier described potential for the WEB to move en masse within the partially thrombosed intracranial aneurysm following recurrence might have contributed to the mechanism of rupture. Alternatively, a ball valve mechanism, in which the WEB acts like a trapdoor that allows blood to enter the sac but not escape (or escape partially), may have been operational. Theoretically, a flow disruptor like the WEB is an intrasaccular version of a flow-diverter stent, and a comparable principle operates in the way it achieves occlusion of an aneurysm.¹³ Hence, an aggressive thrombus-associated autolysis of the aneurysm wall, as described before with flow diverters, cannot be ruled out.¹⁴ It would not be unreasonable to expect interplay of several or all of these postulated factors as the cause of SAH in patients from this series.

Unlike patients 2 and 4, the 2 patients who received adjunctive stent placement had excellent outcomes. This observation seems to suggest that WEB flow disruption in a partially thrombosed intracranial aneurysm could be an extremely promising treatment option when combined with parent vessel remodeling with stents. Stents provide the scaffold for endothelial growth and vessel healing. Besides metallic coverage that disrupts the flow into an aneurysm, the hemodynamic changes secondary to stent-induced alteration in vessel geometry can also reduce the inflow. From our limited experience, it appears that the light flow-diverter effect of the stent complements the intrasaccular flow disruption by the WEB.

Notwithstanding the limitations of the small sample size and the anecdotal nature of this case series, exclusive intrasaccular flow disruption does not seem to be an appropriate treatment for partially thrombosed intracranial aneurysms. Although the mechanism is not clear, it can probably have an unfavorable influence on the natural history of this disease, which has not been reported before with other treatment options. However, combining intrasaccular flow disruption with adjunctive stent placement may be a novel method of treating this complex disease with favorable long-term outcome. Further research is required to better evaluate this endovascular therapeutic option for partially thrombosed intracranial aneurysms.

Disclosures: Anthony J.P. Goddard—*UNRELATED: Consultancy:* Codman, *Comments:* for stent retriever development work, educational lectures, and advice on product development; *Payment for Lectures (including service on Speakers Bureaus):* Codman; *Travel/Accommodations/Meeting Expenses Unrelated to Activities Listed:* Codman, Stryker, *Comments:* travel to international meetings along with accommodations. Tunil Patankar—*UNRELATED: Payment for Lectures (including service on Speakers Bureaus):* Medtronic, Sequent Medical, *Comments:* lecture at Medtronic annual meeting; *Travel/Accommodations/Meeting Expenses Unrelated to Activities Listed:* Sequent Medical, *Comments:* Travel grant to present at Val d'Isere, France, 2013, and Cerebrovascular Complications Conference meeting, Jackson Hole, Wyoming, 2014; *Other:* proctor for Sequent Medical, Codman, and Stryker, *Comments:* proctor for the WEB and the PulseRider and Surpass stents.

REFERENCES

1. Krings T, Alvarez H, Reinacher P, et al. **Growth and rupture mechanism of partially thrombosed aneurysms.** *Interv Neuroradiol* 2007; 13:117–26 [Medline](#)
2. Roccatagliata L, Guédin P, Condette-Auliac S, et al. **Partially thrombosed intracranial aneurysms: symptoms, evolution, and therapeutic management.** *Acta Neurochir (Wien)* 2010;152:2133–42 [CrossRef Medline](#)

3. van Rooij WJ, Sluzewski M. **Unruptured large and giant carotid artery aneurysms presenting with cranial nerve palsy: comparison of clinical recovery after selective aneurysm coiling and therapeutic carotid artery occlusion.** *AJNR Am J Neuroradiol* 2008;29:997–1002 [CrossRef Medline](#)
4. Papagiannaki C, Spelle L, Januel AC, et al. **WEB intrasaccular flow disruptor: prospective, multicenter experience in 83 patients with 85 aneurysms.** *AJNR Am J Neuroradiol* 2014;35:2106–11 [CrossRef Medline](#)
5. Pierot L, Liebig T, Sychra V, et al. **Intrasaccular flow-disruption treatment of intracranial aneurysms: preliminary results of a multicenter clinical study.** *AJNR Am J Neuroradiol* 2012;33:1232–38 [CrossRef Medline](#)
6. Black SP, German WJ. **Observations on the relationship between the volume and the size of the orifice of experimental aneurysms.** *J Neurosurg* 1960;17:984–90 [CrossRef Medline](#)
7. Schubiger O, Valavanis A, Wichmann W. **Growth-mechanism of giant intracranial aneurysms: demonstration by CT and MR imaging.** *Neuroradiology* 1987;29:266–71 [CrossRef Medline](#)
8. Cho YD, Park JC, Kwon BJ, et al. **Endovascular treatment of largely thrombosed saccular aneurysms: follow-up results in ten patients.** *Neuroradiology* 2010;52:751–58 [CrossRef Medline](#)
9. Yang K, Park JC, Ahn JS, et al. **Characteristics and outcomes of varied treatment modalities for partially thrombosed intracranial aneurysms: a review of 35 cases.** *Acta Neurochir (Wein)* 2014;156:1669–75 [CrossRef Medline](#)
10. Ferns S, van Rooij W, Sluzewski W, et al. **Partially thrombosed intracranial aneurysms presenting with mass effect: long-term clinical and imaging follow-up after endovascular treatment.** *AJNR Am J Neuroradiol* 2010;31:1197–205 [CrossRef Medline](#)
11. Cekirge HS, Yavuz K, Geyik S, et al. **A novel “Y” stent flow diversion technique for the endovascular treatment of bifurcation aneurysms without endosaccular coiling.** *AJNR Am J Neuroradiol* 2011;32:1262–68 [CrossRef Medline](#)
12. Fischer S, Vajda Z, Aguilar Perez M, et al. **Pipeline embolization device (PED) for neurovascular reconstruction: initial experience in the treatment of 101 intracranial aneurysms and dissections.** *Neuroradiology* 2012;54:369–82 [CrossRef Medline](#)
13. Mine B, Pierot L, Lubicz B. **Intrasaccular flow-diversion for treatment of intracranial aneurysms: the Woven EndoBridge.** *Expert Rev Med Devices* 2014;11:315–25 [CrossRef Medline](#)
14. Kulcsár Z, Houdart E, Bonafé A, et al. **Intra-aneurysmal thrombosis as a possible cause of delayed aneurysm rupture after flow-diversion treatment.** *AJNR Am J Neuroradiol* 2011;32:20–25 [CrossRef Medline](#)