

Generic Contrast Agents

Our portfolio is growing to serve you better. Now you have a *choice*.



[VIEW CATALOG](#)

AJNR

Combined Endovascular and Surgical Approach for the Treatment of Palpebral Arteriovenous Malformations: Experience of a Single Center

F. Clarençon, R. Blanc, C.-J. Lin, C. Mounayer, O. Galatoire, S. Morax, J. Moret and M. Pötin

This information is current as of May 30, 2025.

AJNR Am J Neuroradiol 2012, 33 (1) 148-153

doi: <https://doi.org/10.3174/ajnr.A2735>

<http://www.ajnr.org/content/33/1/148>

ORIGINAL RESEARCH

F. Clarençon
R. Blanc
C.-J. Lin
C. Mounayer
O. Galatoire
S. Morax
J. Moret
M. Piotin



Combined Endovascular and Surgical Approach for the Treatment of Palpebral Arteriovenous Malformations: Experience of a Single Center

BACKGROUND AND PURPOSE: Palpebral AVMs (pAVMs) are rare vascular lesions for which the treatment is challenging. Our aim was to present the technical aspects of the presurgical treatment by interventional neuroradiology of pAVMs and to report the clinical and angiographic results of combined (interventional neuroradiology/surgery) treatment of these malformations.

MATERIALS AND METHODS: Nine patients (5 females, 4 males) with a mean age of 22 years (range, 12–35 years) were treated in our department from December 1992 to April 2007 for superficial pAVMs. Seven patients presented with isolated pAVMs, while 2 had hemifacial AVMs. Ten TAE procedures, by using a liquid embolic agent (glue or Onyx) or microparticles, were performed in 7 patients. Six patients underwent absolute alcohol, glue, or sclerotic agent injection by direct puncture in 8 procedures. Clinical and angiographic follow-up were performed with a mean delay of, respectively, 6.3 and 5 years.

RESULTS: Three patients had a single EVT. Iterative procedures were performed in 5 patients. In 1 patient, EVT was not performed because of the risk of occlusion of the central retinal artery. No complication occurred except 1 case of transient palpebral hematoma. No visual acuity loss related to an endovascular procedure was reported. Exclusion of the AVMs at the end of the procedure was >75% in all cases and total in 3/8 cases. All the patients except 2 underwent at least 1 surgical procedure after the embolization. Good clinical regression of the mass was obtained in all patients at long-term follow-up.

CONCLUSIONS: Combined endovascular and surgical treatment of pAVMs is an effective and safe technique with good clinical results at long-term follow-up.

ABBREVIATIONS: AV = arteriovenous; AVF = arteriovenous fistula; CRA = central retinal artery; DP = direct puncture; ECA = external carotid artery; EVT = endovascular treatment; IMA = internal maxillary artery; *n*-BCA = *n*-butyl 2-cyanoacrylate; OA = ophthalmic artery; pAVM = palpebral arteriovenous malformation; PVA = polyvinyl alcohol; SOV = superior ophthalmic vein; TAE = transarterial embolization

According to the International Society for the Study of Vascular Anomalies, pAVMs are rare facial high-flow superficial vascular malformations.¹ Their origin is not well-established, but they seem to be congenital.^{2,3} They correspond to an abnormal connection between feeding artery branches and dilated draining veins through a net of dysplastic vessels: the so-called nidus.^{4,5} Superficial AVMs are serious malformations because they are hemodynamically active.^{6,7} Depending on their size and aggressiveness, treatment is proposed because they may cause hemorrhage and/or may be responsible for deformity.⁸ The management of such AVMs is challenging because of the close relationship of these malformations with the CRA.⁹ The high risk of recurrence/progression should also be considered in the management of such superficial AVMs.⁸

We report our experience of presurgical endovascular/per-

cutaneous management of 9 consecutive patients with pAVMs referred to our institution for treatment.

Materials and Methods

We retrospectively reviewed the charts of 9 consecutive patients (5 female and 4 male, 12–35 years of age; mean, 22 years) treated for angiographically proved pAVMs in our department from December 1992 to April 2007. The AVM was limited to the palpebral area in 7 patients, while 2 others had hemifacial AVMs. All the pAVMs were unilateral. Eight were located on the upper eyelid; only 1 arose from the inferior eyelid. The mean duration from initial clinical symptoms to diagnosis and treatment was 15.1 years (range, neonate to 35 years).

Clinical symptoms were assessed for all patients by both an ophthalmologist and a neuroradiologist, including visual field, visual acuity, oculomotricity, and cutaneous examination of the eyelids.

Four of the 9 patients had a previous surgical intervention (mean delay, 4 years; range, 2–6 years). Two patients had 2 prior surgical treatments. One patient had a previous embolization with PVA microparticles through the IMA.

All patients underwent DSA with selective opacification of both ICAs and ECAs in anteroposterior and lateral views centered on orbital and palpebral areas. DSA was retrospectively reviewed in consensus by 2 neuroradiologists (F.C. and R.B.). Feeding arteries, draining veins, and morphology of the nidus were detailed. Endovascular/percutaneous treatment was performed in 8/9 patients. In 1 patient, EVT failed because of the risk of occlusion of the CRA (patient 1).

Received November 17, 2010; accepted after revision April 26, 2011.

From the Departments of Interventional Neuroradiology (F.C., R.B., J.M., M.P.) and Ophthalmology (O.G.), Fondation Adolphe de Rothschild, Paris, France; Department of Neuroradiology (F.C.), Pitié-Salpêtrière Hospital, Paris, France; Department of Radiology (C.-J.L.), Taipei Veterans General Hospital, National Yang Ming University School of Medicine, Taipei, Taiwan, R.O.C.; and Department of Neuroradiology (C.M.), University Hospital of Limoges, Limoges, France.

Please address correspondence to Frédéric Clarençon, MD, Neuroradiology, Pitié-Salpêtrière Hospital, 47 Bd de l'Hôpital, 75013, Paris, France; e-mail: fredclare5@msn.com

 Indicates article with supplemental on-line tables.

<http://dx.doi.org/10.3174/ajnr.A2735>

Table 1: Clinical data

Patient	Sex	Age Sympt (yr)	Age (DSA/Tx) (yr)	Sympt	Bleeding	Puberty Context	Pregnancy	Location	Schöbinger Grade ¹⁴	Associated Facial AVM
1	F	35	35	Mass	No	No	No	Sup R Ext canthus	2	—
2	M	18	24	No coloration, pulsatile mass	No	No	—	Sup R	2	—
3	F	19	30	Pulsatile mass, proptosis, visual blurring	No	No	No	Sup R. Ext canthus	2	—
4	F	19	19	Pulsatile mass	No	No	No	Sup R	2	—
5	F	27	27	Mass	No	No	No	Sup R	2	R cheek
6	F	13	13	Mobile and pulsatile mass	No	Yes	No	Inf R	2	—
7	M	12	16	Small pulsatile mass	No	Yes	—	Sup R + periorbital	2	R cheek + labial AVM
8	M	8	12	Thrill, red coloration	Yes	Yes	—	Sup R	3	—
9	M	New born	21	Post-trauma (2 years ago)	Yes	No	—	Sup L	3	—

Note:—Sympt indicates symptoms; —, not applicable; Tx, treatment; Inf = Inferior; R, right; L, left; Sup, Superior; Ext, external.

Table 2: Schöbinger's classification of superficial AVMs¹⁴

Grade	Description
I	Quiescent lesion, pink or blue cutaneous stain, warm lesion, AV shunt on Doppler sonography
II	Expansive lesion, pulsatile lesion, thrill; dilated draining veins
III	Grade II + necrosis, infection, hemorrhage or pain
IV	Grade III + cardiac failure

Seven patients had TAE during 10 procedures, 6 patients were treated by DP in 8 procedures, and 5 patients were treated by both techniques. The venous approach was attempted in 1 patient but failed (patient 8). Three patients had a single procedure, 3 others had 2 procedures, and 3 patients had 3 interventions. For TAE, 8 procedures were performed with *n*-BCA injection, 1 with Onyx-18 (ev3, Irvine, California), and another with PVA microparticles (Contour, 350–500 μ m; Boston Scientific, Fremont, California) through the IMA. Four patients were treated by DP, 5 with absolute alcohol, 3 with *n*-BCA, and 1 with Ethibloc (Ethicon, Norderstet, Germany).

Perioperative or postprocedural complications were systematically assessed.

Clinical follow-up was obtained for all patients with a mean delay of 6.3 years. Persistence or recurrence of a pulsatile mass, residual mass size, bleeding episodes, visual acuity, and oculomotricity were assessed by both an ophthalmologist and a neuroradiologist. When there was a doubt about a local recurrence at clinical examination, a Doppler sonography was performed (in 1 case, patient 7). Angiographic follow-up was obtained for 5/9 patients with a mean delay of 5 years.

Neither approval of the institutional review board nor patient informed consent is required by the ethics committee of our institution for retrospective analyses of patients' records and imaging data.

Results

Clinical Data

Clinical data are summarized in Table 1.

Seven patients presented with an isolated pulsatile mass of the eyelid (Schöbinger grade II, Table 2).¹⁰ Two patients (patients 8 and 9) experienced hemorrhage (Schöbinger grade III). In 3 patients, the mass appeared or worsened during puberty. In 1 patient (patient 9), the mass worsened after a local

Table 3: Summary of clinical ocular symptoms before treatment

Patient	Pretreatment Ophthalmologic Examination
1	VA: N; OM: N; ptosis
2	VA: N; OM: N
3	Visual blurring; OM: N; blepharoptosis
4	VA: N; OM: N; blepharoptosis
5	VA: N; OM: N
6	VA: N; OM: N
7	VA: N; OM: N; blepharoptosis
8	Bleeding episodes; pain; OM: N; decrease of R eye visual acuity; blepharoptosis
9	Bleeding episodes; VA: N; OM: N; blepharoptosis

Note:—R indicates right; L, Left; VA, visual acuity; OM, oculomotricity; N, normal.

trauma. No case of appearance or worsening of the pAVM was noticed during pregnancy.

No patient presented with cardiac failure related to the AVM.

Palpebral ptosis was observed in 6/9 patients; decreased visual acuity, in 2/9; and pain, in 1/9 patients. Neither limitation in oculomotricity nor chemosis nor proptosis was seen (Table 3).

Angiographic Data

On DSA, detailed review of the angioarchitecture of the pAVMs showed that all the malformations except 1 were fed by palpebral branches arising from the OA (Table 4). In 3 cases, arterial feeders arose from the superficial temporal artery; in 2 cases, from the sphenopalatine; in 2 other cases, from the deep temporal arteries; in 1 case, from the angular artery; and in 1 last case, from the infraorbital artery (Fig 1). Nidus appearance was compact in all cases. In 8 cases, nidus size was inferior to 3 cm; in 1 case, it was superior to 3 cm. Venous drainage was unique in 5 cases and multiple in 4 cases. Draining veins were the SOV in 8 cases, the facial vein in 6 cases, the superficial temporal vein in 1 case and the frontal vein in 1 case (Fig 2). No aneurysm (neither arterial, nidal, nor venous) was observed in the pAVMs. No stenosis on the draining veins was noticed.

Table 4: Angiographic findings of pAVMs

Patient	Feeding Arteries	Venous Drainage	Nidus
1	Palpebral branch of OA	SOV	Small (<3 cm)
2	Branches of OA; branches of superf. temp. a; supraorbital a	SOV; temp sup v, facial v	Small (<3 cm)
3	Lachrymal a (from OA), branch from superf. temp. a; branch from anterior deep temp. a, branches from infra-orbital a	Dilated SOV (7 mm)	Small + direct fistula
4	Supraorbital a, anterior deep temporal branch	SOV	Compact, 2.5 cm
5	Palpebral branches from R sphenopalatine a, angular a	Facial v, SOV	Small and compact
6	Branches from sphenopalatine a, palpebral a from OA	Direct via SOV, reflux in facial v	Compact
7	Palpebral a from OA; branches from superf. temp. a	SOV	Compact; 4 cm
8	Palpebral a from OA	Facial v	Small (<3 cm)
9	Palpebral a from OA, branches from superf. temp. a	SOV, facial v, frontal v	Compact; 2.5 cm

Note:—a indicates artery; v, vein; temp., temporal; superf., superficial.

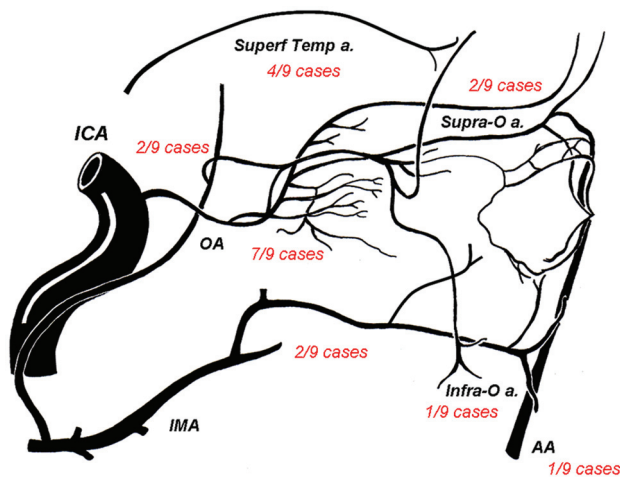


Fig 1. Schematic representation of the distribution of the main feeding arteries of the pAVMs in our series. For each feeding artery, its frequency in vascularization of the AVM in our series is noted in red. IMA indicates internal maxillary artery; ICA, internal carotid artery; Superf Temp a, superficial temporal artery; Infra-O a, infraorbital artery; OA, ophthalmic artery; AA, angular artery.

Neuroradiologic Procedures

All data relative to the procedures are summarized in On-line Table 1.

Endovascular procedures were performed presurgically in all patients except 2. For these 2 patients (patients 3 and 8), postembolization surgery was not performed because of the small size of the malformation and a satisfying esthetic result.

Ten TAE procedures by using glue (8/10), particles (1/10), or Onyx-18 (1/10) were performed in 7 patients. Six patients underwent DP in 8 procedures by using absolute alcohol (5/8), *n*-BCA (2/8), or Ethibloc (1/8) injection. Three patients had a single EVT. Iterative procedures (from 2–3 procedures) were performed in 5 patients. In 1 patient (patient 1), EVT failed because of the risk of potential occlusion of the CRA. In another patient, transvenous embolization also failed (patient 8).

Immediate Angiographic Results

Immediate postembolization angiograms showed complete angiographic exclusion of the pAVMs in 3/8 patients. In the remaining 5 patients, >75% of the AVM nidus was angiographically excluded at the end of the procedure (On-line Table 2).

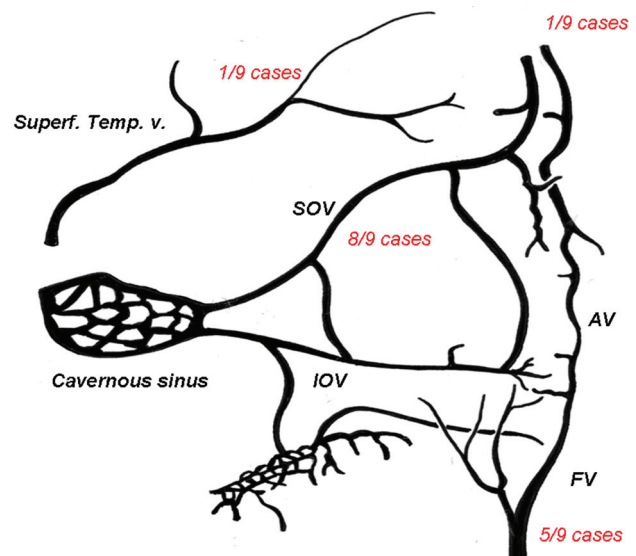


Fig 2. Schematic representation of the distribution of main draining veins of the pAVMs in our series. For each draining vein, its frequency in vascularization of the AVM in our series is noted in red. FV indicates facial vein; Superf Temp. V, superficial temporal vein; IOV, inferior ophthalmic vein; AV, angular vein.

Postembolization Surgical Treatment

All patients except 2 (patients 3 and 8) underwent a surgical excision of the pAVM performed by ophthalmologists specialized in orbital surgery and oculoplastics, after percutaneous treatment/EVT. Four patients underwent surgery between days 1 and 2; two patients had delayed surgery, respectively, at 1 and 7 months (patients 2 and 9), because despite the small size of the their pAVMs, the sole EVT could not cure the lesion, leading to a residual unesthetic mass observed at early clinical follow-up. Finally, 1 patient had a surgery 8 years after a first attempt of embolization of the pAVM because of a growing mass.

Surgery was performed with the patient under general anesthesia. The peritumoral area was infiltrated by using saline to facilitate the surgical dissection. An incision was made in the superior lid line to the lateral canthus followed by a subcutaneous dissection. The orbicularis muscle was also dissected to expose the vascular malformation. The vascular mass was dissected, and a total excision was performed after coagulation of its feeding pedicles. The levator muscle was then reattached to the superior tarsus with 3 stitches by using Vicryl 5.0 surgical thread (Ethicon, Auneau, France). The orbicularis

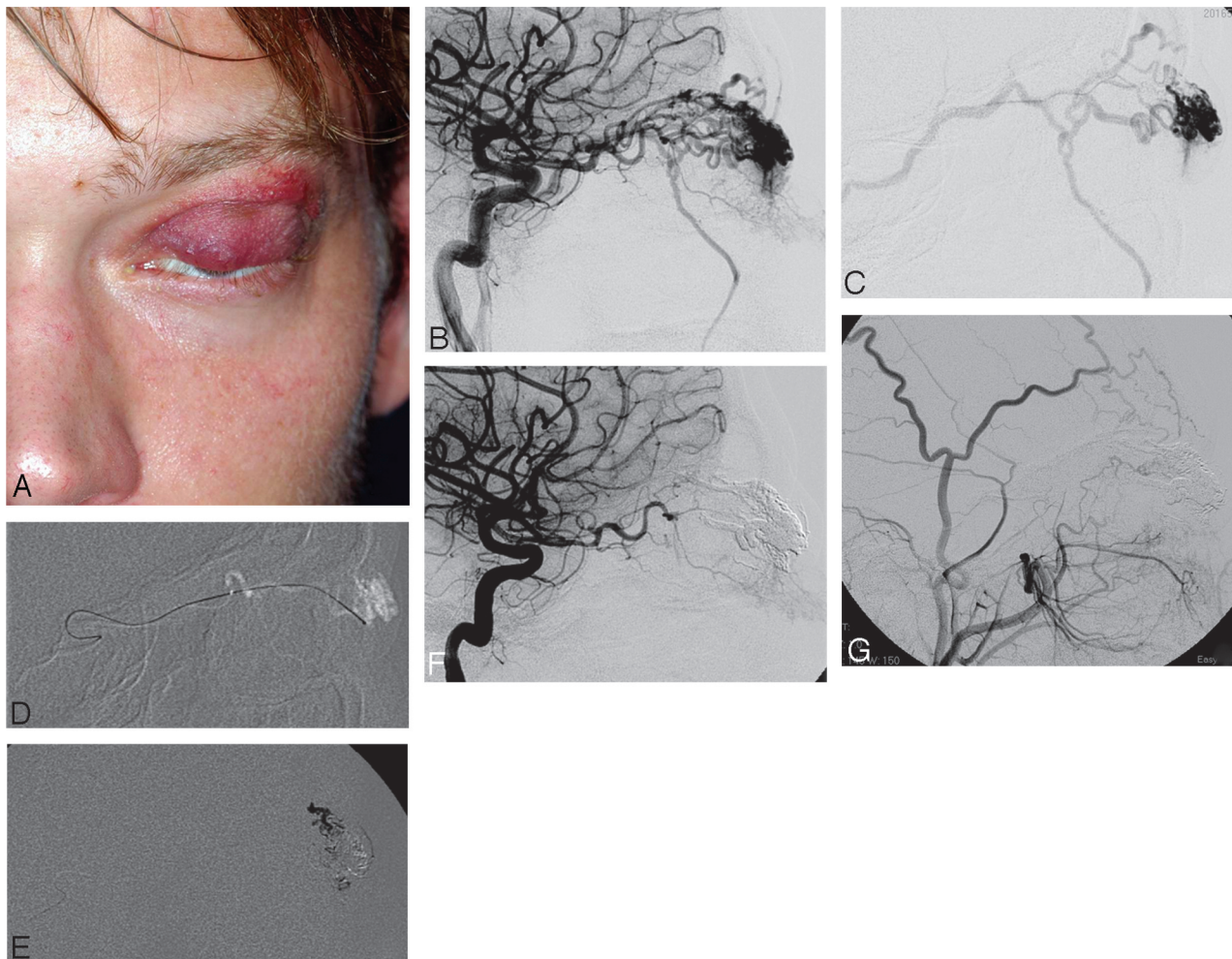


Fig 3. Illustrative case (patient 9). A 21-year-old patient with a left superior eyelid AVM. A, Photograph, frontal view. B, Left ICA angiogram, lateral view, arterial phase. C, Left ICA angiogram, lateral view, venous phase. D, Selective microcatheterism of the OA. E, Onyx-18 injection through a palpebral branch of the OA and superficial temporal artery (not shown). F, Control left ICA angiogram. G, Control left ECA angiogram.

muscle was sutured with Vicryl 6.0 surgical thread, and the skin was closed by using silk thread 6.0.

Additional surgery for blepharoptosis was performed in 3 patients. In these cases, the levator muscle was reattached to the anterior tarsal surface and the excessive skin was removed when necessary.

Illustrative Case

Case 9 (Fig 3). A 21-year-old man was referred to our institution for the management of a recently appearing mass of the left superior eyelid. The patient reported an episode of eyelid trauma 2 years ago. Clinically, the palpebral mass had a red coloration and was pulsatile (Fig 3A). DSA showed a pAVM located in the medial part of the left superior eyelid, fed, respectively, by palpebral branches from the third segment of the OA (Fig 3B) and by the superficial temporal artery branches (not shown). The nidus was small (25 mm) and compact, with no aneurysm inside. Venous drainage was supported by the SOV, facial vein, and frontal vein (Fig 3C). Microcatheterism of the OA was performed by using a 1.5 Ultra-Flow microcatheter (ev3). The microcatheter was positioned in the distal part of the superior palpebral branch (Fig 3D), and intranidal injection of Onyx-18 was performed under sub-

tracted fluoroscopy (Fig 3E). Palpebral feeders from the frontal branch of the superficial temporal artery were also catheterized and embolized with Onyx-18 (not shown).

Immediate postprocedure lateral angiograms of the left ICA and ECA showed a total exclusion of the AVM (Fig 3F, -G). Surgical excision of the pAVM was performed 1 month after the endovascular procedure. At 60-month follow-up, the pAVM had almost totally disappeared clinically (not shown).

Clinical and Angiographic Follow-Up

All data relative to clinical and angiographic follow-up in our series are summarized in On-line Table 2.

No complication occurred during or after the endovascular procedure except 1 transient palpebral hematoma (patient 3). Mean delay for clinical follow-up was 6.3 years (range, 1.5–13 years). Total or quasitotal clinical disappearance of the pAVM was observed in all cases at long-term follow-up. During the clinical follow-up, 2 patients presented with a recurrence, with a mean delay of 6 years (3 and 9 years); a second procedure was performed with a good clinical outcome and without recurrence at long-term follow-up. For 1 patient, the persistence of a remnant at 1 year after the first treatment led to a new treat-

ment by DP with satisfying regression of the mass at 13-year follow-up.

Eyelid functionality was evaluated by ophthalmologists at clinical follow-up and was satisfying in all cases.

Angiographic follow-up was performed in 5/9 patients with a mean delay of 5 years (range, 5 months to 10 years). In all cases (5/5), disappearance or only a small remnant of the nidus was observed.

Discussion

Superficial AVMs: Pathophysiology, Natural History, and Classification

The origin of superficial AVMs, generally, and pAVMs, specifically, has not been clearly established. Some authors hypothesized a congenital origin of these lesions.³ Rare genetic mutations, like ones of the *RASA1* gene, have been reported as being responsible for the development of some of superficial AVMs.¹⁰ Trauma has been described as a potential cause of the appearance or worsening of superficial AVMs,⁸ including pAVMs.¹¹ In the series of Warrier et al,¹² traumas were noticed in as frequently as 50% of the cases. Nevertheless, in larger series on superficial AVMs, causal effects were found in only 20% of the cases.¹³ Schöbinger et al¹⁴ established a classification based on clinical manifestations and complications of superficial AVMs: Grade I corresponded to a blue plane cutaneous lesion; grade II lesions were pulsatile subcutaneous masses; in grade III, hemorrhage was observed; and finally, grade 4 was characterized by a cardiac repercussion of the AVM (Table 2).

Puberty and pregnancy are other causes in the growth of the pAVMs, suggesting a hormonal influence on the evolution of these malformations.

Palpebral AVMs may be isolated or associated with other facial locations that can lead to hemifacial AVMs. Sometime, a pAVM can be associated with other vascular malformations in the central nervous system. Thus, Wyburn-Masson syndrome, also called Bonnet-Dechaume-Blanc syndrome in the French literature, may affect the eyelid, in association with retinal and cerebral AVMs.^{15,16}

The distinction between pAVMs and orbital AVFs is of tremendous importance. AVFs are direct connections between feeding arteries and draining veins, while pAVMs are arteriovenous shunts associated with a network of dysplastic vessels: the nidus. Palpebral AVFs usually occur in post-traumatic conditions, while pAVMs are congenital and may appear or worsen due to trigger factors (trauma, pregnancy, puberty, and so forth). Clinically, AVFs may exceptionally present as a pulsatile eyelid mass.¹⁷ AVFs are less aggressive than pAVMs; pAVMs are present from birth, may remain quiescent for years, and become active with a high increase of the flow.¹⁸ Treatment is easier for palpebral AVFs because it can be performed by a sole endovascular embolization, while in pAVMs, EVT, most of time, needs to be associated with surgery and often remains partial, focused on the active part of the lesion.¹⁹

The differential diagnosis for pAVM include capillary hemangiomas for neonates and solid tumor or venous varices for adults. Clinically, an orbital varicose vein grows in the Val-salva maneuver, in a prone position, and in crying for babies.²⁰

Usually, Doppler sonography and MR imaging help in the confirmation of the diagnosis.

Angiographic Findings in pAVMs

In our series, 8 of 9 patients had pAVMs fed by ICA branches (palpebral branches from the OA); in 1/9 cases, the pAVM was fed only by branches from ECA; in 6/9 cases, pAVMs were fed by both ICAs and ECAs (Fig 1 and Table 4). The draining vein was, most of the time, the SOV (8/9). More rarely, the facial vein drained the pAVM (4/9). The nidus was small (<3 cm) and had a compact appearance in almost all cases. In our study, neither a nidal nor arterial aneurysm was observed. Nevertheless, an aneurysm located on the arterial feeder has already been described in pAVMs.²¹

EVT

EVT is challenging in these superficial vascular malformations because of the risk of intraorbital hematoma or occlusion of the CRA by uncontrolled embolic agent injection, potentially responsible for monocular blindness. According to most authors^{8,13} and our institutional experience, therapeutic abstention should be proposed for quiescent lesions. Thus, treatment should only be performed for nonquiescent lesions (growing lesions or bleeding pAVMs) or in cases of a lesion responsible for a major deformity.⁸

Embolization cannot, most of time, alone achieve a total cure of the AVM.¹³ Thus, according to our experience, combined treatment associating endovascular embolization and surgical resection should be proposed, with the main intention of curing, as totally as possible, the pAVM.^{9,13,14} For small pAVMs, embolization alone could be performed with satisfying results (2 cases in our series). The best delay to surgical resection is 24–48 hours, when additional surgery is recommended. The choice of the embolic agent for the treatment of the pAVMs depends on the habits of the operator and on the angioarchitecture of the pAVM. For small pAVMs, glue should be used as a first choice. Side effects of some embolic agents should also be known: Absolute alcohol presents the risk of cutaneous necrosis and general complications (dose-related)²²; black skin coloration could appear after Onyx injection in cases of superficial pAVMs.

Comparison of Our Results with Data in the Literature

Palpebral AVMs are very rare. In a review of 627 orbital tumors, Wright¹ found only 3 orbital AVMs. Only single case reports and short series have been previously reported.^{12,23} To our knowledge, fewer than 50 cases have been reported in the literature.^{12,24–33} The largest series published in the English literature included 8 patients.¹² In this study, 7 of the 8 patients had a surgical excision of the AVM. Preoperative embolization was performed in 3 patients: Two had embolization with PVA particles in the arterial feeders and 1 was presurgically treated by platinum coils. Postoperative follow-up (mean delay, 27 months) in this series showed that 6 patients remained symptom-free and 2 required further procedures. In our series, no significant complication occurred during or after the endovascular procedure. All patients had total or quasitotal clinical regression of the mass at long-term follow-up (mean delay, 6.3 years). Disappearance or only a small remnant of the pAVM

was observed at long-term angiographic follow-up in all the cases, when performed (5/5).

Conclusions

In this series, combined endovascular and surgical treatment of pAVMs was safe and effective. All patients had a good clinical outcome at 6 years' mean follow-up. No significant complication was reported.

Acknowledgments

We thank Chrisanthi Basdekidou, MD, for her precious help.

Disclosures: Jacques Moret. Consultant: Boston Scientific, ev3.

References

1. Wright JE. **Orbital vascular anomalies.** *Trans Am Acad Ophthalmol Otolaryngol* 1974;78:OP606–16
2. Kim AW, Kosmorsky GS. **Arteriovenous communication in the orbit.** *J Neuroophthalmol* 2000;20:17–19
3. Kohout MP, Hansen M, Pribaz JJ, et al. **Arteriovenous malformations of the head and neck: natural history and management.** *Plast Reconstr Surg* 1998;102:643–54
4. Riché MC. **Fistules et malformations artérioveineuses.** In: Enjolras O, Riché MC, Mulliken JB, et al, eds. *Atlas des Hémangiomes et Malformations Vasculaires Superficielles*. Paris, France: Medsi/Mc Graw Hill; 1990:93–122
5. Young AE. **Arteriovenous malformations.** In: Mulliken JB, Young AE, eds. *Vascular Birthmarks: Hemangiomas and Malformation*. Philadelphia: WB Saunders; 1988: 228–45
6. Riche MC, Enjolras O, Merland JJ, et al. *Atlas des Angiomes et de Malformations Vasculaires Superficielles*. Paris, France: Medsi/McGraw Hill; 1991
7. Enjolras O, Mulliken JB. **Vascular cutaneous anomalies in children: malformations and hemangiomas.** *Pediatr Surg* 1996;290–95
8. Herbreteau D, Brunereau L, Cottier J, et al. **Hemangiomas and superficial vascular malformations of the head and neck: classification, diagnosis, treatment** [in French]. *J Neuroradiol* 1997;24:274–90
9. Hayes BH, Shore JW, Westfall CT, et al. **Management of orbital and periorbital arteriovenous malformations.** *Ophthalmic Surg* 1995;26:145–52
10. Brouillard P, Vikkula M. **Genetic causes of vascular malformations.** *Hum Mol Genet* 2007;(16 spec no. 2):R140–49
11. Holt JE, Holt GR, Thornton WR. **Traumatic arteriovenous malformation of the eyelid.** *Ophthalmic Surg* 1980;11:771–77
12. Warrier S, Prabhakaran VC, Valenzuela A, et al. **Orbital arteriovenous malformations.** *Arch Ophthalmol* 2008;126:1669–75
13. Enjolras O, Logeart I, Gelbert F, et al. **Arteriovenous malformations: a study of 200 cases** [in French]. *Ann Dermatol Venerol* 2000;127:17–22
14. Schöbinger R. In: *Proceedings of International Society for the Study of Vascular Anomalies Congress*, Rome, Italy. June 23–26, 1996
15. Lester J, Ruano-Calderon LA, Gonzalez-Olhovich I. **Wyburn-Mason syndrome.** *J Neuroimaging* 2005;15:284–85
16. Brodsky MC, Hoyt WF, Higashida RT, et al. **Bonnet-Dechaume-Blanc syndrome with large facial angioma.** *Arch Ophthalmol* 1987;105:854–55
17. Busin M, Graefe C, Koch J. **Arteriovenous fistula presenting as a tumor of the upper eyelid.** *Ophthalmic Surg* 1994;25:471–73
18. Mulliken JB, Zetter BR, Folkman J. **In vitro characteristics of endothelium from hemangiomas and vascular malformations.** *Surgery* 1982;92:348–53
19. Decock C, Stefaan R, Vandenbroecke C, et al. **Diagnosis and treatment of a superficial upper eyelid arteriovenous malformation.** *Orbit* 2008;27:301–03
20. Takechi A, Uozumi T, Kiya K, et al. **Embolisation of orbital varix.** *Neuroradiology* 1994;36:487–89
21. Kleinschmidt A, Sullivan TJ, Mitchell K. **Intraorbital ophthalmic artery aneurysms.** *Clin Experiment Ophthalmol* 2004;32:112–14
22. Chapot R, Laurent A, Enjolras O, et al. **Fatal cardiovascular collapse during ethanol sclerotherapy of a venous malformation.** *Interv Neuroradiol* 2002;8:321–24
23. Trombly R, Sandberg DI, Wolfe SA, et al. **High-flow orbital arteriovenous malformation in a child: current management and options.** *J Craniofac Surg* 2006;17:779–82
24. Murali R, Berenstein A, Hirschfeld A. **Intraorbital arteriovenous malformation with spontaneous thrombosis.** *Ann Ophthalmol* 1981;13:457–59
25. Howard GM, Jakobiec FA, Michelsen WJ. **Orbital arteriovenous malformation with secondary capillary angiomas treated by embolization with silastic liquid.** *Ophthalmology* 1983;90:1136–39
26. Gross ND, Hornblass A. **Ligation of an arteriovenous malformation with the Heifetz clamp: case report.** *Arch Ophthalmol* 1989;107:171
27. Tsai FY, Wadley D, Angle JF, et al. **Superselective ophthalmic angiography for diagnostic and therapeutic use.** *AJNR Am J Neuroradiol* 1990;11:1203–04
28. Rootman J, Kao SC, Graeb DA. **Multidisciplinary approaches to complicated vascular lesions of the orbit.** *Ophthalmology* 1992;99:1440–46
29. Chakraborty S, Nagashima T, Izawa I, et al. **Intraorbital arteriovenous malformation: case report.** *Surg Neurol* 1993;40:320–25
30. Hieu PD, Besson G, Roncin S, et al. **Successful surgical treatment of intraorbital arteriovenous malformations: case report.** *Neurosurgery* 1997;40:626–31
31. Yasuhara T, Ikeda T, Koizumi K, et al. **Multiple cranial arteriovenous malformations in a child with eventual blindness in the affected eye.** *Am J Ophthalmol* 1999;127:99–101
32. Pathak-Ray V, Lawson J, Harris M. **Retinal and orbital arteriovenous malformations.** *Eye* 2001;15:357–58
33. Moin M, Kersten RC, Bernardini F, et al. **Spontaneous hemorrhage in an intraorbital arteriovenous malformation.** *Ophthalmology* 2000;107:2215–19