



Discover Generics

Cost-Effective CT & MRI Contrast Agents



WATCH VIDEO

AJNR

Angioplasty and Stenting of Atherosclerotic Middle Cerebral Arteries with Wingspan: Evaluation of Clinical Outcome, Restenosis, and Procedure Outcome

S.C.H. Yu, T.W.H. Leung, K.T. Lee, J.W.Y. Hui and L.K.S. Wong

This information is current as of June 23, 2025.

AJNR Am J Neuroradiol 2011, 32 (4) 753-758

doi: <https://doi.org/10.3174/ajnr.A2363>

<http://www.ajnr.org/content/32/4/753>

ORIGINAL RESEARCH

S.C.H. Yu
T.W.H. Leung
K.T. Lee
J.W.Y. Hui
L.K.S. Wong

Angioplasty and Stenting of Atherosclerotic Middle Cerebral Arteries with Wingspan: Evaluation of Clinical Outcome, Restenosis, and Procedure Outcome

BACKGROUND AND PURPOSE: MCA is a common location of intracranial stenosis. It is relatively more peripherally located and of a smaller caliber, and could therefore be a site technically more challenging and risky for angioplasty and stenting. The study aimed to evaluate the clinical outcome, restenosis rate, and procedural safety of Wingspan stent placement for atherosclerosis in the MCA compared with stenosis in other arteries.

MATERIALS AND METHODS: Patients who underwent Wingspan stent placement for symptomatic intracranial stenosis of $\geq 70\%$ (or stenosis of $\geq 50\%$ for recurrent ischemia despite medical therapy) were recruited prospectively and allocated into a study group (MCA stenosis, $n = 35$) and a control group (other stenosis, $n = 25$). Primary end points were the following: 1) all stroke or death rate at 1 year, and 2) significant in-stent restenosis rate at 1 year. Secondary end points were the following: 1) periprocedural complications within 24 hours, rate of TIA during the procedure, all stroke or death rate within 30 days; and 2) the inability to complete the procedure due to technical problems.

RESULTS: Results of study group versus the control group were the following: degree of stenosis, $78.4 \pm 10.9\%$ versus $72.5 \pm 11.2\%$ (P value = .0456); diameter of stenosis, 0.6 ± 0.3 versus 1.0 ± 0.5 mm ($P = .0017$); all stroke or death rate at 1 year, 14.3% versus 12% (OR = 1.22); in-stent restenosis rate at 1 year, 10% versus 10.5% (OR = 1.05); periprocedural complication rate at 24 hours, 2.9% versus 4% (OR = 0.70); TIA rate during the procedure, 8.6% versus 4% (OR = 2.25); all stroke or death rate at 30 days, 5.7% versus 12% (OR = 0.44); and technical failure rate, 2.9% versus 0%.

CONCLUSIONS: In this study, there were no significant differences in procedural safety, patient outcome, and restenosis rates of stent placement between the group with MCA stenosis and the group with stenoses located at other sites.

ABBREVIATIONS: CI = confidence interval; 3DRA = 3D rotational angiography; DSA = digital-subtraction angiography; MCA = middle cerebral artery; *nFU* = number of patients with follow-up DSA performed; OR = odds ratio; TIA = transient ischemic attack; WASID = Warfarin Aspirin Symptomatic Intracranial Disease

The annual stroke risk from all causes in patients with intracranial atherosclerosis is estimated to be from at least 3.6% to $>13\%$ annually.¹⁻⁸ The WASID Trial Investigators demonstrated a first-year ischemic stroke rate of at least 11% in patients with intracranial atherosclerosis in a pertinent vascular territory.⁴ Patients with a history of TIA or stroke in the territory of a 70%–99% stenosis were found to have a stroke rate of 18% at 1 year while on antithrombotic therapy.⁹ A matched comparison between medically treated patients in the WASID trial² and stent-treated patients in the National Institutes of Health Intracranial Stent Registry concluded that stent placement might offer benefit in patients with 70%–99% stenosis.¹⁰ The use of conservative angioplasty and the Wingspan stent (Boston Scientific, Natick, Massachusetts) as a self-expanding nitinol stent specifically developed for intracranial atherosclerotic stenosis has brought down the periprocedural stroke or

death rate from 9.5% (95% CI, 7.0%–12.0%) in a meta-analysis to 4.5%.^{11,12} The MCA is a common location of stenosis in the anterior circulation; it is more peripherally located and of a relatively smaller caliber compared with the other common locations of intracranial stenosis. It is hypothesized that intracranial atherosclerosis located at the MCA is technically more challenging for angioplasty and stent placement and is associated with a suboptimal treatment outcome. The current study aimed to evaluate the procedural safety, clinical outcome, and restenosis rate of angioplasty and stent placement in atherosclerotic MCA by using a self-expanding nitinol stent, the Wingspan stent system.

Materials and Methods

Study Design

This was a prospective single-center study approved by the institutional review board. An informed consent was signed by either the patient or a close relative. All patients who underwent angioplasty and stent placement by using the Wingspan system from February 2006 to November 2008 were recruited into the study. The inclusion criteria for angioplasty and stent placement using the Wingspan system were the following: 1) The patient presented with symptomatic ischemic stroke or TIA, 2) intracranial stenosis was confirmed on DSA, 3) the

Received June 23, 2010; accepted after revision August 31.

From the Departments of Imaging and Interventional Radiology (S.C.H.Y., K.T.L., J.W.Y.H.) and Medicine and Therapeutics (T.W.H.L., L.K.S.W.), Prince of Wales Hospital, The Chinese University of Hong Kong, Hong Kong, China.

Please address correspondence to Simon Chun Ho Yu, MD, Department of Diagnostic Radiology and Organ Imaging, Prince of Wales Hospital, The Chinese University of Hong Kong, 30–32 Ngan Shing St, Shatin, Hong Kong, China; e-mail: simonyu@cuhk.edu.hk

DOI 10.3174/ajnr.A2363

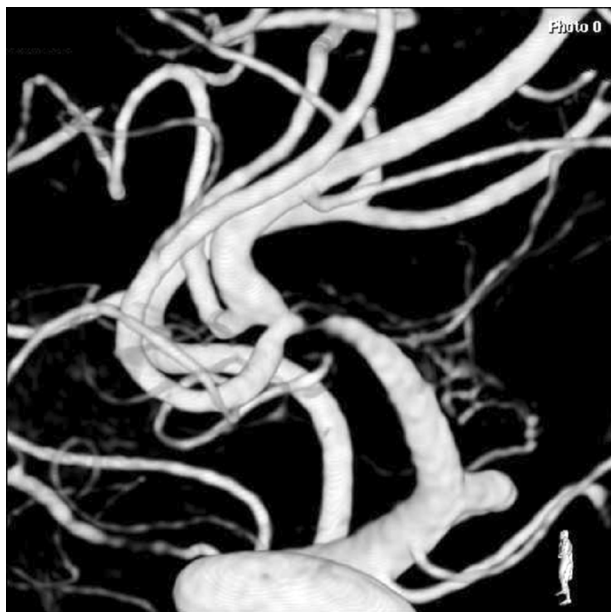

Fig 1. Pretreatment 3DRA image of 96% stenosis at the distal M1 segment of the MCA (2.5-mm diameter).

location of the intracranial stenosis corresponded to the vascular territory of the ischemic event, 4) the degree of intracranial stenosis was $\geq 70\%$ for patients presenting with a first episode of cerebral ischemia (Fig 1), 5) the degree of intracranial stenosis was $\geq 50\%$ for patients with recurrent cerebral ischemia despite medical therapy, and 6) the diameter of the vessel immediately adjacent to the stenosis was ≥ 2 mm. Patients were divided into 2 groups for comparison: Those with MCA stenosis were allocated into the study group, and the remainder into the control group.

The primary end points were the following: 1) clinical outcome in terms of ipsilateral stroke, all stroke, or death at 1 year, and 2) significant in-stent restenosis rate at 1 year. Significant in-stent restenosis was defined as $\geq 50\%$ increase in stenosis compared with the baseline occurring within or immediately adjacent (within 5 mm) to the implanted stent. The secondary end points were the following: 1) procedural safety in terms of periprocedural complications within 24 hours; rate of TIA during the procedure; and ipsilateral stroke, all stroke, or death within 30 days; and 2) technical failure, defined as the inability to complete the angioplasty procedure and stent placement at the site of stenosis due to technical problems.

Methodology of 3DRA

The lesions of intracranial stenosis were studied with 3DRA before the treatment procedure, immediately after treatment, and at 1-year follow-up (V5000; Philips Healthcare, Best, the Netherlands). Contrast media (iopamidol, Iopamiral 300 mg/mL; Bracco, Milan, Italy) was injected at a rate of 2.1 to 2.4 mL per second and a pressure of 400 psi, enough to sharply outline the arterial wall and eliminate flow artifacts, starting 1 second before the onset of radiography and continuing until radiography was completed. The quality of contrast injection was checked with digitally subtracted rotational angiography to ensure that there was no movement of the object during 3DRA and that there were no flow artifacts caused by an insufficient contrast injection rate. The rate and pressure of contrast injection, the level of voltage and current for radiation exposure, and the settings of contrast window and level of the 3DRA workstation for visualizing the 3D recon-

structed images were all maintained constant for the 3DRA studies of the same patient at the 3 different time points. The settings of contrast window and level were at a point where the petrous temporal bone tissue just started to show up, as a standard for all 3DRA images to avoid undermeasurement of vessel size and overmeasurement of vascular stenosis.

Methodology of Stenosis Assessment

The characteristics of stenosis were categorized according to the classification of intracranial stenosis of Mori et al,¹³ in which type A was defined as short (≤ 5 mm in length), concentric, or moderately eccentric lesions less than totally occlusive. Type B was tubular (5–10 mm in length), extremely eccentric, or totally occluded lesions, < 3 months old; and type C was diffuse (> 10 mm in length) extremely angulated ($> 90^\circ$) lesions with excessive tortuosity of the proximal segment or totally occluded lesions and ≥ 3 months old.

The method used for determining percentage of stenosis of an intracranial artery was the same as that used in the WASID trial: percentage of stenosis = $(1 - [D_{\text{stenosis}} / D_{\text{normal}}]) \times 100$, where D_{stenosis} is the diameter of the artery at the site of the most severe degree of stenosis and D_{normal} is the diameter of the proximal normal artery. D_{normal} was determined by the following criteria: For the middle cerebral, intracranial vertebral, and basilar arteries, the diameter of the proximal part of the artery at its widest nontortuous normal segment was chosen (first choice). If the proximal artery was diseased (eg, MCA-origin stenosis), the diameter of the distal portion of the artery at its widest parallel nontortuous normal segment was substituted (second choice). If the entire intracranial artery was diseased, the most distal parallel nontortuous normal segment of the feeding artery was measured (third choice).^{4,14} “In-stent restenosis” was defined as a lesion demonstrating stenosis of $> 50\%$ adjacent to the stent (ie, within or immediately adjacent [5 mm]) and absolute luminal loss $> 20\%$ on follow-up imaging. This second criterion was added because some lesions were left with residual stenoses measuring between 30% and 50% after the initial treatment. In these cases, a relatively small degree of luminal loss (ie, $< 20\%$) could result in in-stent restenosis if a binary criterion of $> 50\%$ stenosis at the time of follow-up was used.^{15–17}

The Procedure and Instruments

The procedures were performed by a team comprising an interventional neuroradiologist with 8 years of experience in neurovascular intervention (S.C.H.Y.) and an interventional neurologist with 1 year of experience in neurovascular intervention (T.W.H.L.). All patients were treated with aspirin, 100 mg, and clopidogrel, 75 mg, orally, daily for at least 3 days before the procedure. During the procedure, unfractionated heparin was administered intravenously as a 2000-U bolus and at an hourly dose of 500 U thereafter. After the procedure, aspirin, 100 mg, and clopidogrel, 75 mg, orally, daily were prescribed for 3 months; and oral aspirin, 100 mg daily, was continued life-long. Instruments included a 6F guiding catheter (Guider Softip; Boston Scientific), microguidewires of 160 and 300 cm long (Transend Floppy, 160 cm and 300 cm; Boston Scientific), a microcatheter (Excel 14, Target Therapeutics/Boston Scientific, Fremont, California), and an angioplasty balloon catheter (Gateway PTA balloon catheter; Boston Scientific). Not different from the standard procedure described in the literature, predilation of the stenotic lesion was performed with an undersized angioplasty balloon at 80% of the native vessel diameter to restrict the barotrauma to the plaque while minimizing intimal damage to the native parent vessel.^{12,18,19} Selection of stent size was

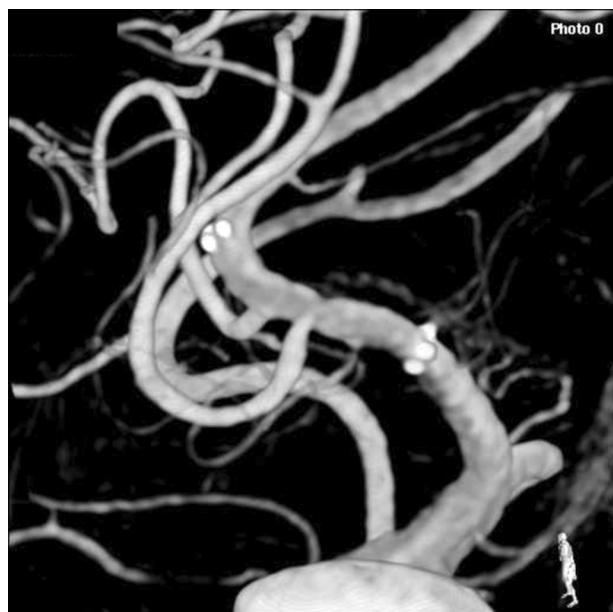

Fig 2. Image of the same lesion immediately after angioplasty with a 2-mm balloon and placement of a 3 × 15 mm Wingspan stent.

based on an oversize of the native diameter of the target vessel by 0.5–1.0 mm and an extended stent length by 3 mm on either side of the lesion (Fig 2).^{12,20}

In the literature, the stenosis was usually crossed with a short microguidewire and a microcatheter (Transend Floppy, 160 cm, and Excel 14) first before the placement of a long microguidewire and subsequently the angioplasty catheter.^{18,19} For the first 45 patients of the current study, the angioplasty balloon catheter was introduced across the stenosis directly by using a long microguidewire (Transend Floppy, 300 cm) without the use of a short microguidewire and a microcatheter. The reason for adopting such a technique was to save the cost and the procedure of using the additional short microguidewire and microcatheter. After a major complication of arterial dissection occurred as a result of such a technique, the remainder of the procedures were performed in the fashion described in the literature.^{18,19} Instead of a prolonged balloon inflation time of at least 120 seconds as described in the literature,^{16,17} the balloon inflation in the current study was not >10 seconds each time to reduce the duration of brain ischemia. The balloon was inflated only once if it was placed at an optimal position during inflation. All procedures were performed with the patient under local anesthesia.

Intraprocedural Observation

Technical problems, patient morbidity, and procedure-related complications were observed prospectively. For patient morbidity, signs of cerebral ischemia or focal neurologic deficits were monitored. For complications, guidewire perforation, vascular dissection, and intracranial hemorrhage were monitored.

Follow-Up Studies

The patients were assessed clinically at follow-up regularly at monthly or bimonthly intervals for up to 1 year. Follow-up DSA and 3DRA were performed at 1 year (Fig 3).

Statistical Analysis

For each study outcome, results were expressed as incidents and percentages of patients for nominal outcomes or as means and SDs for

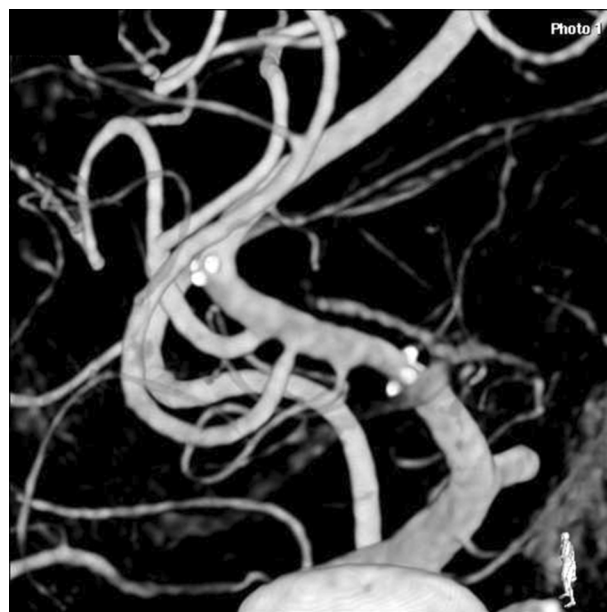


Fig 3. Image of the same lesion at 12 months after angioplasty and stent placement, showing no evidence of in-stent restenosis.

continuous outcomes. The effect size was expressed as OR for binary outcomes and as difference in means for continuous outcomes. A 95% CI was provided to indicate the uncertainty. Comparison of outcomes between the 2 groups was made with the use of the Fisher exact test for binary outcomes and the Student *t* test for continuous outcomes.

Results

Patient Demographics and Lesion Characteristics

All patients who fulfilled the inclusion criteria for angioplasty and stent placement from February 2006 to November 2008 underwent the stent-placement procedure. All patients who underwent stent-placement treatment were recruited into the study without exclusion. There were 47 men and 13 women. Average patient age was 64.27 ± 10.71 years; median, 65 years; range, 34–84 years. Forty-four patients presented with stroke, and 16 presented with TIA. The median score of National Institutes of Health Stroke Scale was 3, the mode was 2, and the range was 0–9. There were 35 patients in the study group and 25 patients in the control group. Patient demographics and lesion characteristics of the 2 groups are shown in Table 1. Overall there were 6 Mori type A lesions, 45 Mori type B lesions, and 9 Mori type C lesions. In the study group, there were 3 Mori type A lesions, 27 Mori type B lesions, and 6 Mori type C lesions. Thirty-two lesions involved only the M1 segment of the MCA; 3 lesions involved both the M1 and M2 segments. In the control group, there were 3 Mori type A lesions, 18 Mori type B lesions, and 4 Mori type C lesions. Seventeen lesions were located at the internal carotid artery; 4 lesions, at the vertebral artery; and 4 lesions, at the basilar artery.

Overall the average degree of stenosis was $76.0 \pm 11.4\%$, the median was 75%, and the range was 52.3%–95.7%. The degree of stenosis was significantly higher in the study group; the average degrees of stenosis in the study and control groups were $78.4 \pm 10.9\%$ and $72.5 \pm 11.2\%$, respectively (difference, 5.9%; 95% CI, 0.12%–11.72%; *P* value = .0456). The diameter

Table 1: Patient demographics and lesion characteristics				
	MCA Stenosis (n = 35)	Other Stenosis (n = 25)	Effect Size (95% CI)	2-Tailed P Value
Age (yr)	64.2 ± 10.9	64.7 ± 10.6	−0.49 (−6.14–5.16)	.8625
Sex ratio (F/M)	9:26	4:21	1.82 (0.49–6.74)	.5275
Presentation (stroke/TIA)	25:10	20:5	0.62 (0.18–2.12)	.5522
Degree of stenosis (%)	78.4 ± 10.9	72.5 ± 11.2	5.9 (0.12–11.72)	.0456
Diameter of stenosis (mm)	0.6 ± 0.3	0.9 ± 0.5	−0.37 (−0.59–0.14)	.0017

Table 2: Primary end points				
	MCA Stenosis (n = 35)	Other Stenosis (n = 25)	OR (95% CI)	2-Tailed P Value
Ipsilateral stroke at 1 year	4 (11.4%)	2 (8%)	1.48 (0.25–8.81)	1
All stroke at 1 year	4 (11.4%)	2 (8%)	1.48 (0.25–8.81)	1
All stroke or death at 1 year	5 (14.3%)	3 (12%)	1.22 (0.26–5.66)	1
In-stent restenosis at 1 year	3 (10%) (nFU = 30)	2 (10.5%) (nFU = 19)	1.05 (0.16–6.94)	1
Symptomatic in-stent restenosis at 1 year	1 (3.3%) (nFU = 30)	0 (nFU = 19)	infinity (0-infinity)	1

Table 3: Secondary end points				
	MCA Stenosis (n = 35)	Other Stenosis (n = 25)	OR (95% CI)	2-Tailed P Value
Periprocedural complication	1 (2.9%)	1 (4%)	0.70 (0.04–11.85)	1
Transient ischemia during procedure	3 (8.6%)	1 (4%)	2.25 (0.22–22.99)	.6339
Ipsilateral stroke at 30 days	1 (2.9%)	2 (8%)	0.34 (0.03–95)	.5653
All strokes at 30 days	1 (2.8%)	2 (8%)	0.34 (0.03–3.95)	.5653
All strokes or death at 30 days	2 (5.7%)	3 (12%)	0.44 (0.07–2.88)	.6405
Technical failure	1 (2.9%)	0	Infinity (0 to infinity)	1

of the stenosis was significantly smaller in the study group; the mean diameters of stenosis were 0.6 ± 0.3 and 1.0 ± 0.5 mm in the study and control groups, respectively (difference, 0.4 mm; 95% CI, 0.14–0.59 mm, P value = .0017). In the study group, the procedure was performed within 30 days in 21 patients (average, 10.0 ± 6.3 days) and beyond 30 days in 14 patients (average, 77.5 ± 44.0 days). In the control group, the procedure was performed within 30 days in 12 patients (average, 14.7 ± 7.7 days) and beyond 30 days in 13 patients (average, 297.62 ± 494.09 days).

Primary End Points

As shown in Table 2, there was no statistically significant difference in patient outcomes at 1 year in terms of ipsilateral stroke rate, all stroke rate, or all stroke or death rate between the 2 groups; the ORs (95% CI, P value) between the 2 groups for the 3 outcome parameters were 1.48 (95% CI, 0.25–8.81; P value = 1), 1.48 (95% CI, 0.25–8.81; P value = 1), and 1.22 (95% CI, 0.26–5.66; P value = 1), respectively. In the study group, ipsilateral stroke occurred in 1 patient within 30 days, in 1 patient within 6 months, and in 2 patients within 12 months. The treatment procedures were apparently uneventful in all of these patients. One patient died within 30 days following a procedural complication of vascular dissection and perforation. In the control group, ipsilateral stroke occurred in 2 patients following apparently uneventful procedures. One patient died of pneumonia within 30 days following an uneventful procedure. There was no difference in in-stent restenosis rates between the 2 groups. The restenosis rates at 1 year were 10% and 10.5% for the study and control groups, respectively (OR, 1.05; 95% CI, 0.16–6.94; P value = 1). The rates of symptomatic in-stent restenosis in the study

and the control groups were 3.3% and 0% respectively (OR equals infinity; 95% CI equals 0 to infinity; P value = 1).

Secondary End Points

As shown in Table 3, the periprocedural complication rate within 24 hours was not significantly different between the 2 groups (2.9% versus 4%; OR, 0.70; 95% CI, 0.04–11.85; P value = 1). Complications were due to vascular dissection and perforation of the MCA in 1 patient in the study group and rupture of the basilar artery during angioplasty in 1 patient in the control group. Both patients died within 2 days following onset of complications. Intraprocedural TIA occurred in 3 patients in the study group (8.6%); all 3 patients had a high-grade stenosis of $>85\%$. Two presented with acute confusion and convulsion when the balloon catheter was placed across the stenosis. In the other patient, repeat transient blindness and severe headache occurred whenever the stent system was manipulated close to the stenosis. The procedure was suspended in these 3 patients when the ischemic event occurred; the procedures were subsequently abandoned to avoid development of stroke. The patients subsequently recovered from the TIA without adverse sequelae. TIA occurred in 1 patient in the control group during advancement of stent system (4%). The procedure was finally completed, and the patient recovered without adverse sequelae.

There was no statistically significant difference between the 2 groups in the rate of TIA during the procedure (OR, 2.25; 95% CI, 0.22–22.99; P value = .6339). All stroke or death rates at 30 days were not significantly different between the study and the control groups (5.7% versus 12%; OR, 0.44; 95% CI, 0.07–2.88; P value = .6405). The technical failure rate was not significantly different between 2 groups (2.9% versus 0%; 95%

CI, 0 to infinity; P value = 1). In the only case of technical failure due to a technical problem in the study group, we were unable to advance the angioplasty balloon through a high-grade stenosis at the M1 bifurcation. The 3 cases of procedural termination due to intraprocedural TIA were not counted as technical failures by definition because the procedural termination was due to patient's condition and not a technical problem.

Overall Results

When the 60 patients were evaluated as a whole group, the periprocedural complication rate at 24 hours was 3.3% (2/60), the technical failure rate was 1.7% (1/60), the all stroke rate at 30 days was 5% (3/60), the all stroke or death rate at 30 days was 8.3% (5/60), the all stroke rate at 1 year was 10% (6/60), the all stroke or death rate at 1 year was 13.3% (8/60), and the in-stent restenosis rate at 1 year was 10.2% (5/49).

Discussion

In the several published studies on the use of the Wingspan stent for intracranial atherosclerosis,¹⁵⁻¹⁹ the technical success rate was high, between 96.7% and 98.8%,^{18,19} which was comparable with that of the current study (98.3%). These published studies shared a common feature of having a relatively short mean angiographic follow-up that ranged from 4.8 to 8.5 months.¹⁵⁻¹⁹ The rate of in-stent restenosis among these studies had been relatively high within a short duration, notably 25% at a mean follow-up of 4.8 months,¹⁹ 29.7% in 5.9 months,¹⁵ 31.2% in 7.3 months,¹⁷ and 32.3% in 8.5 months.¹⁶ In-stent restenosis rates in these studies were higher than those in the current study (10.2%).

The MCA was a common site of atherosclerotic stenosis in the previous studies, constituting 28%–33% of the cases.^{18,19} In 2 studies, lesions at MCAs were associated with a higher rate of in-stent restenosis compared with the overall restenosis rate for all sites, namely 38.7% versus 29.7% at a mean follow-up of 5.9 months¹⁶ and 69.2% versus 32.2% at a mean follow-up of 8.5 months. These findings suggest that atherosclerotic stenosis of the MCAs was more prone to in-stent restenosis than stenoses at other locations. Other evidence that suggested that the location of the lesion was a factor affecting treatment outcome included the finding of a higher restenosis rate of lesions at the supraclinoid internal carotid artery compared with that for all lesions, namely 66.6% versus 31.2% at a mean follow-up of 7.3 months¹⁷ and 90% versus 32.3% at a mean follow-up of 8.5 months.¹⁶ On the basis of these previous findings and the fact that the MCA is more peripherally located and of a relatively smaller caliber compared with the other common locations of intracranial stenosis, we hypothesized that intracranial atherosclerosis located at the MCA is technically more challenging for angioplasty and stent placement than lesions at other locations and is associated with a relatively less favorable treatment outcome.

The definition of in-stent restenosis in the current study was adopted from previous studies on the same topic to facilitate the cross-reference of results of the current study with those of previous studies.¹⁵⁻¹⁷ Findings of the current study showed that there was probably no statistically significant difference between lesions in the MCA and lesions in other locations in procedural safety, clinical outcome, and restenosis

rates of angioplasty and stent placement by using the Wingspan stent. Although there was, apparently, a great discrepancy between the reported studies and the current study for the in-stent restenosis rates of lesions in the MCA, there was no intention to compare the in-stent restenosis rates between different studies because there were variable factors among different studies. For example, the clinical history and timing of the stent-placement procedure in relation to the onset of ischemic events were lacking in the previous studies. However, there was definitely a discrepancy in the findings of the current study and those of the previous studies concerning the effect of lesion location on restenosis rates. A major difference in the technique of angioplasty between the previous studies and the current study was the length of inflation time, but it would be out of the scope of the current discussion to comment on the relation between inflation time and restenosis rate.

Another difference between the previous studies and the current study was the use of 3DRA for assessment of arterial stenosis before and after treatment in the current study. The use of DSA for measurement of the diameters of parent vessels and stenotic segments is limited in that the x-ray projection angle may not be optimal for identification of the site of the greatest degree of stenosis and the proximal part of the artery at its widest nontortuous normal segment. Projection of these arterial segments at an optimal angle was mandatory for accurate assessment of the degree of stenosis according to the methodology of the WASID trial.² Overlapping of arterial branches in DSA may also obscure the region of interest. Moreover, when a structure is well-visualized with an optimal projection, it may not always be feasible to calibrate the measurements of the structure without magnification error. The authors believe it is advantageous to use 3DRA instead of DSA for assessment of arterial stenosis because 3DRA facilitates the identification of the site of the greatest degree of stenosis and the proximal part of the artery at its widest normal segment without superimposition. A standardized method of 3DRA was used in the current study to minimize error. The accuracy in measurement of the diameters of arterial segments and stenoses would affect the accuracy of the selection of the size of angioplasty balloons and the size of stents. It is suspected that the use of inappropriately sized angioplasty balloons and stents could be possible factors affecting the rate of in-stent restenosis; however, further studies are required to confirm this point.

A limitation of the current study was that the number of patients involved was relatively small. Another limitation was that a randomized comparative study could not be performed in the normal clinical setting in which the location of the atherosclerotic lesion was not allocated, despite the fact that the aim of study was to compare 2 groups. A further limitation was that the current study was a single-center study; therefore, the results might be biased, though a control group of comparable size was available for comparison. The discrepancy in findings between the current study and the previous ones should prompt further studies on a larger scale.

Conclusions

There were no significant differences in procedural safety, patient outcome, and restenosis rates of stent placement between

the group with MCA stenosis and the group with stenosis located at other sites.

References

1. Bogousslavsky J, Barnett HJ, Fox AJ, et al. Atherosclerotic disease of the middle cerebral artery. *Stroke* 1986;17:1112–20
2. Chimowitz MI, Kokkinos J, Strong J, et al. The Warfarin–Aspirin Symptomatic Intracranial Disease Study. *Neurology* 1995;45:1488–93
3. Thijs VN, Albers GW. Symptomatic intracranial atherosclerosis: outcome of patients who fail antithrombotic therapy. *Neurology* 2000;55:490–97
4. Chimowitz MI, Lynn MJ, Howlett-Smith H, et al. Comparison of warfarin and aspirin for symptomatic intracranial arterial stenosis. *N Engl J Med* 2005;352:1305–16
5. Failure of extracranial-intracranial arterial bypass to reduce the risk of ischemic stroke: results of an international randomized trial—The EC/IC Bypass Study Group. *N Engl J Med* 1985;313:1191–200
6. Rundek T, Elkind MS, Chen X. Increased early stroke recurrence among patients with extracranial and intracranial atherosclerosis: Northern Manhattan Stroke Study. *Neurology* 1998;50(suppl 4):A75
7. Prognosis of patients with symptomatic vertebral or basilar artery stenosis. The Warfarin–Aspirin Symptomatic Intracranial Disease (WASID) Study Group. *Stroke* 1998;29:1389–92
8. Caplan LR. Advances in stroke research: basic science, treatment, and clinical trial outcomes. *Rev Neurol Dis* 2004;2:91–94
9. Kasner SE, Chimowitz MI, Lynn MJ, et al. Predictors of ischemic stroke in the territory of a symptomatic intracranial arterial stenosis. *Circulation* 2006;113:555–63
10. Qureshi AI, Feldmann E, Gomez CR, et al. Consensus conference on intracranial atherosclerotic disease: rationale, methodology, and results. *J Neuroimaging* 2009;19(suppl 1):1S–10S
11. Marks MP, Wojak JC, Al-Ali F, et al. Angioplasty for symptomatic intracranial stenosis: clinical outcome. *Stroke* 2006;37:1016–20
12. Bose A, Hartmann M, Henkes H, et al. A novel, self-expanding, nitinol stent in medically refractory intracranial atherosclerotic stenoses: the Wingspan study. *Stroke* 2007;38:1531–37
13. Mori T, Fukuoka M, Kazita K, et al. Follow-up study after intracranial percutaneous transluminal cerebral balloon angioplasty. *AJNR Am J Neuroradiol* 1998;19:1525–33
14. Samuels OB, Joseph GJ, Lynn MJ, et al. A standardized method for measuring intracranial arterial stenosis. *AJNR Am J Neuroradiol* 2000;21:643–46
15. Levy EI, Turk AS, Albuquerque FC, et al. Wingspan in-stent restenosis and thrombosis: incidence, clinical presentation, and management. *Neurosurgery* 2007;61:644–51
16. Albuquerque FC, Levy EI, Turk AS, et al. Angiographic patterns of Wingspan in-stent restenosis. *Neurosurgery* 2008;63:23–27
17. Turk AS, Levy EI, Albuquerque FC, et al. Influence of patient age and stenosis location on Wingspan in-stent restenosis. *AJNR Am J Neuroradiol* 2008;29:23–27
18. Fiorella D, Levy EI, Turk AS, et al. US multicenter experience with the Wingspan stent system for the treatment of intracranial atheromatous disease: periprocedural results. *Stroke* 2007;38:881–87
19. Zaidat OO, Klucznik R, Alexander MJ, et al, for the NIH Multi-Center Wingspan Intracranial Stent Registry Study Group. The NIH registry on use of the Wingspan stent for symptomatic 70–99% intracranial arterial stenosis. *Neurology* 2008;70:1518–24
20. Nahab F, Lynn MJ, Kasner SE, et al. Risk factors associated with major cerebrovascular complications after intracranial stenting. *Neurology* 2009;72:2014–19