



Discover Generics

Cost-Effective CT & MRI Contrast Agents



FRESENIUS
KABI

WATCH VIDEO

AJNR

Reply:

W.J. van Rooij and M. Sluzewski

AJNR Am J Neuroradiol 2009, 30 (1) e9-e10

doi: <https://doi.org/10.3174/ajnr.A1372>

<http://www.ajnr.org/content/30/1/e9>

This information is current as
of June 18, 2025.

Reply:

We thank Dr Alvarez for the interest in our review article about the endovascular treatment of very large and giant aneurysms¹ and for the additional thoughts on the mechanisms of growth of partially thrombosed large aneurysms. Dr Alvarez points out that knowledge and understanding of growth mechanism are essential to select the proper treatment. As we well understand, Dr Alvarez presumes that partially thrombosed large aneurysms form a specific entity and can be considered “extraluminal disorders,” for which intraluminal treatment might not be appropriate. This hypothesis is based on imaging observations in small case series and biochemical processes in atherosclerotic mice and is subsequently matured by a basically random selection of associations, thoughts, and figments of the imagination.

Of course we agree with Dr Alvarez that pathogenesis and growth of intracranial aneurysms are complex and largely unknown. Probably, aneurysm growth is related to many factors such as genetic predisposition, biochemical environment (including alcohol and nicotine), vessel wall composition, hemodynamic stresses, and many more factors not yet known. We presume that Dr Alvarez’s concept might be at best part of this complex truth.

Whether partially thrombosed aneurysms form a specific entity is not known. Most of us will be familiar with patients presenting with acute symptoms of mass effect caused by sudden growth of an aneurysm. This sudden growth is caused by intramural hemorrhage as a result of mural dissection or rupture of the vas vasorum, and this intramural hemorrhage can be nicely demonstrated with MR imaging. When this process repeatedly occurs, the typical onion skin appearance will develop. However, in some patients, this intramural thrombus resolves quickly (Fig 1). In these patients, the aneurysm is partially thrombosed for a limited period of time only until the thrombus is resolved. Therefore, the partially thrombosed status of an aneurysm might be a dynamic and temporary phenomenon. Why, in some aneurysms, the mural thrombus resolves quickly and the partially thrombosed aneurysm is transformed into a “normal” aneurysm again is unknown. This is just 1 sample argument about why partially thrombosed aneurysms might not form a specific entity but are different expressions of the same basic but complex pathology. When such an observation is used as the starting point for random thumb sucking, this may result in a completely different concept with equal lack of solid evidence as in the concept of the Bicêtre School.

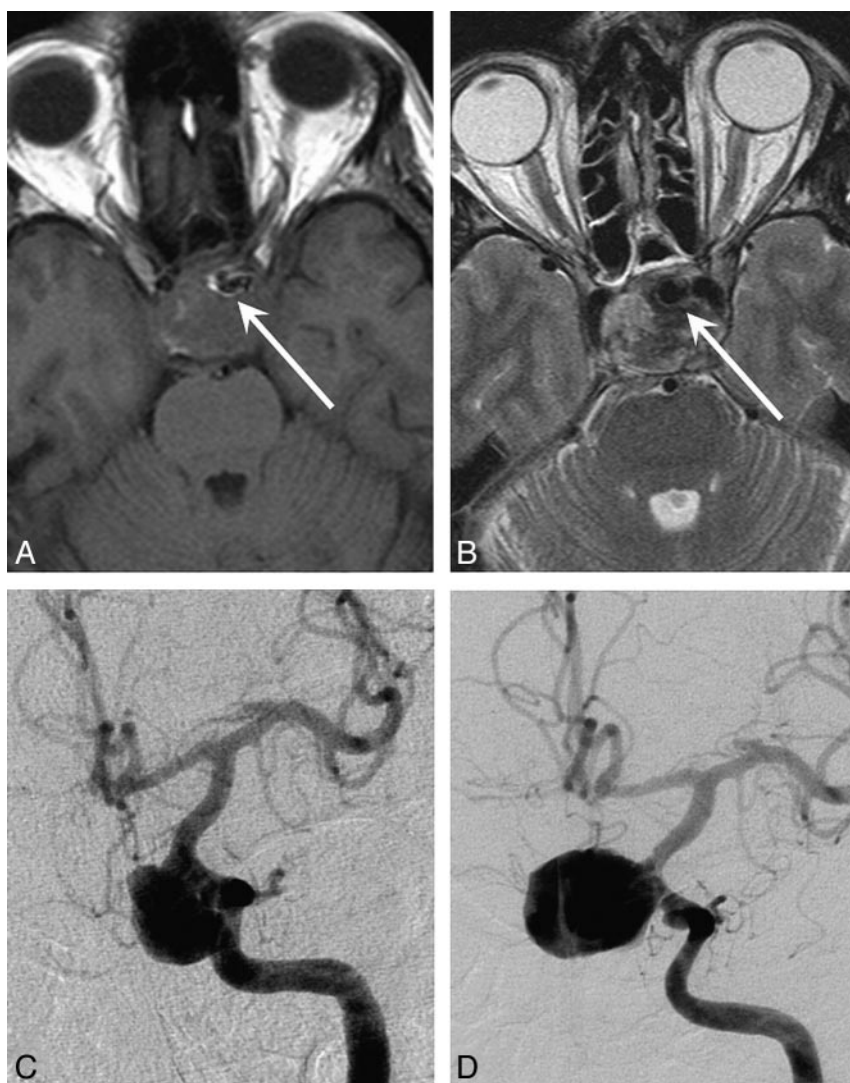


Fig 1. A 43-year-old man with acute left ophthalmoplegia. *A* and *B*, T1- and T2-weighted MR images demonstrate a largely thrombosed carotid hypophyseal aneurysm with a small lumen (arrows). *C*, Angiogram 2 days after MR imaging shows the aneurysmal lumen that appears larger by resolution of thrombus. *D*, Angiogram 16 days after MR imaging demonstrates complete resolution of intraluminal thrombus.

For clinical practice, exact knowledge of the mechanism of growth is not very relevant because our endovascular treatment options are no more than plumbing tools. For every patient with a very large or giant aneurysm, we try to find the momentarily available endovascular or surgical therapy with the lowest risk and the highest chance of short-term success. As we pointed out, short- and midterm clinical results of endovascular treatment of giant aneurysms regarding preventing hemorrhage and improving or curing symptoms of mass effect are fairly good. Observational clinical studies may identify subgroups of patients with large aneurysms with aggravation of symptoms on long-term follow-up. For these subgroups, the method of treatment must be reconsidered.

As for now, we stick to our treatment strategy, which is based on

simple plumbing, common sense, and experience. Theories such as the one from Bicêtre are extremely thin and should not be used to influence clinical decision making.

W.J. van Rooij

M. Sluzewski

*St. Elisabeth Ziekenhuis
Tilburg, the Netherlands*

DOI 10.3174/ajnr.A1372

Reference

1. van Rooij WJ, Sluzewski M. **Endovascular treatment of large and giant aneurysms.** *AJNR Am J Neuroradiol* 2009;30:12–18.