

Generic Contrast Agents

Our portfolio is growing to serve you better. Now you have a *choice*.



FRESENIUS
KABI

[VIEW CATALOG](#)

AJNR

Preoperative embolization of hypervascular head and neck neoplasms using microfibrillar collagen.

A J Kumar, S L Kaufman, J Patt, J B Posey, D D Maxwell and R I White, Jr

AJNR Am J Neuroradiol 1982, 3 (2) 163-168

<http://www.ajnr.org/content/3/2/163>

This information is current as
of May 29, 2025.

Preoperative Embolization of Hypervascular Head and Neck Neoplasms Using Microfibrillar Collagen

Ashok J. Kumar¹
 Stephen L. Kaufman¹
 Jerry Patt²
 John B. Posey³
 Daniel D. Maxwell⁴
 Robert I. White, Jr.¹

Microfibrillar collagen is a bovine collagen material that promotes hemostasis. When mixed with contrast material it makes a fine slurry that is easily injected through small catheters. Experience with preoperative embolization of head and neck neoplasms in six patients indicates that microfibrillar collagen slurry is a highly effective, easy to use embolic material for occlusion of highly vascular neoplasms.

A variety of materials has been used to occlude the blood supply of tumors preoperatively. Embolization of head and neck tumors has been usually performed with agents such as Gelfoam [1-3] or Silastic beads [4]. Recently, polyvinyl alcohol foam (Ivalon) has also been introduced as an embolic agent by Latchaw and Gold [5].

Microfibrillar collagen was reported as a new microcrystalline polymer product by Battista et al. [6] in 1967. Kaufman et al. [7] were the first to suggest its use as a transcatheter embolic agent after experimental studies in swine in 1978. After these experimental studies, Diamond et al. [8] embolized nine patients with microfibrillar collagen, four of whom had large vascular renal tumors. Microfibrillar collagen, commercially known as Avitene (Avicon, Inc., Fort Worth, TX), is prepared from purified bovine collagen. It is a white, flourlike substance that mixes readily with contrast agents and is an effective topical hemostatic agent for controlling capillary hemorrhage during surgery [9-14]. Microfibrillar collagen promotes hemostatic action through platelet agglutination and is effective in the presence of heparinization as well as clotting defects [15, 16].

Subjects and Methods

Two patients with carotid body tumors, two with nasopharyngeal angiofibromas, one with a glomus vagale tumor, and one with a meningioma were embolized preoperatively with microfibrillar collagen.

A 7 French intravascular sheath (Cordis) was placed percutaneously into the femoral artery. A 6.5 French reinforced-wall catheter (Cook) was introduced through the sheath and selectively placed into the external carotid artery. We use 6.5 French catheters tapered to 5 French to occlude the major branches of the external carotid artery. Thin suspensions of microfibrillar collagen can be injected through 3 or 4 French catheters for superselective angiography of small external carotid artery branches or in pediatric patients, where 3 or 4 French catheters are preferred. Use of an introducer sheath is highly desirable because it allows rapid exchange for catheters of different sizes and shapes without additional vessel trauma. Also, if catheters are occluded by microfibrillar collagen, Gelfoam, or other particulate materials, they can be easily replaced.

Microfibrillar collagen is available in powder form and readily mixes with contrast material. Small amounts are transferred to a bowl using sterile forceps and mixed with contrast material by rapidly stirring until a thin slurry suspension is made. We now prefer using a suspension with the consistency of thin "pea soup" because there is less chance of catheter occlusion by the slurry and better penetration into small arteries. Aliquots of 0.1

Received December 1, 1980; accepted after revision November 10, 1981.

Presented at the annual meeting of the American Society of Neuroradiology, Los Angeles, March 1980.

¹ Russell H. Morgan Department of Radiology and Radiological Sciences, Johns Hopkins Medical Institutions, Baltimore, MD 21205. Address reprint requests to A. J. Kumar.

² Department of Radiology, Union Memorial Hospital, Baltimore, MD 21218.

³ Department of Neurosurgery, Union Memorial Hospital, Baltimore, MD 21218.

⁴ Department of Radiology, Washington Hospital Center, Washington, DC 20010.

AJNR 3:163-168, March/April 1982
 0195-6108/82/0302-0163 \$00.00
 © American Roentgen Ray Society

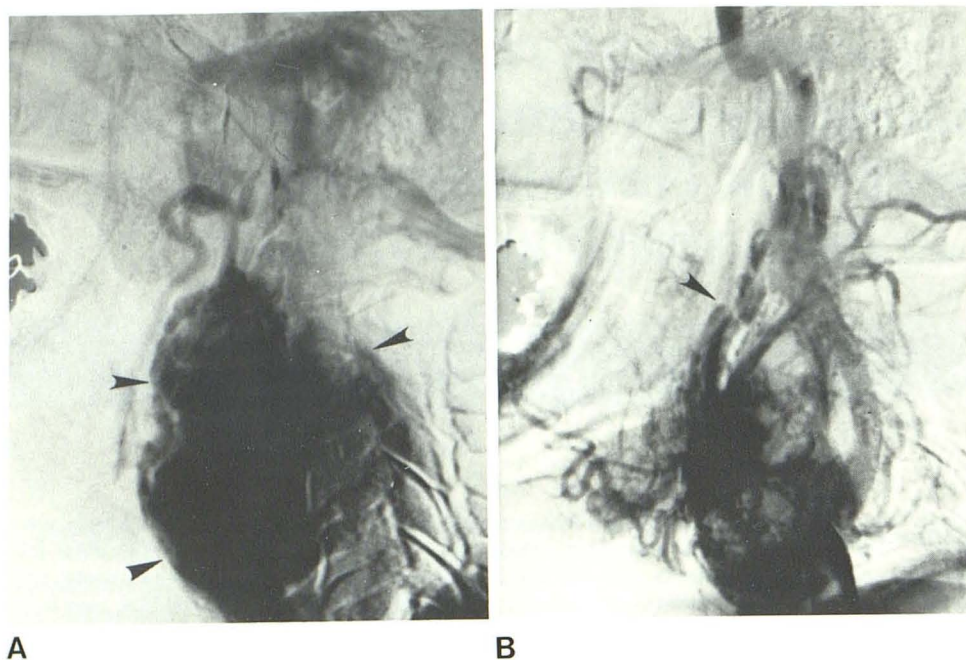


Fig. 1.—Case 1. **A**, Lateral subtraction common carotid angiogram, late arterial phase. Large carotid body tumor (arrowheads). **B**, Postembolization (1.5 ml) common carotid angiogram. Moderate decrease in vascularity of lesion. Distal site of balloon placement into external carotid artery (arrowhead).

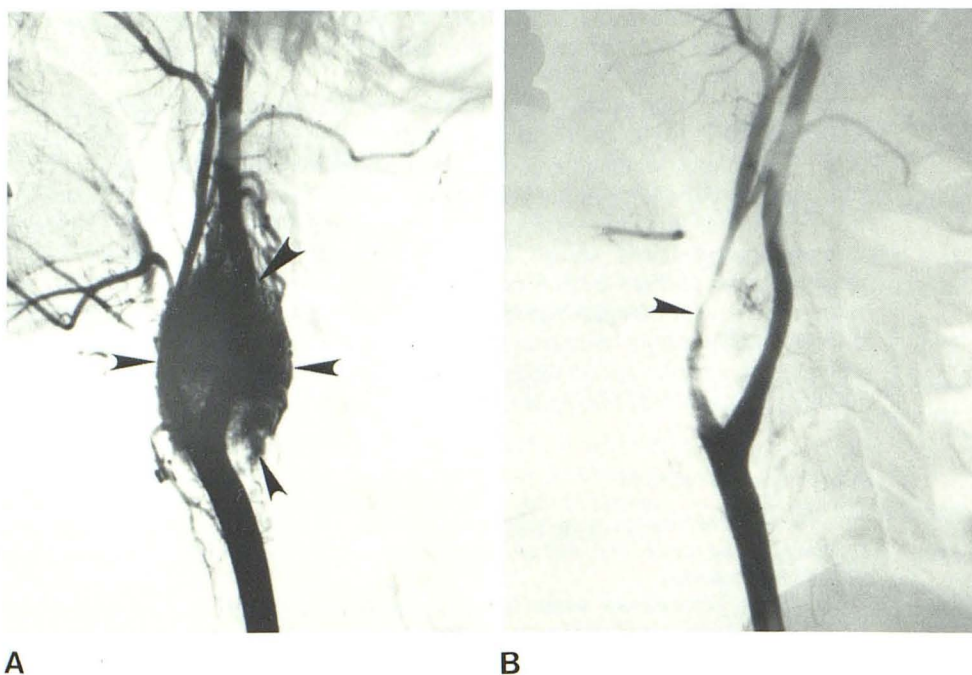


Fig. 2.—Case 2. **A**, Lateral subtraction common carotid angiogram. Carotid body tumor (arrowheads). **B**, Postembolization (4 ml) common carotid angiogram. Marked decrease in vascularity of lesion. Marked narrowing due to vasospasm of proximal external carotid artery (arrowhead).

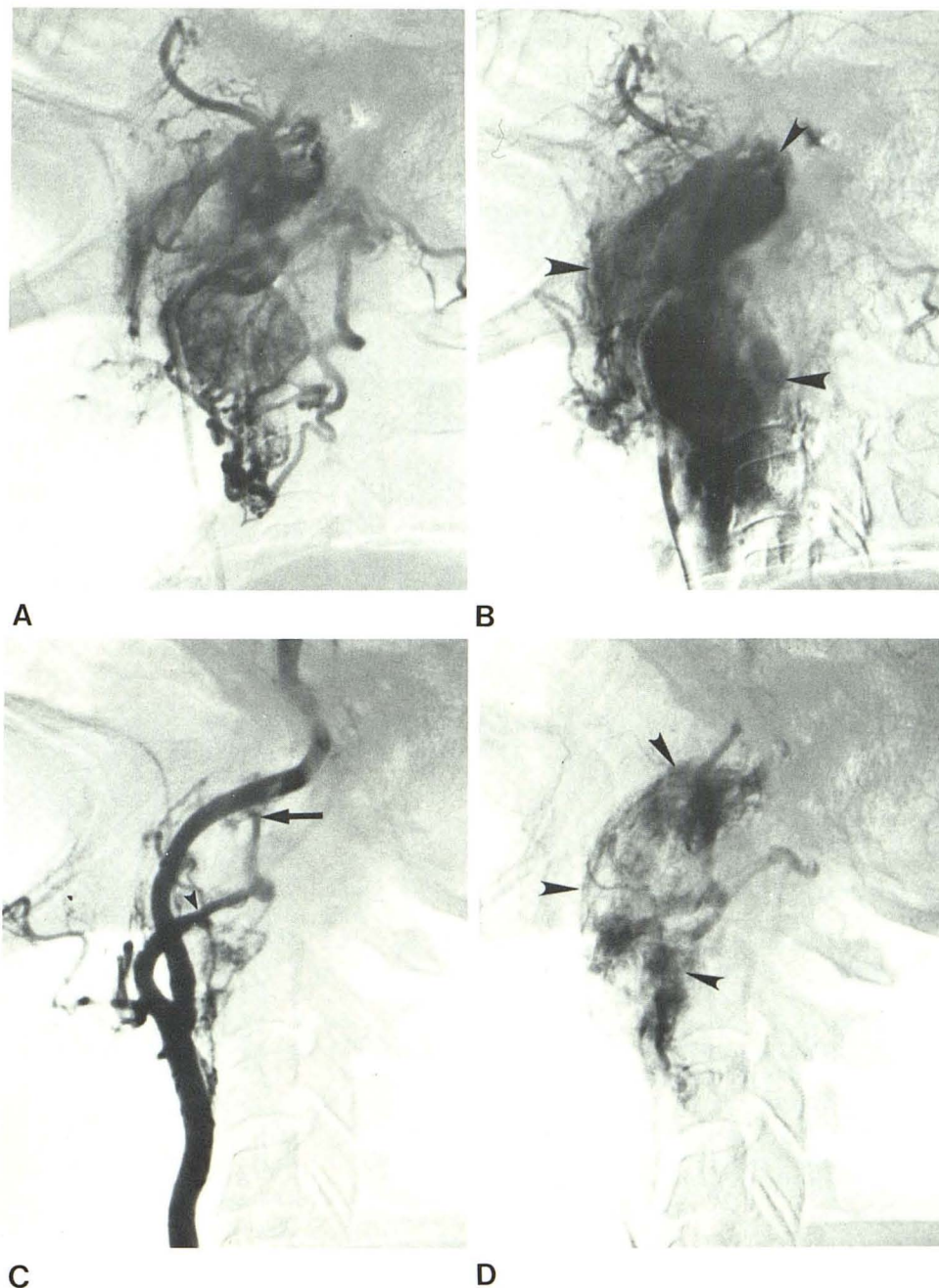
or 0.2 ml of the slurry suspension are aspirated into a 1 ml syringe filled with contrast material and injected through the catheter, followed by gentle flushing with saline or dilute contrast material. In two patients after embolization, balloon occlusion of the proximal external carotid artery was also performed. We used detachable silicone balloons (Miniballoon, Becton-Dickinson) [17] to reduce the amount of particulate materials required for occlusion and to prevent any redistribution of reflux of microfibrillar collagen into the internal carotid artery.

Case Reports

Case 1

A 75-year-old woman with a right neck mass for 25 years noticed growth of the mass 5 weeks before admission. External carotid angiography revealed a large carotid body tumor on the right side (fig. 1A) and a small carotid body tumor on the left. Preoperative embolization of the tumor was performed by embolizing the distal external carotid artery using 1.5 ml of microfibrillar collagen sus-

Fig. 3.—Case 3. **A** and **B**, Lateral subtraction external carotid angiogram in early (**A**) and late (**B**) arterial phase. Large glomus vagale tumor (*arrow-heads*) extends from base of skull to carotid bifurcation. **C** and **D**, Postembolization (4–5 ml) carotid angiogram in early (**C**) and late (**D**) arterial phase. Marked narrowing of distal external carotid artery (*arrow*) with moderate decrease in vascularity of lesion (*arrow-heads*).



pension followed by balloon occlusion of a large branch supplying the tumor. In this patient the detachable balloon was not large enough to occlude the external carotid artery as proximally as intended. Ideally a more proximal occlusion would have been preferred. Postembolization angiography (fig. 1B) showed diminished vascularity of the tumor. After embolization, the tumor was resected. It was the surgeon's impression that the embolization greatly facilitated the procedure. The patient experienced moderate blood loss during the operation, but this was due to accidental laceration of the carotid artery.

Case 2

A 32-year-old patient had a mass in the left neck that grew gradually over a 2 month period. Left carotid angiography demon-

strated a large vascular mass around the carotid bifurcation (fig. 2A). Selective embolization of the external carotid artery was performed with microfibrillar collagen slurry in increments until a total of 4 ml of embolic material had been delivered. Postembolization angiography (fig. 2B) showed marked decrease in vascularity. The next day, the carotid body tumor was surgically removed. The internal carotid artery was an integral part of the tumor and a vein graft had to be placed between the common carotid artery and the distal internal carotid artery. Estimated blood loss was 500 ml.

Case 3

A 67-year-old patient with a large glomus vagale tumor largely supplied by external carotid branches (figs. 3A and 3B) had embolization. The external carotid artery was occluded (figs. 3C and

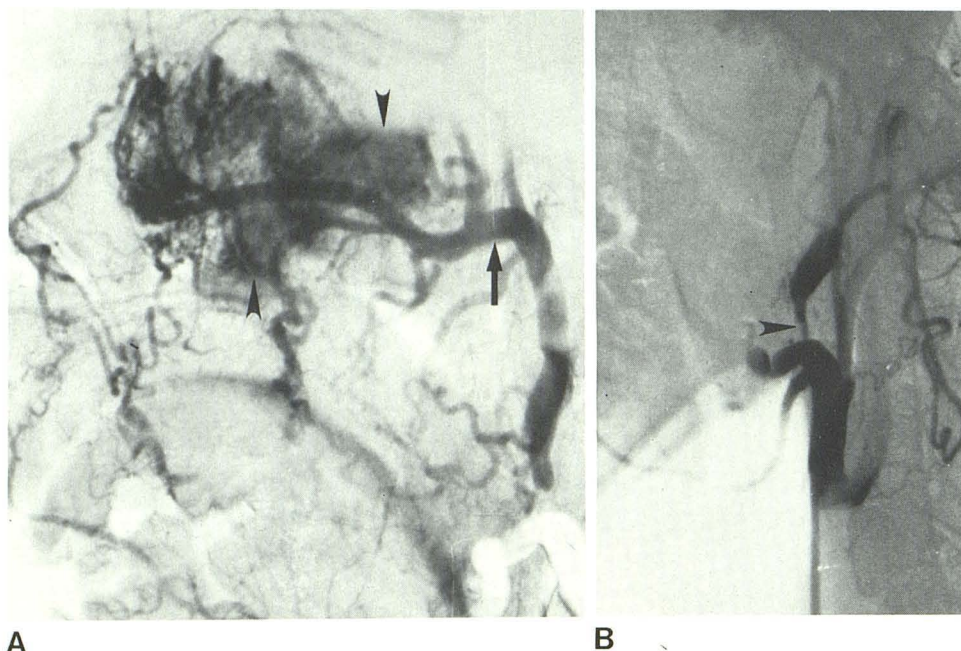


Fig. 4.—Case 4. **A**, Lateral subtraction external carotid angiogram. Nasopharyngeal angiofibroma (arrowheads) fed by hypertrophied internal maxillary artery (arrow) and its branches. **B**, Postembolization external carotid angiogram. Vasospasm of proximal external carotid artery (arrowhead) secondary to embolization; occlusion of internal maxillary artery.

3D) with 4–5 ml microfibrillar collagen suspension with some decrease in the vascularity of the lesion noted. The tumor was resected the next day with a blood loss of 200 ml.

Case 4

A 21-year-old man developed marked epistaxis 2 years after diagnosis of a juvenile angiofibroma of the nasopharynx. Partial resection had been previously performed. Left external carotid angiography (fig. 4A) demonstrated a large vascular nasopharyngeal tumor supplied primarily by branches of the internal maxillary artery. The tumor also derived its blood supply from the left internal carotid artery and right external carotid artery. Selective embolization of the left external carotid artery was performed with microfibrillar collagen slurry (fig. 4B). A total of 3.0 ml of embolic material caused complete occlusion of the left external carotid artery which largely supplied the tumor and immediate cessation of epistaxis occurred. The patient refused surgery.

Case 5

A 14-year-old boy had a juvenile nasopharyngeal angiofibroma supplied by the left internal maxillary artery with small feeding vessels from the ipsilateral internal carotid artery. The left internal maxillary artery was embolized using 3.0 ml of microfibrillar collagen. Unfortunately, a vascular sheath was not used and a thicker than necessary slurry resulted in occlusion of the catheter. The catheter was withdrawn without a postocclusion angiogram and the right side was not embolized. After embolization, a large lobulated tumor was removed. The surgeon believed that the procedure was greatly facilitated by the embolotherapy. Microscopic sections of the tumor revealed eosinophilic-stained microfibrillar collagen in arteries estimated to be about 500 μ m in diameter (fig. 5).

Case 6

A 56-year-old man had a meningioma supplied by the middle meningeal artery. The internal maxillary artery was embolized with

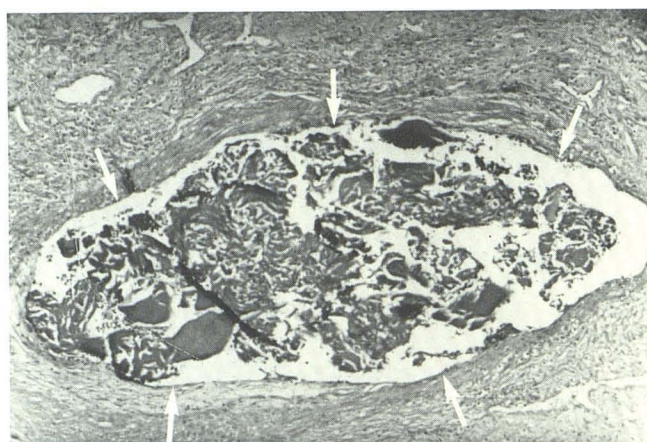

Fig. 5.—Case 5. Photomicrograph reveals microfibrillar collagen within arterial lumen (arrows) estimated to be about 500 μ m in diameter.

0.6 ml of microfibrillar collagen suspension followed by balloon occlusion at the point of stasis in the distal external carotid artery. In this instance, the balloon was probably not necessary, but in more proximal embolizations of the external carotid artery where there is a danger of reflux into the internal carotid artery, a detachable balloon can reduce the amount of particulate material required. On the next day, the patient underwent craniotomy with removal of the meningioma; the neurosurgeons specifically noted that blood loss was minimal during the operation.

Discussion

In vitro interactions of blood cells with collagen at the ultrastructural level were studied by Zucker and Mason [18]. They observed through scanning and transmission electron microscopic studies that platelets adhere to collagen, pro-

ducing morphologic changes within the platelet resulting in release of platelet products. After the release of products from platelets, platelet aggregation was observed. Thus microfibrillar collagen seems to exert its hemostatic effects largely through promotion of platelet aggregation. Microfibrillar collagen has been shown to be effective in the presence of heparinization as well as intrinsic clotting defects, but much less effective in thrombocytopenia. These observations led to the wide use of the material as an effective topical hemostatic agent for surgery.

Kaufman et al. [7] evaluated the effectiveness of microfibrillar collagen as a transcatheter embolic agent and its long-term effect on embolized tissues. Embolized vessels remained occluded at 2 days with only variable amounts of residual organized thrombosis at 3 months. The material was considered to be an effective medium-duration embolic agent, similar in this respect to Gelfoam. Early, a marked granulomatous arteritis was seen within the vessel walls and perivascular areas in all animals after intraarterial injection of microfibrillar collagen with clearing of the inflammatory response within 3 months. No inflammatory response is observed when the material is used as a topical hemostatic agent, and no clinical evidence of inflammation was noticed after intraarterial injection in any of our patients. We expect that some of the inflammatory changes observed after intraarterial injection of microfibrillar collagen in animals is partly because of distal necrosis of tissue embolized.

After embolization, one of our patients developed facial pain during mastication which resolved in 72 hours. There were no similar side effects in the other five patients. Ischemic cranial nerve palsy has been reported by Lasjaunias [19] from external carotid artery embolization. Knowledge of transcranial vascular supply to cranial nerves from branches of the external carotid artery and careful superselective angiograms should be evaluated before embolization to prevent the potential complication of cranial nerve palsy after occlusion of their blood supply. Cranial nerve palsies did not occur in any of our patients.

Careful search for potential communications between extracranial arteries like the occipital artery with intracranial branches such as the vertebral artery should be made before embolization. Again, no extra-to-intracranial anastomoses were demonstrated in the branches we embolized. By slowly injecting thin dilutions of microfibrillar collagen in 0.1–0.5 ml increments, high pressure in the embolized arteries is avoided, thus reducing the potential for emboli to cross these anastomoses when they are present. Of course, careful fluoroscopic monitoring is needed during and after each injection, and the embolization is stopped as soon as stasis is observed in the embolized artery [20].

We prefer to use microfibrillar collagen for preoperative embolization of hypervascular neoplasms of the head and neck for two reasons: (1) semiliquid suspensions pass readily through small catheters, with less chance for catheter recoil or inadvertent embolization of neighboring arteries than with the other agents, and (2) microfibrillar collagen can penetrate the small end arteries of a lesion, down to 100 μ m in diameter, thus propagating into blood vessels more distally than polyvinyl alcohol foam (Ivalon) or Gelfoam sponge. Ivalon and Gelfoam sponge are ideal for occluding

medium-sized to large vessels, but to produce occlusion of smaller vessels at the precapillary level, microfibrillar collagen is preferred.

While we have no experience with Gelfoam powder, it is possible that equivalent vascular penetration might be achieved with it. However, our limited experience suggests that microfibrillar collagen is a safe and effective occluding material for highly vascular head and neck neoplasms.

ACKNOWLEDGMENTS

We thank Diana G. Beatty and Dee Deinlein for assistance with manuscript preparation.

REFERENCES

1. Berenstein A, Kricheff II. Catheter and material selection for transarterial embolization: technical consideration. II. Materials. *Radiology* **1979**;132:631–639
2. Roberson GH, Price AC, Davis JM, Gulati A. Therapeutic embolization of juvenile angiofibroma. *AJR* **1979**;133:657–663
3. Berenstein A, Russell E. Gelatin sponge in therapeutic neuro-radiology: a subject review. *Radiology* **1981**;141:105–112
4. Hilal SK, Michelsen JW. Therapeutic percutaneous embolization for extra-axial vascular lesions of the head, neck and spine. *J Neurosurg* **1975**;43:275–287
5. Latchaw RE, Gold LA. Polyvinyl foam embolization of vascular and neoplastic lesions of the head, neck and spine. *Radiology* **1979**;131:669–679
6. Battista OA, Erdi NZ, Ferraro CF. Novel microcrystals of polymers. *J Appl Polymer Sci* **1967**;11:481–498
7. Kaufman SL, Strandberg JD, Barth KH, White RI Jr. Transcatheter embolization with microfibrillar collagen in swine. *Invest Radiol* **1978**;13:200–204
8. Diamond NG, Casarella WJ, Bachman DM, Wolff M. Microfibrillar collagen hemostat: a new transcatheter embolization agent. *Radiology* **1979**;133:775–779
9. Murphy DJ, Clough CA. A new microcrystalline collagen hemostatic agent. *Surg Neurol* **1974**;2:77–79
10. Abbott WM, Austen WG. Microcrystalline collagen as a topical hemostatic agent for vascular surgery. *Surgery* **1974**;75:925–933
11. Vistens LM, Goldwin DA, Tenery JH, Ksander GA, Gruber RP. Control of capillary bleeding by topical application of microcrystalline collagen. *Surgery* **1974**;76:291–294
12. Cobden RH, Thrasher EL, Harris WH. Topical hemostatic agents to reduce bleeding from cancellous bone. A comparison of microcrystalline collagen, thrombin and thrombin-soaked gelatin foam. *J Bone Jt Surg [Am]* **1976**;58:70–73
13. Cameron WJ. A new topical hemostatic agent in gynecologic surgery. *Obstet Gynecol* **1978**;51:118–122
14. Rybock JC, Long DM. Use of microfibrillar collagen as a topical hemostatic agent in brain tissue. *J Neurosurg* **1977**;46:501–505
15. Abbott WB, Austen WG. The effectiveness and mechanism of collagen-induced topical hemostasis. *Surgery* **1975**;78:723–729
16. Schitteck A, Demetriou AA, Seifter E, Stein JM, Levenson SM. Microcrystalline collagen hemostat and wound healing. *Ann Surg* **1976**;184:697–704
17. White RI Jr, Barth KH, Kaufman SL, DeCaprio V. Therapeutic

- embolization with detachable balloons. *Cardiovasc Intervent Radiol* **1980**;3:229-241
18. Zucker WH, Mason RA. Ultrastructural aspects of interactions of platelets with microcrystalline collagen. *Am J Pathol* **1976**;82:129-142
19. Lasjaunias P. Nasopharyngeal angiofibromas: Hazards of embolization. *Radiology* **1980**;136:119-123
20. Ahn HS, Kerber CW, Deeb ZL. Extra- to intracranial arterial anastomoses in therapeutic embolization: recognition and role. *AJNR* **1980**;1:71-75