



## Discover Generics

Cost-Effective CT & MRI Contrast Agents



FRESENIUS  
KABI

WATCH VIDEO

# AJNR

## Spinal Trauma: An Imaging Approach

*AJNR Am J Neuroradiol* 2008, 29 (5) e35

doi: <https://doi.org/10.3174/ajnr.A0976>

<http://www.ajnr.org/content/29/5/e35>

This information is current as  
of June 22, 2025.

## BOOK REVIEW

### Spinal Trauma: An Imaging Approach

V.N. Cassar-Pullicino and H. Imhof, eds. New York: Thieme; 2006, 256 pages, 18 tables, 439 illustrations, \$149.95.

With the improved visualization of the injured spine with multidetector CT and the emerging strategies in MR imaging for determining neural tissue damage, more and more attention is being directed to a complete imaging description of the extent of spine injuries, including osseous vascular, ligamentous, neural, and soft-tissue abnormalities. With that in mind, this 256-page book strives first to cover the basic concepts of spine injury, including clinical perspectives and biomechanics/pathophysiology and then, in great detail, describes image optimization, classification of injuries, spine malalignment, bony vertebral injuries, spinal cord and vertebral artery injuries, pediatric spine injuries, sports injuries (both spondylolysis and overuse of the diskovertebral unit), injuries to the rigid spine (as in diffuse idiopathic skeletal hyperostosis and ankylosing spondylosis), spine trauma in the elderly, chronic spinal cord injuries, vertebral osteoporosis and benign fractures, and the neuropathic spine. Most important for radiologists, there is a brief discussion of the management options, including the initial (acute) management, pharmacologic intervention, nonsurgical strategies including orthotic management, and a description of the benefits of an anterior-versus-posterior spinal approach when surgery is deemed necessary. Interrogatives at the end of this chapter add interest because questions that many readers would themselves ask are posed.

Integrated within the book and often within each chapter are contributions by orthopedic surgeons on patient treatment and outcome. Thus, one has here a book that addresses both the radiology and clinical aspects of spinal injury. Throughout, the book is well written and appropriately illustrated. This reviewer found the chapter on the overuse injuries of the diskovertebral junction of unusual interest, primarily because it is controversial and the theories discussed are not widely known. Other areas of particular note include classifi-

cation of spine injuries, and even more relevant is a discussion of why such classifications are important. This is addressed under the heading “Do We Need Any Classification At All?”—a question many radiologists would ask after looking at the “Comprehensive Classification” and the subdivisions of type A (vertebral body compression), type B (anterior and posterior element injury with distraction), and type C (anterior and posterior injury with rotation or translation) injuries.

Excellent radiographs and diagrams in all chapters serve to show these fractures. CT scans are used liberally to demonstrate the crucial nature that this technique plays in assessing spine injuries. Adequate MR imaging provides insight into its value in neurovascular injuries (cord and vessels) and in the long-term consequences of spine and spinal cord injuries. One would hope that by the time a future edition of this valuable text is in print, state-of-the-art MR imaging techniques, such as diffusion-weighted imaging and quantitative CSF flow measurements, which are under evaluation for the spine, would be included. Perhaps such techniques would allow more insights into the ongoing pathophysiologic changes present in the acute and chronically injured spine.

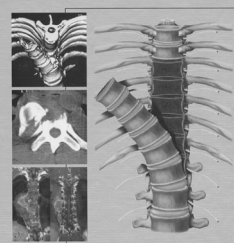
Although the chapter on “The Future: Trends and Developments in Spinal Cord Regeneration” is short (3 pages is too short for this topic), at least the issues of neuroprotection, neural tissue regeneration/transportation, and neurorehabilitation are brought to the forefront. Radiologists ought to know that some day when exquisite details of the spinal cord are possible in a clinical context, they may be monitors of the success of many of these evolving therapeutic schemes.

This book is recommended to all radiologists and those clinicians who deal with spine injuries.

DOI 10.3174/ajnr.A0976

### Spinal Trauma— An Imaging Approach

Victor N. Cassar-Pullicino  
Herwig Imhof



Thieme