



Discover Generics

Cost-Effective CT & MRI Contrast Agents



FRESENIUS
KABI

WATCH VIDEO

AJNR

Imaging of Carotid Artery Stenosis

AJNR Am J Neuroradiol 2008, 29 (3) e7-e8

doi: <https://doi.org/10.3174/ajnr.A0881>

<http://www.ajnr.org/content/29/3/e7>

This information is current as
of June 24, 2025.

Imaging of Carotid Artery Stenosis

B.J. Schaller, ed. New York: Springer Wien; 2007, 273 pages, 86 illustrations, \$259.00.

Stroke remains a major cause of morbidity and mortality worldwide, despite our ever-growing understanding of cerebrovascular disease and its risk factors. Current strategies for prevention of stroke in patients with known carotid stenosis continue to rely on relatively crude measurements of stroke risk, namely the presence of ischemic symptoms and the severity of vessel stenosis. As such, our ability to reliably determine which patients with carotid stenosis will actually go on to have strokes is far from perfect. Fortunately, in recent years we have seen the development of a number of new breakthroughs in carotid imaging which offer hope that we may one day be able to predict accurately which patients would truly benefit from surgical and endovascular interventions (ie, endarterectomy, angioplasty, and stent placement) and which could be treated adequately with medical management. With new imaging technologies arriving at a breakneck pace, the task of staying abreast of the field of carotid imaging can be difficult. Enter the new book *Imaging of Carotid Artery Stenosis*, edited by Dr. Bernhard Schaller.

Weighing in at a modest 273 pages, this book covers a broad array of topics related to the radiologic diagnosis of carotid atherosclerotic disease and lists among its contributors a number of international experts on the field of cerebrovascular imaging. The text is divided into 5 main sections, and each section is further divided into several chapters, with a total of 16 chapters.

Section 1, entitled "Imaging Examination Techniques of Carotid Artery," opens with a succinct review of atherosclerotic plaque pathogenesis and morphology, including a discussion on morphologic factors associated with plaque vulnerability. Subsequent chapters cover specific modalities used in carotid imaging, including sonography, digital subtraction angiography, CT, and positron-emission tomography (PET). A brief discussion on plaque morphology imaging with MR is also included in this section, but this topic is discussed in greater detail in Section 2. Various aspects of the techniques, such as their role in contemporary clinical practice, relative strengths and weaknesses, study interpretation, and areas for future investigation are discussed in a fair amount of detail.

Section 2, "Specific Pathologic Problems in Carotid Artery Imaging," covers common entities that affect the carotid and intracranial arteries, including atherosclerotic plaque, carotid artery dissection, and intracranial stenoses. The first chapter in the section, "Atherosclerotic Plaque Characterization by Imaging," is a well-written and concise review of current state-of-the-art techniques

for carotid plaque evaluation, including intravascular sonography, morphologic imaging with high-resolution MR, and functional and inflammatory imaging with PET and ultra-small paramagnetic iron oxide particle-enhanced MR. The last chapter in the section covers advanced intracranial imaging techniques, including MR perfusion imaging and transcranial Doppler sonography.

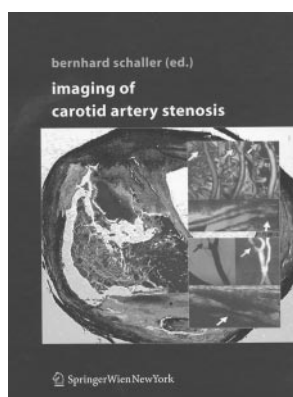
Section 3 consists of a single chapter, "From Imaging to Therapy in Carotid Artery Stenosis," which addresses topics related to preoperative and perioperative imaging. Practically speaking, this chapter could have been incorporated into the next section (perhaps the most original aspect of this book), "Therapy and Carotid Artery Imaging," which covers carotid and intracranial imaging after therapy, including evaluation after extracranial-to-intracranial bypass, carotid endarterectomy, and carotid stent placement. The final chapter addresses future prospects for carotid imaging, with a focus on molecular imaging.

Although the book provides a reasonable amount of accurate, up-to-date information, its overall execution leaves something to be desired. A significant flaw of the book relates to the lack of a common chapter format, which makes for a fairly disjointed reading experience. Chapter quality is uneven, and rather than reading as a single unified text, the book feels more like a collection of articles culled from multiple disparate sources. A relatively weak attempt is made to tie the chapters together by concluding them with a section of "take-home-messages," which are meant to represent the major teaching points of each chapter. Unfortunately, this feature is inconsistent in its execution, and several of the chapters fail to even include a "take-home-message" section. A further shortcoming of the book is the lack of a subject index, which makes the task of locating information on a particular topic extremely frustrating at times.

It is surprising that for such a short book, there is a fair amount of redundancy between sections, with similar topics being covered repeatedly in more than 1 place. With the large number of contributors to the book (33 to be exact), some redundancy is to be expected, but in this case the redundancies amount to wasted text. As an example, chapters 1.6 ("Intracerebral Imaging and Carotid Artery Stenosis") and 2.4 ("Intracranial MR and Vascular Imaging in Patients with Extracranial Carotid Stenosis") contain much of the same information pertaining to intracranial MR imaging, including sections on conventional MR images, diffusion-weighted imaging, and perfusion imaging. Although some different information is presented in each of the 2 chapters, it might have made more sense had they been combined into a single chapter. A bit more editorial oversight during the creation of the book may have made for a more cohesive finished product.

Grammatical errors litter the text to the point of distraction. Occasional errors in grammar and syntax are not unusual when authors are not native English speakers, but this problem can be minimized, or even eliminated, with decent proofreading. The proofreaders must have had the day off when it came time to work on this book.

The quality of the illustrations runs the gamut from very good to so-so, and the quality of the figures and descriptiveness of the legends vary from chapter to chapter. I noticed that



several figures were clearly mislabeled in their captions, which further detracted from the overall quality of the book.

Editorial and proofreading shortcomings aside, Dr. Schaller and the book's contributors should be lauded for their efforts to create an up-to-date text that brings together in 1 place a wide range of topics related to carotid imaging. Subjects contained in the book are covered with reasonable, though not outstanding, depth, and though much of the book covers state-of-the art techniques not widely used outside of the academic setting, plenty of information between the covers can be applied to everyday practice. With that in mind, I would say that this book is probably more appropriate for a neuroradiologist working in a large stroke

center than it is for a radiologist practicing in a small community hospital.

In the end, *Imaging of Carotid Artery Stenosis* is a hit-or-miss affair. The book capably serves as an introduction to current state-of-the-art carotid imaging and sets a framework for understanding possible advances that may lie just around the bend. Unfortunately, an overall lack of editorial direction makes the creators' endeavors come across often as amateurish. The shame is that there is definitely a need in the world of radiology literature for a comprehensive textbook on the topic of carotid imaging, but ultimately, this is not the ideal book to fill that need.

DOI 10.3174/ajnr.A0881