



Discover Generics

Cost-Effective CT & MRI Contrast Agents



FRESENIUS
KABI

WATCH VIDEO

AJNR

Medical Technologies in Neurosurgery (Acta Neurochirurgica Supplementum), Supplement 98

AJNR Am J Neuroradiol 2008, 29 (2) 403-404

doi: <https://doi.org/10.3174/ajnr.A0835>

<http://www.ajnr.org/content/29/2/403.2>

This information is current as
of June 22, 2025.

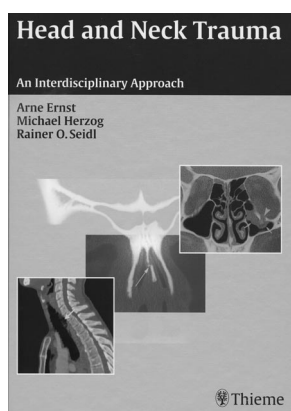
BOOK REVIEWS

Section Editor: Robert M. Quencer

Head and Neck Trauma: An Interdisciplinary Approach

A. Ernst, M. Herzog, and R.O. Seidl, eds. New York: Thieme Medical Publishers; 2006. 236 pages, 249 illustrations, \$129.95.

Despite what is suggested in the title, this book is only interdisciplinary if one excludes radiology as a discipline. It is a clinical book written by ear, nose, and throat (ENT) or maxillofacial surgeons only. It is not geared toward radiologists, though it does contain some imaging. This relatively short book does contain much good solid information on the subject of trauma to the facial region, skull base, and neck. The book is divided into 3 broad sections. The initial section has individual chapters dealing with emergency management, first aid, and principles of trauma care, which include much valuable information about the initial care for patients with such injuries. Some of the material comprises physical findings, triage, flow charts for individual types of injuries, and general information on trauma management. Although not specifically relevant to radiology per se, this section probably contains good general knowledge for anyone who might encounter a trauma on the street or be compelled to perform an emergency cricothyrotomy in



a restaurant.

The second section is divided into chapters devoted to individual trauma sites such as the cranium and craniocervical junction, skull base, ear and temporal bone, facial nerve, orbit, mandible, teeth, pharynx and soft-tissue neck, and laryngotracheal area. These chapters are subclassified into sections on surgical anatomy, mechanisms and classifications of injuries, clinical signs and symptoms, diagnosis (to include a small amount of imaging), and treatment. Although the accompanying illustrations (gross photographs and diagrams), imaging, and tables are of uniformly high quality, it seems that these chapters really provide an overview, not a comprehensive treatise on the subject. Furthermore, the amount of imaging is fairly limited. Having said that, I found the presentation of the orbital and maxillofacial fractures to be quite good.

The third and final section is devoted to therapy of head and neck trauma. It includes chapters that are devoted to the same injury sites that were discussed in the chapters on diagnosis. These sections are almost entirely clinical, with relatively few radiographs.

In summary, this relatively compact yet very readable book is clearly not geared toward radiologists. In fact, I am not aware of any book on this subject that is specifically intended for radiologists. Who then is the ideal target audience? Clearly

able information about the initial care for patients with such injuries. Some of the material comprises physical findings, triage, flow charts for individual types of injuries, and general information on trauma management. Although not specifically relevant to radiology per se, this section probably contains good general knowledge for anyone who might encounter a trauma on the street or be compelled to perform an emergency cricothyrotomy in

surgical and ENT trainees would benefit. As for radiologists who want to be taken seriously, there is a clear-cut benefit in understanding the clinical aspects of trauma management and, indeed, of any disease. This knowledge makes us better radiologists, and it also facilitates intelligent communication with the treating physician. I believe this book has enough clinical pearls to be useful in the radiology reading room of a busy trauma department and perhaps any emergency department. This book might just suggest questions for the radiologist to ask the clinician that would clarify not only image interpretation but possibly imaging strategies as well.

DOI 10.3174/ajnr.A0834

BOOK REVIEW


Medical Technologies in Neurosurgery (Acta Neurochirurgica Supplementum), Supplement 98

C. Nimsky and R. Fahlbusch, eds. New York: SpringerWien; 2006. 103 pages, 6 partly colored figures, \$129.00.

This book is Supplement 98 of *Acta Neurochirurgica*, and it contains the proceedings of a joint meeting of the Academia Eurasian Neurochirurgica and the German Academy of Neurosurgery held in September 2005. The first 4 chapters in the book consist of discussions of ethical principles related to the application of technology to medicine. These ethical principles are discussed from the perspectives of 4 different religious traditions. Next is a chapter with an overview of the current status of medical technology, followed by a chapter on diffusion tensor imaging. The next 3 chapters cover robotic surgery, and the final 4 chapters discuss intraoperative MR imaging.

The first chapter is entitled "Bioethics, Technology and Human Dignity: The Roman Catholic Viewpoint." This chapter begins with a discussion of the appearance of the first humans and their humanlike ancestors in relation to the age of the universe and then discusses human ecology and the Catholic concept of human dignity. The Catholic outlook on research involving human embryos is discussed, including aspects of stem cell research. The chapter concludes with a discussion of "dignity versus quality of life."

The next chapter discusses Jewish ethical perspectives on robotics and artificial intelligence. The author explains that man has the power to improve creation but that the principle of "first do no harm" takes precedence. Examples such as deep brain stimulation and cortical stimulation are discussed. Popular concepts of such medical technologies as reflected in science fiction literature and



movies are discussed, and intersections of such stories with Jewish folklore are presented. The point is made that Jewish ethics allows a permissive attitude for scientific innovations, as long as risks are kept to an acceptable level.

The next chapter discusses Islamic viewpoints on the ethics of new technologies in neurosurgery. A substantial part of this chapter is devoted to 6 interviews with Islamic theologians. These interviews discuss such principles as free will and personal responsibility.

The final chapter on ethics covers Buddhism and Shintoism in neurosurgical practice in Japan. This chapter includes discussion of brain death and organ transplantation from brain dead patients and its relative infrequency in Japan. The influence of Buddhism and Shintoism on such practices is discussed.

Inclusion of chapters on the ethics of current medical technology is a somewhat unusual finding in such a compendium. This certainly can be taken as a worthwhile reminder to the reader that there are ethical questions to be considered in the development and application of new medical practices.

The review chapter on the current status of medical technology is mostly just a listing of various modern medical technologies, including both those in current application and those that are investigational. There is some discussion of the economics of innovation in medical technology, with a specific discussion of the economy of Germany.

The chapter on fiber tracking by using diffusion tensor imaging will be of interest to neuroradiologists. The authors present a method to assess uncertainty in fiber reconstructions on the basis of variational complex gaussian noise. The chapter concludes that this approach allows investigation of the uncertainty of fiber tracking by using diffusion tensor imaging. The chapter includes a detailed technical discussion of the algorithm.

The next 3 chapters discuss robotics in neurosurgery. The first chapter begins with devices that are currently available in clinical practice, including a robotized surgical microscope and the CyberKnife stereotactic radiosurgical instrument (Accuray, Sunnyvale, Calif). Next discussed is a robotized arm used for stereotactic surgical procedures for deep brain stimulation. The next chapter describes an investigational robot system for skull opening and closure. The third chapter describes a robotic micromanipulator system for minimally invasive neurosurgery. Use of this system for procedures currently performed with neuroendoscopy, such as third ventriculostomy, is described. Cadaver experiments are described, and an investigational use of the device in a patient for partial removal of a recurrent meningioma is discussed. Another experiment with this device was performed by using remote control of the device with the robot placed 40 km away from the controller. Successful use of the system in this fashion to perform telesurgery on an experimental rat brain preparation is presented. Obviously, the proper role of these experimental devices remains to be determined, but the neuroradiologist is likely to be at least somewhat interested in these descriptions.

The final 4 chapters discuss intraoperative MR imaging by using different MR imaging field strengths. The first of these chapters describes use of a 0.3T system in Japan for

removal of gliomas. The technical setup is well described and illustrated. Interesting results include the data that show that more radical resections were achieved during the later experience with this system compared with earlier experience. The more aggressive resections, however, were accompanied by significantly higher short-term neurologic deterioration, though long-term neurologic outcome was said to be similar between the earlier patients and the later patients. The next chapter describes the vertical double-doughnut intraoperative MR imaging unit at the Brigham and Women's Hospital in Boston. The mechanics of performing surgery in this 0.5T unit are described for stereotactic biopsy, craniotomy, transsphenoidal resection, and other procedures. Imaging findings are discussed. This chapter is clearly written and is a useful overview of the details of performing surgery in an MR imaging scanner. The next chapter describes intraoperative high-field MR imaging with the 1.5T system at Erlangen, Germany. Experience with craniotomy for gliomas and transsphenoidal resection of pituitary tumors is described. As with the other systems, the incorporation of stereotactic neuronavigation systems and functional data is described. The conclusion in this chapter is that use of the high-field system allows improved resections with lower morbidity. The final chapter is a relatively brief description of the preliminary results of intraoperative MR imaging with a 3T system. That system requires transfer of the patient from the operating room to an immediately adjacent imaging room. All of these chapters on intraoperative MR imaging will be of interest to the neuroradiologist. Interpretation of intraoperative MR images requires some specific experience, and these chapters offer such insights.

This book is a collection of papers by different authors, so style is variable, and many of the papers have rather stilted English, which can make reading tedious. Overall, illustration is relatively limited, but in some chapters, particularly the 4 covering intraoperative MR imaging, the illustrations are quite useful. These 4 chapters will probably be the most interesting to the neuroradiologist, because they do provide not only a broad overview of the variety of systems and techniques but also some concrete information on interpreting the intraoperative images.

DOI 10.3174/ajnr.A0835

BOOK REVIEW

Neuroradiology Third Series, Test and Syllabus, Vol. 51

M. Castillo and J.G. Smirniotopoulos, eds. Reston, Va: ACR Publications; 2006, \$180.00 member, \$250 nonmember, \$98.00 member-in-training.

The time-honored American College of Radiology (ACR) *Test and Syllabus* now has its newest neuroradiology book edited by Drs. Mauricio Castillo and James Smirniotopoulos, with 5 additional contributors: Drs. Falcone, Rumboldt, Fukui, Smith, and Mukherji. While this syllabus is aimed at