



Discover Generics

Cost-Effective CT & MRI Contrast Agents



FRESENIUS
KABI

WATCH VIDEO

AJNR

Clinical MR Neuroimaging: Diffusion, Perfusion and Spectroscopy

AJNR Am J Neuroradiol 2006, 27 (2) 463-464
<http://www.ajnr.org/content/27/2/463>

This information is current as
of June 27, 2025.

BOOK REVIEW

Clinical MR Neuroimaging: Diffusion, Perfusion and Spectroscopy

Jonathan Gillard, Adam Waldman, and Peter Barker, eds. Cambridge: Cambridge University Press; 2005, 852 pages, \$330.

The newly published *Clinical MR Neuroimaging: Diffusion, Perfusion and Spectroscopy*, edited by Jonathan Gillard, Adam Waldman, and Peter Barker, brings under one title a review of many of the advanced techniques and their applications in neuro MR imaging. This is multiauthored text with 80 contributors, both MR physicists and clinical neuroradiologists, who have special expertise in the use of state-of-the-art MR applications.

The book is divided into 8 sections, the first of which is entitled "Physiologic MR Techniques." This section gives the basic background information which is needed to appreciate the 7 sections that follow, because these 7 sections are disease-oriented and involve primarily the implementation of advanced techniques in each disease category.

In this era of a plethora of case-based textbooks, it is important to have on hand a text that immediately immerses the reader into advanced techniques, precluding material on routine MR imaging. This was a wise decision by the editors because material on the basics of MR abound. Because this type of MR information is not included, the reader must have a basic understanding of MR physics beforehand. Therefore, the book begins (section 1) with the fundamentals of MR spectroscopy, followed sequentially by quantification, analysis, and pitfalls of MR spectroscopy. The same pattern is repeated for diffusion imaging (fundamentals, tractography, artifacts, and pitfalls) and cerebral perfusion (perfusion with exogenous contrast agents, rCBF with arterial spin-labeling, and artifacts and pitfalls in MR perfusion). Thus, in the first 160 pages, the reader receives the basic information needed to appreciate the clinical material which follows in the 3 major foci of the book—spectroscopy, diffusion, and perfusion. Each area is written with the practicing radiologist in mind with good drawings and easy to follow text.

The following areas are discussed in separate sections: cerebrovascular disease; adult neoplasia; infection/inflammation/demyelination; seizure disorders; psychiatric and neurodegenerative diseases; trauma; and pediatrics. Conspicuously absent is a separate chapter on spine (there is only a brief mention of the spine in the demyelination chapter), and, because of this, the

book should have been entitled *Clinical MR Brain Imaging*. Although it is recognized that minimal clinical material has been accumulated by using advanced techniques in the spine, there have been reports of application of diffusion imaging tractography, CSF flow studies, and even functional MR (fMR) imaging of the spinal cord, all of which should have been incorporated into a short chap-

ter. It is hoped that in a future edition that the editors will consider this important area of neuroimaging.

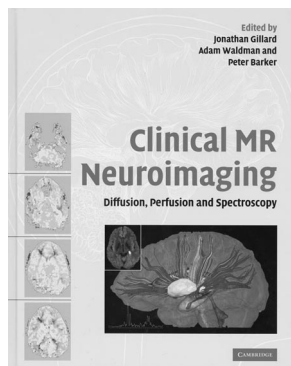
Each of the 7 sections start off with a brief introduction called an "overview," and then each chapter begins with a summary of the chapter entitled "key points." There are straightforward descriptions of the techniques with clinical examples, ending with a separate section called "case studies." The print is large, the text uncluttered, and the image quality by and large is excellent, though a few images are unnecessarily dark. Each contributor's style varies, but what makes a few chapters enjoyable is the posing of questions, many of which are often raised in the context of clinical imaging such as, "does diffusion-weighted imaging differentiate transient ischemic attack from stroke?" or "how long do diffusion-weighted imaging and apparent diffusion coefficient values remain abnormal in acute stroke?" It would have been even better had every chapter contained a number of these questions followed by an appropriate discussion of the interrogative.

In the 7 clinical sections, the concepts are simply and briefly expressed, with the inclusion of some of the latest concepts and techniques. The book addresses many issues that probably do not bother MR physicists but may occasionally stump the radiologist, such as why the apparent diffusion coefficient is a rotationally variant measure or how the PROPELLER acquisition samples K-space or the basis for giving twice the amount of contrast material when using spin-echo perfusion imaging compared with gradient-echo perfusion imaging. There are other abundant examples like this throughout the book. For those who wish to delve more deeply into the basics of these techniques, the references will be of assistance.

The bulk of the book (the last 3 quarters) is devoted to applying the lessons learned in the first quarter of the book to various diseases. The imaging of stroke is treated in a complete manner; it is interesting that the last chapter in this section concerns the imaging of migraines, showing among other parameters, magnetoencephalography, fMR, magnesium maps, and alterations in *n*-acetyl aspartate during visual stimulation.

In the relatively short adult neoplasia section, equal attention and space is given to MR spectroscopy, diffusion, and perfusion. Spectroscopy naturally deals with single voxel, multivoxel, and spectroscopic imaging; for details on MR spectroscopy, the reader will have to refer to the first section of the book. This very basic chapter is written primarily to give the clinical neurologist a flavor of the potential value of MR spectroscopy. Although brevity is important, this reviewer feels that the neoplasm chapter overdoes brevity and the reader is left with "bare bones" MR spectroscopy. As a result, some of the case study examples are not explained in the depth they should have been. For example, the 72 multivoxel MR spectroscopy in a case of GBM does not have the various peaks explained. The chapters on diffusion and perfusion in tumors do have more in-depth material than the spectroscopy chapter.

The section on infection, inflammation, and demyelination follows the same pattern of overview (Dr. Zimmerman's contribution is incidentally a useful overview of the subject), and MR spectroscopy/diffusion-weighted imaging (separately for infection and inflammation). In the MR spectroscopy chapter in cranial infection, the authors should have paid closer attention to the legends. For example, they describe a herpes infection extending into the "frontal region" when clearly the extension is into the



occipital region. Better descriptions in the legends of the pulse sequences used in every MR spectroscopy would have added significantly to the descriptive material. Good clinical examples including wide ranging pathology are presented. There is a nice final chapter by Drs. Chang and Ernest (both of whom are well-known investigators in HIV) on physiologic MR to evaluate HIV-associated disorders. The remaining chapters on seizures, psychiatric and neurodegenerative disorders, and trauma are basically surveys of these fields. The chapter on pediatrics, however, is more extensive (156 pages), informative, and useful than the preceding 3 chapters. Here Drs. Melham and Gotay present a nice survey of physiologic MR of the pediatric brain.

Overall, the book is highly readable and the image quality is good throughout, though a few images are unnecessarily dark. There are advanced techniques that are not included in this book, such as fMR (cortical activation), time-resolved MR angiography, and CSF flow studies, but of course it was the author's intent to concentrate just on the application of MR spectroscopy, diffusion, and perfusion in brain MR imaging. Perhaps future editions will include these newer areas of MR interest.

The book is recommended as an excellent description of advanced techniques in clinical settings and will be useful to all practicing neuroradiologists.

BOOK REVIEW

Nuclear Medicine in Clinical Diagnosis and Treatment, 3rd ed

Peter J. Ell and Sanjid Sam Gambhir, eds. 3rd ed., 2 vols. Churchill Livingstone; 2004, 1950 pages, 1761 illustrations, \$399.

This is a comprehensive 2-volume text on nuclear medicine. The third edition of this well-known reference work has almost 2000 pages. I.P.C. Murray and P.J. Ell edited the 2 previous editions of the book, and now P.J. Ell and S.S. Gambhir have edited this new edition.

Preface and Stated Goals: In the preface, Ell and Gambhir refer to the "increasing role of nuclear medicine in the investigation and management of cancer patients" and "the increasing role of small animal imaging instrumentation" and define this period of nuclear medicine "as the most exciting times ever for the field." Therefore, this edition gives particular attention to fluorodeoxyglucose positron-emission tomography (PET), PET-CT, and molecular imaging and the investigation of the central nervous system (CNS). For readers of the *AJNR*, these 3 fields are of significant interest, particularly the specific investigation of the CNS. The editors comment about the new atlas section of the book, which includes a brain atlas, and about the basic sciences section. The latter maintains a question-and-answer format and now includes special topics: cell biology and molecular imaging fundamentals, optical imaging technology, and statistical issues, such as clinical decision making and decision analysis fundamentals. They conclude their preface by referring to the authors and section editors as leaders in the field of nuclear medicine from around the world. They dedicate their book to "a new gener-

ation of clinical physicians and basic scientists" and express the hope that "this book will help us to better understand the past, simplify the present, and provide some insights into the potential future of nuclear medicine." In reviewing the book, we see that they have indeed pursued, and in many aspects they have achieved, their goals.

Esthetics: The 2 volumes are eye-catching and appropriately sized. The paper is of high quality and the typefaces are clear and attractive. Color is used well to define the different chapters of the book and even the individual pages. The images of the cases presented are mostly representative and are of high teaching value. The book is divided into 8 clinical sections, and each exploring a different aspect of nuclear medicine: (1) tumor diagnosis and therapy, (2) disorders of the bones and joints, (3) gastrointestinal function, (4) acute care, (5) nuclear cardiology, (6) neurology and psychiatry, (7) renal disorders, and (8) basic sciences. The sections are subdivided into a total of 133 chapters.

Index, Contents, Contributors, Foreword, and Preface: Each volume includes a complete and comprehensive index, as well as the table of contents, names of the contributors, foreword, and preface. The complete 80 pages are printed in each volume.

The Contributors: There are 236 contributors to this book, 54 of whom are from the United States. Each section or part has an advisory editor, and 10 of them are from the United States. As the authors state in their preface, this is an international book, reflecting the views of nuclear medicine people throughout the world. This book offers the best aspects of clinical nuclear medicine because it is the product of the experience and enthusiasm of the dedicated international contributors. On the other hand, the contributors are specialists who try to write optimistically and comprehensively on their topics, even if the method is sometimes nearly obsolete—for example, the discussion on Myoscint. In addition, the use of many educated specialists and a fractionated presentation of many topics has resulted in many avoidable redundancies. In general, despite the fact that there are section editors for the book, the overall impression underscores the autonomy of the contributors who helped produce this book.

Development of Nuclear Medicine, History, and Trends: Reading this book was a wonderful journey through the years and knowledge of the emergence of modern nuclear medicine. The contemporary practice of nuclear medicine is also well reviewed. There are many new topics, of current and great clinical significance or related to vital research activities that this book reviews, some discussed exhaustively and others briefly. This book is primarily directed to the nuclear specialist, practitioner, or researcher who has particular interest in nuclear medicine and wants to know more, before he or she digs into the vast literature on the topic.

General Remarks: For some, who have limited interest in nuclear medicine, the material may appear too much, and the 2 volumes may be cumbersome and difficult to handle. Others, however, will find the book quite informative, well referenced, and, though opinionated here and there because of some particular experience of the contributor, will consider this as a good reference book. There will also be some readers who may know certain topics better than the contributors and might find the coverage of some issues inadequate; for others,