



Discover Generics

Cost-Effective CT & MRI Contrast Agents



WATCH VIDEO

AJNR

This information is current as of June 26, 2025.

Effects of Carotid or Vertebrobasilar Stent Placement on Cerebral Perfusion and Cognition

Roham Moftakhar, Aquilla S. Turk, David B. Niemann, Sayed Hussain, Sharad Rajpal, Thomas Cook, Madeleine Geraghty, Beverly Aagaard-Kienitz, Patrick A. Turski and George C. Newman

AJNR Am J Neuroradiol 2005, 26 (7) 1772-1780
<http://www.ajnr.org/content/26/7/1772>

Effects of Carotid or Vertebrobasilar Stent Placement on Cerebral Perfusion and Cognition

Roham Moftakhar, Aquilla S. Turk, David B. Niemann, Sayed Hussain, Sharad Rajpal, Thomas Cook, Madeleine Geraghty, Beverly Aagaard-Kienitz, Patrick A. Turski, and George C. Newman

INTRODUCTION: There are no well-established physiologic or neuropsychological criteria for identifying which patients with stenosis of the cervicocerebral vessels are at high risk of stroke or cognitive impairment. Our purpose was to evaluate changes in cognitive performance and cerebral perfusion associated with endovascular stent placement of the cervicocerebral vessels.

METHODS: A consecutive series of 20 patients, 31–88 years of age, who underwent 21 stent procedures for arterial stenosis (10 extracranial carotid stents [ECS], four intracranial carotid stents [ICS], and seven extra- or intracranial vertebrobasilar stents [VBS]) was investigated retrospectively. All patients were evaluated with CT or MR perfusion studies both before and after stent placement. Cognitive response after stent placement was evaluated by using an informant questionnaire.

RESULTS: In patients with anterior circulation stenoses (ECS and ICS group), 11 of 14 (79%) had a baseline perfusion abnormality and all 11 patients showed improved perfusion after stent placement. Four of seven (57%) patients with posterior circulation stenoses (VBS group) had a baseline perfusion abnormality and two of the four patients showed improved perfusion after stent placement. Degree of stenosis was the strongest predictor of the presence of a baseline perfusion abnormality ($P = .03$). Fifteen of 19 (79%) of the patients showed improved cognitive scores after stent placement. Among patients with improvement in perfusion after stent placement, 11 of 13 (85%) had improved cognitive scores. Improved perfusion after stent placement was a significant predictor of cognitive improvement ($P = .04$). Patients who were stented on an elective basis demonstrated greater improvement in cognition as compared with patients stented urgently ($P = .01$).

CONCLUSION: Endovascular stent placement of the cervicocerebral vessels can safely and effectively resolve cerebral perfusion abnormalities. Improvement in perfusion parameters is associated with cognitive improvement. Larger, blinded, prospective studies are needed to confirm these preliminary observations.

Atherosclerosis of the cervicocerebral vessels is responsible for a large proportion of strokes. Although extracranial carotid occlusive disease is responsible for 25% of the 750,000 yearly strokes in the United States, as much as 10% of the stroke population harbor significant intracranial carotid artery stenosis

(1, 2). Studies of patients with extracranial internal carotid artery stenosis undergoing carotid endarterectomy (CEA) have shown impaired preoperative neuropsychological performance (3–6). These studies have also shown that restoration of blood flow after endarterectomy correlated with cognitive improvement. Although there has been increasing adoption of endovascular stent placement of the cervicocerebral vessels as a less-invasive alternative to open surgery, the benefit of these new techniques in relation to cerebral perfusion and cognition has not been documented.

In the past several years stent placement of the cervicocerebral vessels has emerged as a less-invasive therapeutic alternative to CEA and extracranial/intracranial (ECIC) artery bypass in patients with significant intracranial stenosis. The safety of extracra-

Received November 14, 2004; accepted after revision January 26, 2005.

From the Departments of Radiology (A.S.T., D.B.N., B.A.-K., P.A.T., G.C.N.), Neurosurgery (R.M., A.S.T., D.B.N., S.R., B.A.-K., P.A.T., G.C.N.), Neurology (S.H., M.G., G.C.N.), and Biostatistics (T.C.), University of Wisconsin Hospital and Clinics, Madison, WI.

Address correspondence to Aquilla S. Turk, DO, 600 Highland Ave., CSC E3/372, Madison, WI 53792.

© American Society of Neuroradiology

TABLE 1: Cases of stents placed for extracranial carotid stenoses

Patient Number	Age (years)	Side of Stenosis	Stenotic Vessel	Urgent/ Elective	Etiology of Vessel Stenosis	% Vessel Stenosis	Prestent Perfusion	Poststent Perfusion	Cognitive Score	Time of Imaging F/U (days)	Time of Clinical F/U (month)	Presence of Acom	No. of Pcom(s)	Functional COW
1	84	R	ICA	E	A	65	Yes	2	7	70	14	—	0	N
2	66	L	ICA	E	A	80	No	ND	6	4	3	—	2	Y
3	83	R	ICA	E	A	>90	Yes	2	9	1	3	—	2	Y
4	88	R	ICA	U	A	>90	Yes	2	—8	0	5	—	1	N
5A	83	L	ICA	E	A	70	No	ND	6	51	5	—	0	N
5B	83	R	ICA	E	A	70	No	ND	6	47	5	—	0	N
6	63	R	ICA	E	A	90	Yes	2	32	90	9	+	0	Y
7	63	R	ICA	E	A	75	Yes	2	32	0	12	+	1	Y
8	62	R	ECA	E	A	>90	Yes	1	21	0	5	—	2	Y
9	31	L	ICA	U	D	>90	Yes	2	8	1	6	+	0	Y

Note.—Cases of stents placed for extracranial carotid stenoses according to etiology of the stenoses (A indicates atherosclerosis; D, dissection); whether the stent was placed urgently (U) or electively (E); whether the case had prestent perfusion abnormality on imaging; whether the poststent perfusion abnormality normalized (2), improved (1), or did not change (0) (ND indicates patients who did not have prestent perfusion abnormality). The circle of Willis (COW) anatomy in each case is indicated by the presence or absence of anterior communicating artery (Acom) and the number of posterior communicating arteries (Pcom). The presence of a functional COW means that there is either a competent Acom or presence of a Pcom ipsilateral to the stenosis. Time of imaging follow-up is the number of days from the procedure that the follow-up perfusion imaging was performed. Time of clinical follow-up is the number of months from the procedure that the IQ-CODE was administered. L indicates left; R, right; ICA, internal carotid artery; ECA, external carotid artery.

nial internal carotid artery stent placement has been demonstrated and carotid stents have recently received US Food and Drug Administration approval for use in high-risk patients (7–11). Several randomized clinical trials are in progress to compare the efficacy of extracranial carotid stent placement to CEA (12–17). The preliminary results of these studies have demonstrated comparable or lower 30-day and 1-year event rate of stroke, heart attack, or death in patients who have undergone extracranial internal carotid stent placement as compared with CEA.

Advancements in technology, such as more flexible coronary stents, have made treatment of intracranial stenosis more feasible. Several small, uncontrolled case series have demonstrated the safety and efficacy of intracranial stent placement (18–23). The SSYL-VIA trial, the first prospective clinical study to evaluate stents for intracranial stenosis, has shown promising preliminary data (24). Compared with the natural history, the 30-day and 1-year stroke rates appear encouraging.

The first goal of this retrospective study was to evaluate whether stent placement improves cerebral perfusion abnormalities in patients with a related significant stenosis. The second aim was to determine whether patients experienced improved cognition following endovascular stent placement. Finally, we hoped to determine whether there was a correlation between improved cerebral perfusion and enhanced cognitive function.

Materials and Methods

Subjects

All procedures were performed according to institutional review board–approved guidelines. Between August 2003 and May 2004, 20 patients (21 procedures), 31–88 years of age, with a diameter stenosis of $\geq 65\%$ of a major cervicocerebral vessel,

underwent stent placement. All patients were referred for stent consideration because of ongoing neurologic symptoms in the related vascular region, despite maximal medical therapy. The patient population included nine patients with 10 extracranial carotid stenoses (Table 1), four patients with intracranial carotid stenosis (Table 2), and seven with either extra- or intracranial vertebrobasilar stenoses (Table 3). Six patients (4, 7, 9, 10, 13, and 19) had radiographic evidence of small acute or subacute infarctions at presentation. All of the infarction sizes were <2 cm or involved <2 cm of cortex as determined by CT or MR imaging. Of the 21 stents placed, 17 were elective and four were urgent (within 4 hours of patient presentation) because of patient symptomatology. All stenoses were atherosclerotic except for one, because of progressive carotid dissection.

Perfusion Imaging Acquisition and Analysis

Routine preprocedure stroke workup in all cases was performed with comprehensive head and cervical neurovascular MR or CT protocols, including MR angiography (MRA) and MR perfusion (MRP) and/or CT angiography (CTA) and CT perfusion (CTP). Poststent follow-up examinations were obtained at time points ranging from 4 hours to 3 months, by using the same imaging technique (CT, CTA, CTP or MR, MRA, MRP; Tables 1–3). Patient 15 did not have follow-up perfusion imaging after stent placement because of a progressive worsening of renal function; however, because the patient did not have baseline perfusion abnormality before stent placement, poststent perfusion imaging was not felt to be clinically necessary.

MR studies were performed on a standard 1.5T magnet (GE Medical Systems, Milwaukee, WI; 11.0 software platform). Standard clinical imaging sequences included sagittal T1, axial T2, axial diffusion-weighted images ($B = 1000$) with apparent diffusion coefficient maps, axial T2*, 3D time of flight (3D TOF) MRA at the circle of Willis, two-dimensional (2D) TOF cervical carotid arteries, dynamic contrast enhanced elliptic-centric MRA of the aortic arch through the circle of Willis, dynamic contrast bolus perfusion, followed by postcontrast axial T1 and coronal T2 fluid-attenuated inversion recovery brain images. Perfusion was acquired dynamically as a single-dose gadolinium T2* series covering 20–24 5–7-mm sections of brain. Parameter maps were calculated off-line on a commercially available system (GE Advantage Windows [AW] Work-

TABLE 2: Cases of stents placed for intracranial carotid stenoses

Patient Number	Age	Side of Stenosis	Stenotic Vessel	Urgent/ Elective	Etiology of Vessel Stenosis	% Vessel Stenosis	Pre-stent Perfusion	Post-stent Perfusion	Cognitive Score	Time of Imaging F/U (days)	Time of Clinical F/U (month)	Presence of Acom	No. of Pcom(s)	Functional COW
10	68	R	ICA	E	A	>85	Yes	2	9	9	4	—	1	N
11	69	L	ICA	E	A	>80	Yes	1	1	0	4	+	1	Y
12	58	R	ICA	E	A	70	Yes	2	27	25	7	—	2	Y
13	66	L	ICA	E	A	75	Yes	1	16	2	9	+	0	Y

Note.—Cases of stents placed for intracranial carotid stenoses according to etiology of the stenoses (A indicates atherosclerosis; D, dissection); whether the stent was placed urgently (U) or electively (E); whether the case had pre-stent perfusion abnormality on imaging; whether the post-stent perfusion abnormality normalized (2), improved (1), or did not change (0). The circle of Willis (COW) anatomy in each case is indicated by the presence or absence of anterior communicating artery (Acom) and number of posterior communicating arteries (Pcom). The presence of a functional COW means that there is either a competent Acom or presence of a Pcom ipsilateral to the stenosis. Time of imaging follow-up is the number of days from the procedure that the follow-up perfusion imaging was performed. Time of clinical follow-up is the number of months from the procedure that the IQ-CODE was administered. L indicates left; R, right; ICA, internal carotid artery.

TABLE 3: Cases of stents placed for vertebrobasilar stenoses

Patient Number	Age	Side of Stenosis	Stenotic Vessel	Urgent/ Elective	Etiology of Vessel Stenosis	% Vessel Stenosis	Pre-stent Perfusion	Post-stent Perfusion	Cognitive Score	Time of Imaging F/U (days)	Time of Clinical F/U (month)	Presence of Acom	No. of Pcom(s)	Functional COW
14	79	R	V	E	A	>85	Yes	1	21	0	3	—	0	N
15	66	L	V	E	A	70	No	ND	3	NA	6	+	1	Y
16	62	L	V	E	A	70	No	ND	0	30	5	—	1	Y
17	51	R	VB	U	A	80	Yes	2	LFU	6	LFU	—	0	N
18	69	R	VB	E	A	80	Yes	0	3	4	10	+	0	N
19	56	M	B	U	A	80	Yes	0	−3	1	3	—	2	Y
20	70	M	B	E	A	>75	No	ND	−1	21	4	—	2	Y

Note.—Cases of stents placed for vertebrobasilar stenoses according to etiology of the stenoses (A indicates atherosclerosis; D, dissection); whether the stent was placed urgently (U) or electively (E); whether the case had pre-stent perfusion abnormality on imaging; whether the post-stent perfusion abnormality normalized (2), improved (1), or did not change (0) (ND indicates patients who did not have pre-stent perfusion abnormality). The circle of Willis (COW) anatomy in each case is indicated by the presence or absence of anterior communicating artery (Acom) and the number of posterior communicating arteries (Pcom). The presence of a functional COW means that there is at least one Pcom. Time of imaging follow-up is the number of days from the procedure that the follow-up perfusion imaging was performed (NA indicates case number 15 did not have follow-up imaging). Time of clinical follow up is the number of months from the procedure that the IQ-CODE was administered. L indicates left; R, right; M, midline; V, vertebral; VB, vertebrobasilar junction; LFU, lost to follow-up.

station, version 4.2 by using Functool software, Milwaukee, WI), and maps were also automatically generated at the scanning console by using in-house software utilizing arterial deconvolution to calculate cerebral blood flow (CBF), cerebral blood volume (CBV), and mean transit time (MTT) maps according to previously published methods (25).

CT scans were also performed by using commercially available eight- or 16-section scanners (GE). Perfusion parameter maps were prepared on a GE AW Workstation using version 4.2 Perfusion 3 software. A routine head CT was performed with contiguous 5-mm axial images before and after the CTA/CTP. CTA of the head and neck was performed with a 120-mL timed bolus injection and a minimum section thickness of 1.25 mm spanning from the aortic arch to the top of the head. Thick-slab multiplanar CTA reformations and 3D reconstructions were built from this data set. CT perfusion images were then acquired by using a dynamic 40-mL intravenous contrast bolus, scanning a 2-cm region of the brain for 40–45 seconds (Fig 1). Perfusion coverage was adjusted according to vascular territory of interest, with carotid-directed examinations centered at the level of the top of the ventricles, and vertebrobasilar coverage centered to include the upper posterior fossa and lower occipital region.

For the purposes of this study, routine clinically acquired CT or MR perfusion scans were analyzed by an independent senior neuroradiologist, blinded to the clinical condition, at a later time on a PACS workstation. The examiner addressed the

following questions in this order: (1) Does a perfusion abnormality exist on the pre-stent study? (2) If a perfusion abnormality exists, does it correspond to the vascular distribution of the stenotic vessel? (3) In cases demonstrating pre-stent perfusion abnormality, does the post-stent study show decline (assigned “−1”), no change (assigned “0”), improvement (assigned “1”) or normalization (assigned “2”) of perfusion? All three questions were answered by qualitative analysis of the MTT, CBV, and CBF maps displayed in standard color rainbow scale. A mean score for change in perfusion after stent placement was calculated for the anterior (ECS and ICS) and posterior circulation.

Angiographic Procedure and Analysis

The presence of carotid or vertebrobasilar stenosis was evaluated and characterized by utilizing the patients' initial CTA or MRA, which allowed preoperative planning and risk stratification before conventional angiography. Quantitative angiographic measurements of the stenotic vessels were taken from the conventional angiograms before and after stent placement, according to methods described by the North American Symptomatic Carotid Endarterectomy Trial (NASCET) for cervical carotid lesions and WASID criteria for intracranial lesions (26, 27).

All patients were pretreated with clopidogrel (Plavix) and aspirin if they were not already taking these medications. All

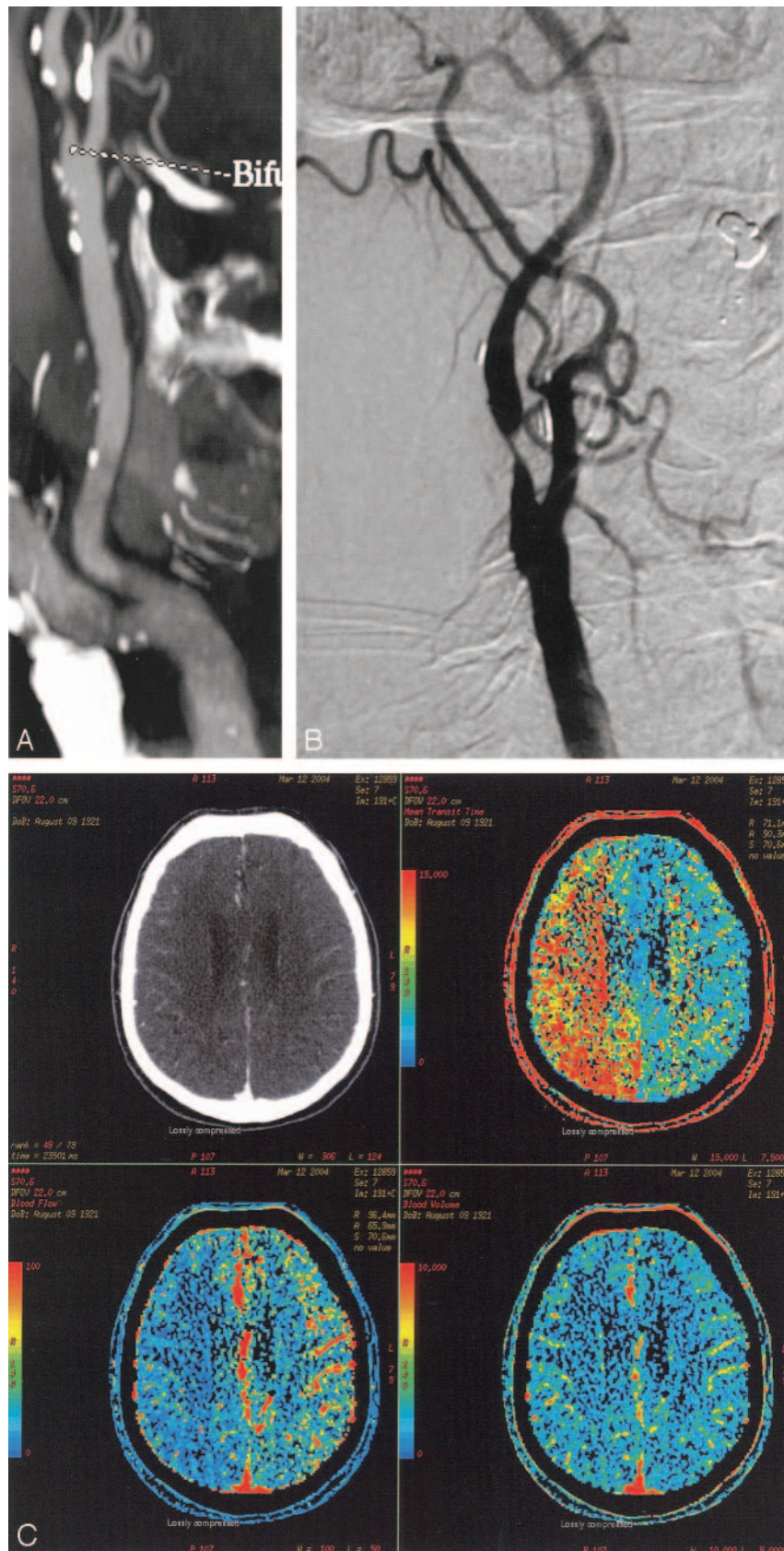


FIG 1. Sample patient with cervical internal carotid artery stenosis.

A, CTA 2D reformation showing the innominate, right common, and internal carotid arteries with a significant stenosis in the proximal ICA.

B, DSA showing right ICA stenosis.

C, Prestent CT perfusion demonstrating abnormal prolongation of mean transit time (MTT; upper right), decreased cerebral blood flow (CBF; lower left), and normal cerebral blood volume (CBV; bottom right).

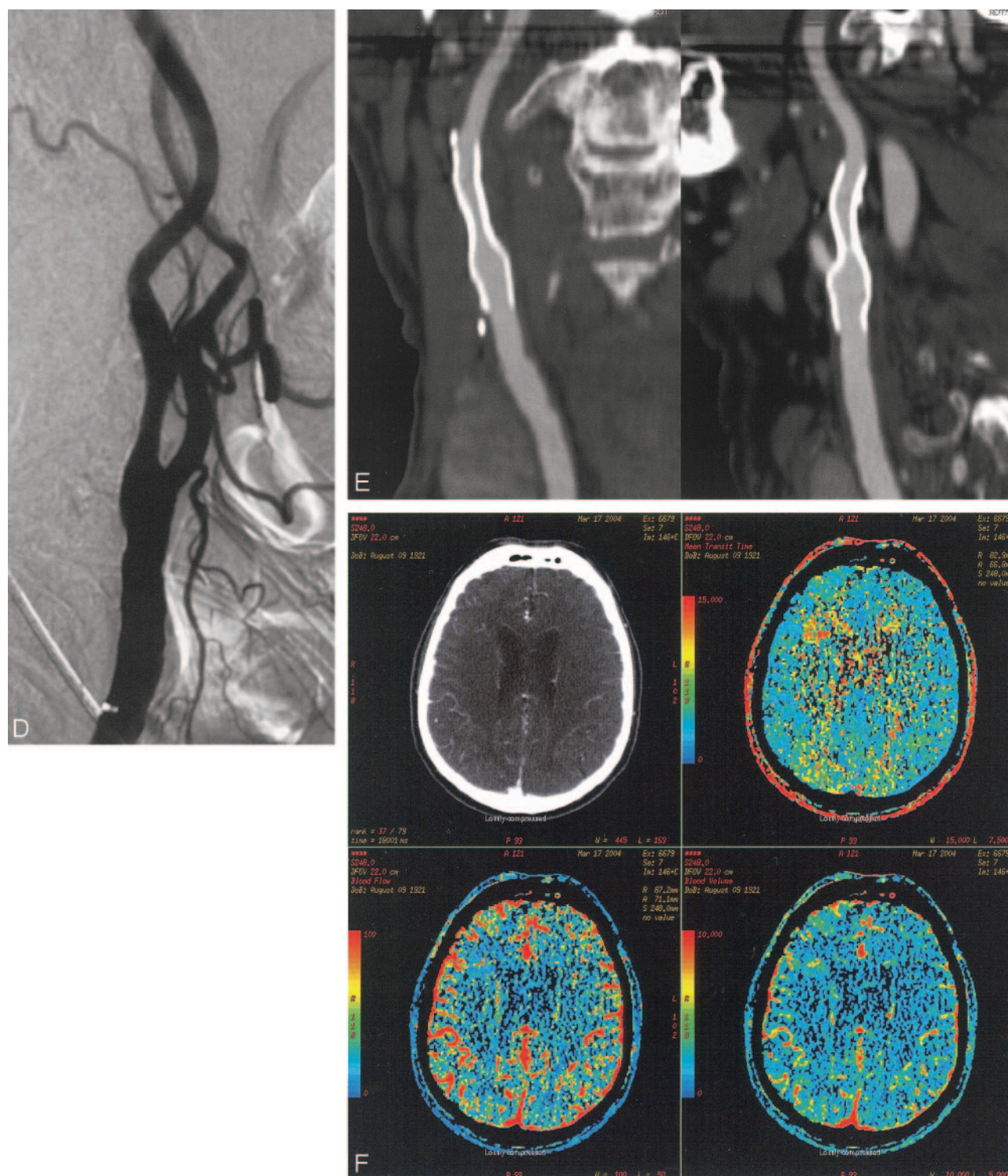


FIG 1. Continued.

D, DSA after stent placement.

E, CTA 2D multiplanar reformation with orthogonal projections through the stent.

F, CT perfusion after stent placement demonstrates normalization of MTT (upper right), CBF (bottom left), and CBV (bottom right).

cervical carotid stenoses were treated with self-expanding stents (Precise, Cordis Corp., Miami, FL). All intracranial stenoses were treated with balloon expandable coronary stents (Driver, Medtronic Corp., Minneapolis MN; or BX Velocity, Cordis). Attempts were made to primarily stent all lesions with the stent size that most closely approximated the vessel without oversizing for balloon expandable stents and oversizing by 1–2

mm for self-expanding stents. Those stenoses where a stent would not primarily traverse the lesion were predilated with a 2.5- or 3-mm-diameter balloon (Maverick, Boston Scientific, Fremont CA), to allow passage of the stent. All intracranial stents were deployed with balloon inflation to nominal pressure. If necessary, angioplasty was performed after stent placement to achieve a 20% or less residual diameter stenosis.

The presence of circle of Willis collateral pathways was determined according to Hartkamp et al by analysis of the angiogram, CTA or MRA, and assigned separate scores for the anterior and posterior pathways (28). The anterior circle of Willis was considered intact if both proximal anterior cerebral artery segments were present together with an anterior communicating artery (Acom) or incomplete if any of these elements were missing (Tables 1–3). The configuration of posterior communicating arteries (Pcom) was also determined along with the side relative to the stenosis. In the ECS and ICS, the circle of Willis was labeled as “functional” if there was a competent Acom or a Pcom ipsilateral to the stenosis. For the VBS group, the circle of Willis was labeled as “functional” if at least one Pcom was present. The presence of a contributing contralateral vertebral artery was evaluated in patients with vertebral stenosis.

Clinical Data and Analysis

Demographic and clinical data of the patients in the study population were obtained by chart review. Changes in cognition were assessed by phone interview performed by a physician blinded to clinical data by using the Informant Questionnaire on the Cognitive Decline in the Elderly (IQ-CODE), which has been validated in prior studies (29–31). The IQCODE has been shown to correlate with the Mini-Mental State examination as well as a test of episodic memory performance (32, 33). This questionnaire consists of 16 questions assessing the patients’ memory, calculation skills, and decision-making capacity on a daily basis. One investigator performed all the cognitive evaluations. Patients were contacted by telephone, and verbal consent was obtained over the phone before conducting the interview. The questions were posed to a close contact (spouse or next of kin) who had an opportunity to observe the patient on a daily basis and was able to compare the patient’s performance before and after stent placement. In the event of a close contact not being available, the patient’s own response to the questionnaire was recorded. Each of 16 questions were graded +2 (much improved), +1 (slightly improved), 0 (no change), –1 (slight decline), or –2 (marked decline). Individual scores were tallied for each patient. The scale thus ranged from +32 for maximal improvement to –32 for maximal decline in cognition. All 20 patients had cognitive evaluation except patient 17, who was lost to follow-up (Tables 1–3).

Statistical Analysis

Associations between the presence of a preperfusion deficit and other baseline variables were assessed by using logistic regression. Predictors of the degree of postperfusion improvement and cognitive changes were assessed by using ordinary least squares. Differences in percent stenosis and cognitive change between groups were assessed by using the Wilcoxon rank-sum test.

Results

Patients

The mean age for the 20 patients was 67 years, with a range of 31–88 years. The mean age for the ECS group was 69 years and for the ICS and VBS group was 65 years. The patients included 19 men and one woman. Four of the 20 patients were actively symptomatic and treated urgently. Two of the patients treated urgently had extracranial carotid stenoses and two had vertebrobasilar stenoses (Tables 1 and 2). Of the four patients treated urgently, three had atherosclerotic-related stenosis and one a progressive dis-

section. Six patients had radiographic evidence of small acute or subacute infarctions at presentation.

Imaging

Examination of the initial perfusion studies demonstrated that pre-stent perfusion abnormalities were present in 15 of 20 (75%) patients. Analysis of the pre-stent perfusion studies by specific vascular category showed that seven of nine (78%) patients in the ECS group, four of four patients in the ICS group, and four of seven (57%) patients in the VBS group had pre-stent perfusion abnormalities (Tables 1–3). The pre-stent perfusion abnormality in all cases (15/15) corresponded to the territory of the stenotic vessel that was stented.

The mean post-stent perfusion imaging follow-up was 18 days, range 0 (4 hours after stent procedure) to 90 days. Perfusion abnormalities improved or normalized in 13 of 15 (87%) patients and did not change in the other two patients. No patient had worsening in perfusion after stent placement. The post-stent perfusion analysis was broken down by vascular categories. In the anterior circulation (ECS and ICS groups), all 11 patients with baseline perfusion abnormality had improvement or normalization of perfusion (Tables 1 and 2). In the posterior circulation (VBS) group, of the four patients with baseline perfusion abnormality two improved or normalized after stent placement (Table 3). Patients with anterior circulation stenosis demonstrated a greater degree of perfusion improvement after stent placement compared with patients with the posterior circulation stenosis ($P = .02$).

Nine of the 20 patients have had additional late perfusion imaging follow-up. The mean imaging follow-up has been 5 months (range, 1.5–8.5 months). None of these patients has developed a new perfusion abnormality in the vascular territory that was stented. In fact, two patients have had further improvement in their prior existing perfusion abnormality.

The results of the circle of Willis collateral pathways are summarized for each vascular category in Tables 1–3. Note that of the five patients who did not have pre-stent perfusion abnormality, four had a functional circle of Willis and one (patient 5) had bilateral extracranial carotid stenoses when the pre-stent perfusion imaging was acquired.

The degree of vessel stenosis was $>65\%$ in all subjects and was $>90\%$ in four patients in the ECS group (mean stenosis, 79%). Patients with pre-stent perfusion abnormalities had more severe stenoses on average (81.7%) than patients without a baseline perfusion abnormality (73%; $P = .03$).

Stent-related complications were infrequent and are in keeping with other reported series. One patient had a basilar restenosis at 1 month and one patient had a vertebral origin restenosis at 3 months. Both of these lesions were treated successfully by balloon angioplasty with resolution of symptoms. Patient 11 experienced a seizure due to reperfusion 1 week after right carotid siphon stent placement. None of the patients experienced a procedure-related stroke.

Clinical and Cognitive Outcomes

Follow-up with IQ-CODE questionnaire was performed between 3 and 14 months, with a mean of 6 months. Of the 20 patients, 19 had cognitive clinical follow-up and one (patient 17) was lost to follow-up. Five patients, all of whom lived independently, self-reported the IQ-CODE questionnaire due to unavailability of a close contact.

Fifteen of the 19 patients (79%) had positive cognitive scores (mean, +9.9; range, -8 to 32) after stent placement. Of the remaining four patients, one had no cognitive change (score, 0), and three had negative cognitive scores. The patient with a -8 cognitive score was treated emergently after failed surgery and had hemorrhagic conversion of an acute infarction. Among the anterior circulation patients 12 of 13 (92%) had positive cognitive improvements as compared with three of six patients (one lost to follow-up) in the posterior circulation. The mean improvement in cognitive scores was significantly higher (+12.8) in the anterior circulation as compared with the posterior circulation (+3.8; $P = .05$).

The relationship of perfusion improvement to cognitive scores was then examined. Improvement of perfusion after stent placement was a significant predictor of cognitive improvement ($P = .04$). Of the 13 patients whose perfusion improved or normalized after stent placement, 11 (85%) had a positive cognitive score, one had a negative score, and one was lost to follow-up (mean cognitive score, +13.5; range -8 to 32). Cognitive scores were then further analyzed in terms of not only perfusion, but also the vascular territory involved. Among patients who had improved or normalized perfusion after stent placement, 10 of 11 (91%) patients in the anterior circulation had positive cognitive scores (mean cognitive score, +14; range, -8 to 32; Tables 1 and 2). In the posterior circulation, one of two patients had a positive cognitive score, and one was lost to follow-up (Table 3).

Among the patients stented on an elective basis, 15 of 16 (94%) had positive cognitive score after stent placement. Of the four patients stented urgently, one had positive cognitive score, two had negative cognitive score, and one was lost to follow-up. Patients stented on an elective basis had significantly greater cognitive improvement (mean cognitive score, +12; range, -1 to 32) as compared with patients stented urgently (mean cognitive score, -1; range, -8 to 8; $P = .01$).

Discussion

High-grade stenosis of the cervicocerebral vasculature is a known risk factor for stroke (34); however, not all patients harboring stenosis will develop overt symptoms preceding a major stroke. Considerable controversy exists over the treatment of asymptomatic stenoses of the cervicocerebral vasculature (27, 35). There are many clinical factors and anatomic features that are used to stratify patients' risk for stroke. Currently, however, there are no objective physiologic, imaging, or neuropsychological criteria for identifying

which patients with cervicocerebral stenosis are at high risk for stroke.

NASCET and ECST have shown the benefit of surgical revascularization in patients with cervical carotid stenosis (26, 36). Although renewed interest in surgical bypass has recently developed, to date no studies have shown a clear advantage of medical therapy over surgical bypass for patients with intracranial stenosis (27, 37). Cervical internal carotid artery stent placement has been shown to have a low complication rate, but long-term outcomes are not known (38-40). Although endovascular therapy is an evolving technology with limited long-term data, it does show promise in patients with high risk of stroke related to intracranial stenosis (24).

This study suggests that many patients with significant cervicocerebral stenosis demonstrate perfusion abnormalities at initial presentation that are improved after stent placement. We noted the degree of perfusion improvement was greater after anterior circulation stent placement than posterior circulation. In the anterior circulation, all patients had improvement of perfusion abnormalities after stent placement, whereas in the posterior circulation half of the patients had improvement of perfusion. One explanation for the lesser degree of perfusion improvement in the posterior circulation could be the qualitative limitations of CT and MR perfusion imaging used in this study for evaluating posterior circulation anatomy. Our studies were qualitatively evaluated because of difficulty obtaining reproducible quantitative information from the CTP data sets, which has been recently reported (41). Other potential limitations to imaging the posterior fossa include small size of anatomic structures, T2* effects from the skull base with MRP, and limited coverage area of CTP. These theories could also explain why baseline perfusion abnormalities were not seen in 57% of the posterior circulation patients as compared with 85% of anterior circulation patients.

Hypoperfusion resulting from impairment of cerebral blood flow has been documented in patients with significant cervicocerebral stenosis (42, 43). Subsequent revascularization with carotid endarterectomy or angioplasty has been shown to improve cerebral blood flow (44-46). Studies of cerebral blood flow after stent placement, however, are limited and have used ultrasonography of large vessels to demonstrate blood-flow improvement after stent placement (47). Positron-emission tomography (PET) O₂ extraction is another means to evaluate cerebral blood flow, but the limited availability and access to PET scanners make this a difficult possibility and further emphasizes the promise of CT/MR methods. The results of this study are similar to previous reports showing improved cerebral perfusion after stent placement; however, our results are unique in that we used dynamic cerebral perfusion imaging and also included intracranial stent patients. Dynamic perfusion imaging is an increasingly available and useful technique in the initial evaluation of patients with stroke that can

be integrated with traditional vascular and parenchymal imaging tests (48–50).

Another point that this study suggests is that patients with both anterior and posterior circulation stenoses show cognitive improvement after stent placement. Furthermore, the patients in the anterior circulation group with improved perfusion after stent placement showed a stronger association with cognitive improvement. Several studies have documented the cognitive deficit of patients with cerebrovascular stenosis (5, 6, 51, 52). Others have shown the cognitive improvement of patients after carotid endarterectomy (3, 4, 53, 54). Patients undergoing extracranial-intracranial bypass surgery have also benefited cognitively by this revascularization procedure (55). Our study validates the idea that many patients with cervicocerebral stenosis have cognitive dysfunction and that anterior and posterior circulation revascularization with stent placement improves cognition. Cognitive improvement after stent placement in the posterior circulation is less clear, likely because of small patient population in this study and the relatively limited role of the posterior circulation in the higher functions tested by our questionnaire.

In this study, patients who were stented on an elective basis had greater cognitive improvement than did patients who were stented urgently. This suggests that patients who are stented urgently could show cognitive improvement; however, the improvement might be to a lesser degree as compared with patients treated on an elective basis. One explanation for lesser degree of cognitive improvement in patients who are stented urgently could be that this group of patients presented with an already poor neurologic examination from an acute infarction that could make cognitive improvement difficult.

One possibility for the lack of baseline perfusion abnormality before stent placement could be related to degree of vessel stenosis. In our study, patients with perfusion abnormality had a higher vessel stenosis (81.7%) as compared with patients without perfusion abnormality (73%; $P = .03$). Another explanation for lack of perfusion abnormality before stent placement could be presence of functional circle of Willis. Among the patients without prestent perfusion abnormality, four of five had a functional circle of Willis. Collateralization from leptomeningeal vessels or retrograde ophthalmic artery flow, which has been studied, could also account for the absence of perfusion abnormality (56). In patient 5, lack of perfusion deficit before stent placement could be explained by the fact that there were bilateral carotid stenoses, which would make the perfusion symmetrical. Also, CTP has limited volume coverage, which could miss the affected area and evaluation of the posterior fossa with MRP has T2* limitations due to the skull base.

Risk of future stroke in presence of stenosis relates to embolic and hemodynamic causes. Perfusion at rest can only show potential hemodynamic derangement and does not indicate risk from emboli. Therefore, this would be expected to be an imprecise indicator of global stroke risk, even if a perfect

measurement tool. This stresses the need for global imaging assessment including detailed vascular imaging.

This study has several limitations. Some of the cases were evaluated with CT perfusion ($n = 14$) and some with MR perfusion ($n = 7$); however, the initial and poststent perfusion imaging for 83% of the cases was the same technique. The perfusion scans were evaluated qualitatively based on color differences of a standard rainbow scale. The time to clinical and imaging follow-up was not the same for all patients. The IQ-CODE, even though clinically used for cognitive evaluation, has not been previously tested in a clinical study such as this. Also, the IQ-CODE questionnaire was administered directly to five patients because of unavailability of a close contact. Finally, this study is retrospective with a small population of patients and lacks a medically treated control group.

These observations illustrate the potential ill effects of vascular stenosis beyond the more obvious risks of hemodynamic or embolic stroke. Chronic hypoperfusion can lead to chronic cognitive dysfunction, either on a persistent or intermittent basis. The resting perfusion examinations done in our patients are limited in that they provide only a snapshot of resting flow in one position at one moment in time. Because CT and MR perfusion measurements are done with patients recumbent, this may represent optimal perfusion conditions. Intermittent periods of even more severe regional oligemia than shown in our perfusion examinations might be expected due to blood pressure fluctuations related to daily activities, assumption of upright postures, medication, hydration status, and other factors.

In conclusion, this study suggests that patients harboring cervicocerebral stenosis especially of the anterior circulation with a corresponding perfusion abnormality derive a cognitive benefit from cerebral revascularization when treated on an elective basis before a cerebrovascular event. This pilot study supports the theory that physiologic and neuropsychological criteria for identifying patients with cervicocerebral stenosis are needed so that early therapeutic intervention can be instituted before a devastating stroke occurs. Currently, there is an ongoing prospective study on this subject matter at our institution.

References

1. Stroke Outcomes and Neuroimaging of Intracranial Atherosclerosis (SDNIA) Investigators. **Stroke outcome and neuroimaging of intracranial atherosclerosis (SONIA): design of a prospective, multicenter trial of diagnostic tests.** *Neuroepidemiology* 2004;23:23–32
2. Higashida RT, Meyers PM, Phatouros CC, et al. **Reporting standards for carotid artery angioplasty and stent placement.** *J Vasc Interv Radiol* 2004;15:421–422
3. Kelly MP, Javid H. **Carotid artery disease, carotid endarterectomy, and behavior.** *Arch Neurol* 1980;37:743–748
4. King GD, Gideon DA, Haynes CD, et al. **Intellectual and personality changes associated with carotid endarterectomy.** *J Clin Psychol* 1977;33:215–220
5. Mathiesen EB, Waterloo K, Joakimsen O, et al. **Reduced neuropsychological test performance in asymptomatic carotid stenosis: the Tromsø Study.** *Neurology* 2004;62:695–701
6. Linfante I, Hirsch JA, Selim M, et al. **Safety of latest-generation self-expanding stents in patients with NASCET-ineligible severe**

- symptomatic extracranial internal carotid artery stenosis. *Arch Neurol* 2004;61:39–43
7. New G, Roubin GS, Iyer SS, et al. Safety, efficacy, and durability of carotid artery stenting for restenosis following carotid endarterectomy: a multicenter study. *J Endovasc Ther* 2000;7:345–352
 8. Rao R. The role of carotid stenosis in vascular cognitive impairment. *Eur Neurol* 2001;46:63–69
 9. Roubin GS, New G, Iyer SS, et al. Immediate and late clinical outcomes of carotid artery stenting in patients with symptomatic and asymptomatic carotid artery stenosis: a 5-year prospective analysis. *Circulation* 2001;103:532–537
 10. Yadav JS, Roubin GS, Iyer S, et al. Elective stenting of the extracranial carotid arteries. *Circulation* 1997;95:376–381
 11. Yadav JS, Wholey MH, Kuntz RE, et al. Protected carotid-artery stenting versus endarterectomy in high-risk patients. *N Engl J Med* 2004;351:1493–1501
 12. Data from the ARCHER trial shows carotid stenting for stroke prevention is safe and effective for high risk patients. *Society of Interventional Radiology* March 25, 2004 (www.sirweb.org/news/newspdf/archerfinal.pdf)
 13. ISES Steering Committee, Dietrich EBFT, Hopkins LN, Roubin G, et al. The CARESS Trial. *Endovasc Today* 2004;21–29
 14. Hobson RW 2nd. CREST (Carotid Revascularization Endarterectomy versus Stent Trial): background, design, and current status. *Semin Vasc Surg* 2000;13:139–143
 15. Hobson RW 2nd. Update on the Carotid Revascularization Endarterectomy versus Stent Trial (CREST) protocol. *J Am Coll Surg* 2002;194:S9–14
 16. Hobson RW 2nd, Brott T, Ferguson R, et al. CREST: carotid revascularization endarterectomy versus stent trial. *Cardiovasc Surg* 1997;5:457–458
 17. Yadav J. The 30-day SAPHIRE results. Presented at: American Heart Association annual meeting, Chicago, IL, November 17–20, 2002
 18. Alazzaz A, Thornton J, Aletich VA, et al. Intracranial percutaneous transluminal angioplasty for arteriosclerotic stenosis. *Arch Neurol* 2000;57:1625–1630
 19. de Rochemont Rdu M, Turowski B, Buchkremer M, et al. Recurrent symptomatic high-grade intracranial stenoses: safety and efficacy of undersized stents: initial experience. *Radiology* 2004;231:45–49
 20. Kim JK, Ahn JY, Lee BH, et al. Elective stenting for symptomatic middle cerebral artery stenosis presenting as transient ischaemic deficits or stroke attacks: short term arteriographical and clinical outcome. *J Neurol Neurosurg Psychiatry* 2004;75:847–851
 21. Lylyk P, Cohen JE, Ceratto R, et al. Angioplasty and stent placement in intracranial atherosclerotic stenoses and dissections. *AJNR Am J Neuroradiol* 2002;23:430–436
 22. Morris PP, Martin EM, Regan J, et al. Intracranial deployment of coronary stents for symptomatic atherosclerotic disease. *AJNR Am J Neuroradiol* 1999;20:1688–1694
 23. Nakahara T, Sakamoto S, Hamasaki O, et al. Stent-assisted angioplasty for intracranial atherosclerosis. *Neuroradiology* 2002;44:706–710
 24. Investigators TSS. Stenting of Symptomatic Atherosclerotic Lesions in the Vertebral or Intracranial Arteries (SSYLVA) Study Results. *Stroke* 2004;35:1388–1392
 25. Carroll TJ, Rowley HA, Houghton VM. Automatic calculation of the arterial input function for cerebral perfusion imaging with MR imaging. *Radiology* 2003;227:593–600
 26. North American Symptomatic Carotid Endarterectomy Trial Collaborators. Beneficial effect of carotid endarterectomy in symptomatic patients with high-grade carotid stenosis. North American Symptomatic Carotid Endarterectomy Trial Collaborators. *N Engl J Med* 1991;325:445–453
 27. Chimowitz MI, Kokkinos J, Strong J, et al. The Warfarin-Aspirin Symptomatic Intracranial Disease Study. *Neurology* 1995;45:1488–1493
 28. Hartkamp MJ, van Der Grond J, van Everdingen KJ, et al. Circle of Willis collateral flow investigated by magnetic resonance angiography. *Stroke* 1999;30:2671–2678
 29. Jorm AF. A short form of the Informant Questionnaire on Cognitive Decline in the Elderly (IQCODE): development and cross-validation. *Psychol Med* 1994;24:145–153
 30. Jorm AF, Jacomb PA. The Informant Questionnaire on Cognitive Decline in the Elderly (IQCODE): socio-demographic correlates, reliability, validity and some norms. *Psychol Med* 1989;19:1015–1022
 31. Jorm AF, Scott R, Cullen JS, et al. Performance of the Informant Questionnaire on Cognitive Decline in the Elderly (IQCODE) as a screening test for dementia. *Psychol Med* 1991;21:785–790
 32. Bowers J, Jorm AF, Henderson S, et al. General practitioners' detection of depression and dementia in elderly patients. *Med J Aust* 1990;153:192–196
 33. Folstein MF, Folstein SE, McHugh PR. "Mini-mental state": a practical method for grading the cognitive state of patients for the clinician. *J Psychiatr Res* 1975;12:189–198
 34. Liapis CD, Kakisis JD, Kostakis AG. Carotid stenosis: factors affecting symptomatology. *Stroke* 2001;32:2782–2786
 35. Endarterectomy for asymptomatic carotid artery stenosis. Executive Committee for the Asymptomatic Carotid Atherosclerosis Study. *JAMA* 1995;273:1421–1428
 36. European Carotid Surgery Trialists' Collaborative Group. Randomized trial of endarterectomy for recently symptomatic carotid stenosis: final results of the MRC European Carotid Surgery Trial (ECST). *Lancet* 1998;351:1379–1380
 37. EC/IC Bypass Study Group. Failure of extracranial-intracranial arterial bypass to reduce the risk of ischemic stroke: results of an international randomized trial. The EC/IC Bypass Study Group. *N Engl J Med* 1985;313:1191–1200
 38. Henry M, Amor M, Masson I, et al. Angioplasty and stenting of the extracranial carotid arteries. *J Endovasc Surg* 1998;5:293–304
 39. Mathias K, Jager H, Sahl H, et al. [Interventional treatment of arteriosclerotic carotid stenosis]. *Radiologe* 1999;39:125–134
 40. Theron JG, Payelle GG, Coskun O, et al. Carotid artery stenosis: treatment with protected balloon angioplasty and stent placement. *Radiology* 1996;201:627–636
 41. Fiorella D, Heiserman J, Prenger E, et al. Assessment of the reproducibility of postprocessing dynamic CT perfusion data. *AJNR Am J Neuroradiol* 2004;25:97–107
 42. Klijn CJ, Kappelle LJ, Tulleken CA, et al. Symptomatic carotid artery occlusion: a reappraisal of hemodynamic factors. *Stroke* 1997;28:2084–2093
 43. Powers WJ. Cerebral hemodynamics in ischemic cerebrovascular disease. *Ann Neurol* 1991;29:231–240
 44. Markus HS, Clifton A, Buckenham T, et al. Improvement in cerebral hemodynamics after carotid angioplasty. *Stroke* 1996;27:612–616
 45. Rutgers DR, Klijn CJ, Kappelle LJ, et al. Sustained bilateral hemodynamic benefit of contralateral carotid endarterectomy in patients with symptomatic internal carotid artery occlusion. *Stroke* 2001;32:728–734
 46. Visser GH, van Huffelen AC, Wieneke GH, et al. Bilateral increase in CO₂ reactivity after unilateral carotid endarterectomy. *Stroke* 1997;28:899–905
 47. Niesen WD, Rosenkranz M, Eckert B, et al. Hemodynamic changes of the cerebral circulation after stent-protected carotid angioplasty. *AJNR Am J Neuroradiol* 2004;25:1162–1167
 48. Eastwood JD, Lev MH, Wintermark M, et al. Correlation of early dynamic CT perfusion imaging with whole-brain MR diffusion and perfusion imaging in acute hemispheric stroke. *AJNR Am J Neuroradiol* 2003;24:1869–1875
 49. Latchaw RE, Yonas H, Hunter GJ, et al. Guidelines and recommendations for perfusion imaging in cerebral ischemia: a scientific statement for healthcare professionals by the writing group on perfusion imaging, from the Council on Cardiovascular Radiology of the American Heart Association. *Stroke* 2003;34:1084–1104
 50. Wintermark M, Thiran JP, Maeder P, et al. Simultaneous measurement of regional cerebral blood flow by perfusion CT and stable xenon CT: a validation study. *AJNR Am J Neuroradiol* 2001;22:905–914
 51. Hamster W, Diener HC. Neuropsychological changes associated with stenoses or occlusions of the carotid arteries: a comparative psychometric study. *Eur Arch Psychiatry Neurol Sci* 1984;234:69–73
 52. O'Brien JT, Erkinjuntti T, Reisberg B, et al. Vascular cognitive impairment. *Lancet Neurol* 2003;2:89–98
 53. Dardik A, Minor J, Watson C, et al. Improved quality of life among patients with symptomatic carotid artery disease undergoing carotid endarterectomy. *J Vasc Surg* 2001;33:329–333
 54. Hemmingsen R, Mejsholm B, Vorstrup S, et al. Carotid surgery, cognitive function, and cerebral blood flow in patients with transient ischemic attacks. *Ann Neurol* 1986;20:13–19
 55. Sasoh M, Ogasawara K, Kuroda K, et al. Effects of EC-IC bypass surgery on cognitive impairment in patients with hemodynamic cerebral ischemia. *Surg Neurol* 2003;59:455–460; discussion 460–453
 56. Smith HA, Thompson-Dobkin J, Yonas H, et al. Correlation of xenon-enhanced computed tomography-defined cerebral blood flow reactivity and collateral flow patterns. *Stroke* 1994;25:1784–1787