



Providing Choice & Value

Generic CT and MRI Contrast Agents



CONTACT REP

AJNR

This information is current as
of July 18, 2025.

Treatment of Unruptured Aneurysms with GDCs: Clinical Experience with 247 Aneurysms

Nestor Gonzalez, Yuichi Murayama, Yih Lin Nien, Neil
Martin, John Frazee, Gary Duckwiler, Reza Jahan, Y. Pierre
Gobin and Fernando Viñuela

AJNR Am J Neuroradiol 2004, 25 (4) 577-583
<http://www.ajnr.org/content/25/4/577>

Treatment of Unruptured Aneurysms with GDCs: Clinical Experience with 247 Aneurysms

Nestor Gonzalez, Yuichi Murayama, Yih Lin Nien, Neil Martin, John Frazee, Gary Duckwiler, Reza Jahan, Y. Pierre Gobin, and Fernando Viñuela

BACKGROUND AND PURPOSE: The GDC system is a valuable therapeutic alternative to surgical treatment of intracranial aneurysms. We present our clinical experience with the GDC technique used to treat unruptured cerebral aneurysms.

METHODS: This is a retrospective review of 217 patients with 247 unruptured intracranial aneurysms who underwent embolization with GDCs between August 1991 and June 2000. One hundred sixty-seven of the 217 were female patients. Patient age ranged from 13 to 83 years. In 118 patients, the aneurysms were found when unrelated non-neurologic conditions indicated angiography, CT angiography, or MR angiography (group 1). Fifty-one patients with mass effect symptoms comprised group 2, 12 patients with aneurysms associated with arteriovenous malformations or tumors of the brain comprised group 3, 17 patients with unruptured aneurysms treated during the chronic phase of subarachnoid hemorrhage (SAH) comprised group 4, and 19 patients treated during the acute phase of SAH due to another ruptured aneurysm comprised group 5.

RESULTS: Angiographic results revealed complete occlusion in 138 of 247 aneurysms (55.9%), neck remnants in 92 (37.2%), and incomplete occlusion in three (1.2%). GDC embolization was attempted unsuccessfully in 14 aneurysms (5.7%). Of the 198 patients without acute SAH (groups 1–4), 186 (93.9%) of 198 remained neurologically unchanged. Eleven of the 217 patients (5.1%) experienced neurologic deterioration caused by immediate procedural complications. One patient died (0.5%) as a result of aneurysmal rupture during embolization. For asymptomatic patients and those treated after the chronic period of SAH, the mean hospitalization stay was 2.9 days.

CONCLUSION: GDC technology constitutes safe treatment for unruptured aneurysms, with successful anatomic and clinical results and low complication rates achieved.

To date, >125,000 patients with ruptured and unruptured aneurysms have been treated worldwide with the GDC system (1). The GDC system has shown short-term clinical and angiographic efficacy as a therapeutic alternative to the surgical treatment of intracranial aneurysms (2–9). However, the long-term impact of the GDC system in preventing growth or rupture of unruptured intracranial aneurysms (UIAs) has not been proved. We herein report the results of 217 patients with 247 UIAs treated with the GDC technique, including analysis of their anatomic and

clinical outcomes according to the risk factors that have been identified in the natural history of UIAs.

Patients and Techniques

Patient Population

Two hundred seventeen patients with 247 UIAs underwent GDC embolization at the University of California, Los Angeles Medical Center between August 1991 and June 2000. One hundred sixty-seven (77%) of the 217 were female patients. Mean patient age was 54.2 years, with a range from 13 to 83 years. Age distribution was as follows: 32 patients (14.7%) were younger than 40 years, 149 (68.7%) were between 40 and 69 years, and 36 (16.6%) were older than 70 years (Table 1).

Clinical Presentation

Patients were classified into five groups. One hundred ninety-eight patients (91.2%) did not have acute SAH (groups 1–4). One hundred eighteen patients (54.4%) had UIAs discovered incidentally during angiography, CT angiography, or MR angiography for unrelated medical conditions (group 1: incidental).

Received June 2, 2002; accepted after revision August 30, 2003.
From the Divisions of Neurosurgery (N.G., N.M., J.F.) and Interventional Neuroradiology (Y.M., Y.L.N., Y.P.G., F.V.), University of California, Los Angeles Medical Center, Los Angeles, CA.

Address reprint requests to Fernando Viñuela, MD, Division of Interventional Neuroradiology, Radiology 172115, University of California, Los Angeles Medical Center, 10833 Le Conte Avenue, Los Angeles, CA 90095.

TABLE 1: Characteristics of patient population

	Number of Patients (%)
Age	
<40 yr	32 (14.7)
40–69 yr	149 (68.7)
≥70 yr	36 (16.6)
Mean	54.2 yr
Range	13–83 yr
Sex	
Female	167 (77)
Male	50 (23)
Classification	
Group 1, incidental	118 (54.4)
Group 2, mass effect	51 (23.5)
Group 3, tumor/AVM	12 (5.5)
Group 4, chronic SAH	17 (7.8)
Group 5, acute SAH	19 (8.8)
Grade I	4
Grade II	9
Grade III	5
Grade IV	1
Grade V	0
Indication for endovascular treatment	
Surgically difficult	68 (31.3)
Failed clipping	17 (7.8)
Refusal of surgery	37 (17.1)
Elderly plus poor medical condition	54 (24.9)
Information not available	41 (18.9)

Note.—AVM indicates arteriovenous malformation; SAH, subarachnoid hemorrhage.

Group 2 (mass effect) included 51 patients (23.5%) who presented with symptomatic mass effect from UIAs. The signs and symptoms in this group included headache in 18 cases, visual deterioration in 16, cranial nerve palsy/diplopia in 14, ptosis in three, vertigo in two, and eye pain in two.

Twelve (5.5%) patients had aneurysms that were discovered to be associated with tumors or arteriovenous malformations (AVMs). They comprised group 3 (tumor/AVM).

Seventeen patients (7.8%) each had multiple aneurysms and history of SAH, but the procedure had not been performed during the acute phase. They were readmitted to the hospital for treatment of the UIA after clinical recovery from initial SAH (group 4: multiple/chronic phase).

Nineteen patients with multiple aneurysms (8.8%) were treated during the acute phase of SAH due to another ruptured aneurysm (group 5: multiple/acute phase). Within group 5, four patients were classified as having Hunt and Hess grade I, nine as having grade II, five as having grade III, and one as having grade IV (Table 1).

Indication for Aneurysm Treatment

Final decisions regarding the treatment of patients with UIAs were discussed among the members of the vascular neurosurgery and interventional neuroradiology departments. The indications for GDC embolization included surgical difficulty, determined by the referring neurosurgeon or the University of California, Los Angeles neurosurgical team (68 patients), attempted surgical exploration (17 patients), refusal of surgery (37 patients), elderly patients (36 patients older than 70 years), and poor medical condition (18 patients). The information was not available for 41 patients (Table 1).

TABLE 2: Aneurysm locations

Location	Number of Aneurysms (%)
Anterior circulation	187 (76)
Paraclinoid carotid artery	95 (38.5)
Posterior communicating artery	24 (9.7)
Middle cerebral artery	22 (8.9)
Anterior communicating artery	19 (7.7)
Intracavernous/intrapetrous	14 (5.7)
Internal carotid artery bifurcation	5 (2)
Anterior choroidal	3 (1.2)
Anterior cerebral artery	3 (1.2)
Others	2 (0.8)
Posterior circulation	60 (24)
Basilar tip	36 (14.6)
Basilar trunk	15 (6.1)
Posterior inferior cerebellar artery	3 (1.2)
Posterior cerebral artery	3 (1.2)
Vertebral artery	3 (1.2)

Description of Aneurysms

Aneurysm location. One hundred eighty-seven (76%) aneurysms were located in the anterior circulation and 60 (24%) in the posterior circulation. The most common location was the paraclinoid internal carotid artery, which includes the carotid ophthalmic artery, and the superior hypophyseal artery (95 aneurysms, 38.5%). The second most frequent location was the basilar tip (14.6%), and the next most frequent were the posterior communicating artery (9.7%), middle cerebral artery (8.9%), and anterior communicating artery (7.7%). A detailed description of aneurysm location is provided in Table 2.

Aneurysm size. The aneurysm size and neck dimensions were determined by using 2D digital subtraction angiography. One hundred forty-five aneurysms (58.7%) were small (4–10 mm in largest diameter), 62 (25.1%) were large (11–25 mm), 29 (11.7%) were giant (>25 mm), and 11 (4.5%) were fusiform. The aneurysms responsible for mass effect symptoms (group 2) tended to be larger than those found in the other groups. In this group, of 56 aneurysms, 23 (41.1%) were giant aneurysms, 16 (28.6%) were large, and only 11 (19.6%) were small. The distribution of sizes in the other groups is presented in Table 3.

Neck size. Eighty-seven (35.2%) of the 347 aneurysms had small necks (<4 mm in diameter), 149 (60.3%) had wide necks (>4 mm), and 11 (4.5%) were fusiform.

GDC Embolization

The technique applied in the endovascular treatment of these UIAs is the same that has been published before (8). The procedures were performed with the patients under general anesthesia, and systemic heparinization was provided throughout. An initial dose of 3000 to 5000 U of heparin was IV administered, and repeated doses of 1000 U were administered every hour. Reversal of the heparinization with injection of protamine sulfate (10 mg/1000 U heparin) was performed in most cases, except in cases in which protrusion of the GDCs into the parent artery had occurred.

Under high resolution digital fluoroscopy and road mapping, a 1.8- or 2.1-French microcatheter was positioned in the sac of the aneurysm. The GDCs were delivered sequentially and deployed into the aneurysm until tight coil packing was achieved. The balloon-assisted technique described by Moret et al (10) was used to treat seven wide necked aneurysms during GDC deposition.

TABLE 3: Distribution of aneurysm sizes by group

Aneurysm Size Group Distribution	Group 1: Incidental		Group 2: Mass Effect		Group 3: Tumor/AVM		Group 4: Chronic SAH		Group 5: Acute SAH	
	n	%	n	%	n	%	n	%	n	%
Small/Small	46	34.6	8	14.3	2	15.4	12	54.5	16	69.6
Small/Wide	38	28.6	3	5.3	6	46.1	8	36.4	6	26.1
Large	40	30.1	16	28.6	3	23.1	2	9.1	1	4.3
Giant	6	4.5	23	41.1	0	0	0	0	0	0
Fusiform	3	2.2	6	10.7	2	15.4	0	0	0	0
Total	133	100	56	100	13	100	22	100	23	100

Note.—AVM indicates arteriovenous malformation; SAH, subarachnoid hemorrhage.

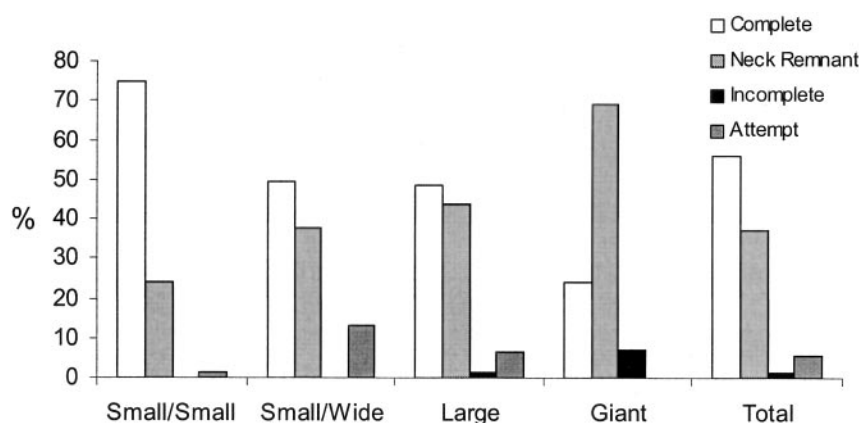


FIG 1. Histogram shows immediate anatomic outcomes among aneurysm categories.

Immediate postembolization angiography in multiple projections was performed and evaluated by the interventional neuroradiologist. Embolization was considered "complete" if no filling of contrast medium in the dome, body, or neck occurred. "Small neck remnant" was defined as residual filling of part of the neck of the aneurysm. "Incomplete" occlusion was defined as some filling of contrast medium in the dome. "Attempted" occlusion was defined as endovascular intervention that was attempted without GDC embolization being performed.

GDC embolization of UIAs was usually performed on the day of admission (day 0). After the procedure, the patients were admitted to the neuro-observation unit, where they stayed overnight. The next day, they were transferred to the neurosurgical ward. The patients were allowed a normal diet and were able to walk in the ward. Patients were usually discharged by day 2 or 3 after treatment, except those in the acute phase of SAH or with coexisting tumors or AVMs. After embolization, the interventional neuroradiologists and members of the neurosurgery team performed the initial and follow-up clinical evaluations during the post-procedural hospitalization and at the outpatient clinic.

Clinical and Angiographic Follow-Up Studies

Follow-up clinical and angiographic evaluations were conducted as follows: 1) after 3 months of embolization if the occlusion had been incomplete as shown by any residual neck or dome filling on immediate postembolization angiograms, or 2) after 6 to 12 months of embolization if the aneurysm had been completely occluded. Some patients underwent yearly clinical and angiographic follow-up for up to 5 years. Members of the interventional neuroradiology team evaluated the follow-up angiograms.

Results

Immediate Anatomic Outcomes

Angiographic results revealed complete occlusion in 138 (55.9%) of 247 aneurysms, incomplete occlusion in three (1.2%), and neck remnants in 92 (37.2%). GDC embolization was unsuccessfully attempted in 14 (5.7%). Of the 14, 12 had wide necks. This sort of finding, before the use of 3D coils and the balloon-assisted technique, significantly limited GDC embolization. Six of these cases underwent surgical clipping, and five were treated conservatively. Two small aneurysms had necks that were small according to the definition stated; in relation to the diameter of the aneurysm, however, the necks were wide, preventing the secure positioning of coils within the aneurysm. Surgical clipping was performed in those two cases.

Of the 84 aneurysms in the small aneurysm with small neck category, 63 (75%) resulted in complete embolization and 20 (23.8%) presented with neck remnants after the procedure. Embolization was attempted unsuccessfully in one patient.

Of 61 aneurysms in the small aneurysm with wide neck category, 30 (49.2%) achieved complete embolization and 23 (37.7%) resulted in neck remnants. In eight patients, the procedure was attempted.

Of 62 aneurysms in the large aneurysm category, 30 (48.4%) achieved complete embolization, 27 (43.5%) had neck remnants, and one (1.6%) had incomplete

embolization. In four patients, the procedure was attempted.

Of 29 aneurysms in the giant aneurysm category, only seven (24.1%) were completely embolized. Twenty (69%) had neck remnants, and two (6.9%) were incompletely embolized (Fig 1).

Immediate Clinical Outcome

All patients were clinically evaluated before hospital discharge. Of 19 patients with coexisting SAH (group 5), 17 (89.5%) remained neurologically unchanged. One patient experienced, during the procedure, embolization of the left middle cerebral artery that was treated with urokinase infusion. Although the angiogram showed reopening of the artery, the patient developed right hemiparesis. Another patient with two carotid cave aneurysms presented with severe vasospasm during embolization, and after the procedure, she developed left hemiparesis. She was thus taken back to the angiography suite, and angioplasty of the middle cerebral artery was performed. Despite treatment, the patient's condition deteriorated, and CT of the head showed a large right subcortical hematoma in the frontotemporal region that was emergently evacuated. Postoperatively, the patient was transferred to the intensive care unit where her condition deteriorated progressively. She died 7 days later.

Of the 198 patients without acute SAH (groups 1–4), 186 (93.9%) remained neurologically intact. Eleven (5.6%) presented with neurologic deficits, and one patient, a 58-year-old patient with two basilar-superior cerebellar artery aneurysms and a left parietal AVM, died (0.5%). After embolization of the AVM nidus, four arterial feeders, and >90% of the right aneurysm, during the delivery of the final soft GDC, excessive catheter tension caused rupture of the aneurysm. Immediate reversal of heparin was performed with protamine, and an additional coil was deployed to stop the bleeding. Postembolization angiography showed complete occlusion of the aneurysm. CT of the head showed diffuse SAH and hydrocephalus. An emergent ventriculostomy was placed, and the patient was transferred to the neuro-intensive care unit. The patient remained deeply comatose with flat EEG readings. The intracranial pressure was difficult to manage despite maximal medical therapy and intraventricular drainage, and the patient's course was complicated with severe pulmonary edema and extensive myocardial infarction. The patient died 4 days after the procedure.

The overall immediate clinical outcome for all groups was as follows: 203 (93.5%) of 217 patients were unchanged, 12 (5.5%) developed new neurologic deficits, and two (0.9%) died as the result of a cause directly related to the aneurysm itself or endovascular procedure (Table 4).

Procedural Complications

Technical complications were observed in 15 patients during GDC embolization. Eight (3.7%) of 217

TABLE 4: Clinical outcome

	Number of Patients (%)
Immediate clinical outcome	
Unchanged	203 (93.5)
Neurologic deficit	12 (5.5)
Death	2 (0.9)
Clinical follow-up	
Improved	20 (16.9)
Unchanged	88 (74.6)
Neurologic deficit	5 (4.2)
Death	2 (1.7)

TABLE 5: Technical complications

	Number of Patients (%)
Cerebral embolization	8 (3.7)
Aneurysm perforation	3 (1.4)
Arterial dissection	2 (0.9)
Coil rupture	1 (0.5)
Coil migration	1 (0.5)
Total	15 (6.9)

patients experienced cerebral embolization, three (1.4%) experienced aneurysm perforation, two (0.9%) presented with arterial dissection in the neck, one (0.5%) experienced coil rupture, which is fragmentation of one of the coils at a level different from that of the detachment system, and another (0.5%) experienced coil migration, which is displacement of the coil into the parent artery lumen after detachment. One patient died as the result of aneurysm perforation (Table 5).

Length of Hospital Stay

The mean period of hospitalization was 2.9 days (SD, 2.8) for asymptomatic patients. Patients with symptoms caused by mass effect (group 2) had a mean hospitalization of 5 days (SD, 4.6). For patients with UIAs associated with AVMs or tumors and for those with history of SAH (groups 3 and 4), the mean period of hospitalization was 5.7 days (SD, 5.6) and 2.9 days (SD, 1.7), respectively. For patients with acute SAH (group 5), the mean period of hospitalization was 15.4 days (SD, 8.1).

Anatomic Follow-up

Follow-up anatomic findings were assessed by performing angiography in multiple projections, and the results were classified as follows: unchanged ($\leq 10\%$ increase of contrast filling in the aneurysm compared with the immediate postembolization angiography), further thrombosis (no contrast filling in the residual neck or incomplete embolization), and recanalization ($>10\%$ of increase in contrast filling in the aneurysm) (Table 6).

Follow-up angiograms were obtained of 125 patients (143 aneurysms). The mean time of follow-up was 11.9 months (SD, 10.3). Of 79 UIAs that were

TABLE 6: Angiographic Follow-up

	% (n)
Unchanged	80.4 (115/143)
Recanalization	11.9 (17/143)
From complete embolization	6.3 (5/79)
From neck remnant	18.7 (12/64)
Further thrombosis	7.7 (11/143)

Note.—Follow-up was conducted of 125 patients of a total of 217 patients (58%). The 125 patients had 143 aneurysms. The mean follow-up period was 11.9 months (SD, 10.3 months).

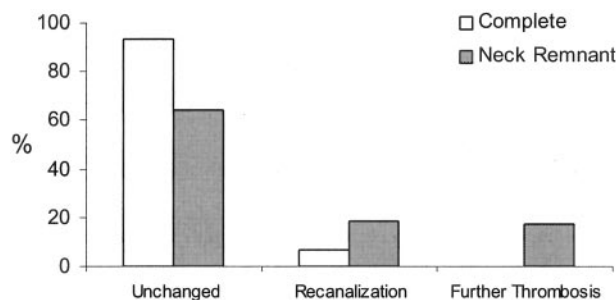


FIG 2. Histogram shows anatomic follow-up after initial aneurysm packing.

completely embolized, five (6.3%) recanalizations occurred: two in giant aneurysms, two in large aneurysms, and one in a small aneurysm, all of them with wide necks. No recanalization occurred in small aneurysms with small necks. Of 64 aneurysms that had neck remnants after embolization, 12 (18.7%) recanalized, 11 (17.2%) further thrombosed completely, and the other 41 (64.1%) did not change (Fig 2). The overall recanalization rate was 11.9%.

Two delayed ruptures occurred. One was a giant aneurysm that presented with a large neck remnant after embolization and ruptured after 8 months. The patient was treated during the early phase of GDC experience. After 1995, only one delayed rupture was reported, and it occurred in a large aneurysm with a wide neck. This aneurysm was successfully embolized but recanalized after 12 months. One month later, the patient was admitted with intracranial bleeding and died.

Clinical Follow-up

Of the 118 patients who were followed clinically, 20 (16.9%) experienced improvement of their previous neurologic conditions, 88 (74.6%) were neurologically intact or remained unchanged, and five (4.2%) presented with neurologic deficits at the time of the last follow-up visit. Deaths in the follow-up period occurred in five patients, three of them with causes not directly related to the aneurysm or the endovascular procedure (1.7%) (Table 4). The overall mortality rate in our series was 3.5% (4/115).

Discussion

The main limitations of our study were its retrospective nature and the lack of clinical and angio-

graphic follow-up data for a considerable percentage of patients. These limited our ability to draw firm conclusions.

Cerebral aneurysm is one of the major causes of hemorrhagic stroke in patients with cerebrovascular disease. Aneurysmal SAH has a 30-day mortality rate of 45% and an approximately 50% rate of disabilities among survivors (11). The annual incidence of SAH is between six and 16 per 100,000, with the highest rates reported in Japan and Finland (11–14).

Cigarette smoking, aneurysm size, patient age, and female sex have been reported as factors that increase the risk of aneurysm enlargement and subsequent rupture (15). Although prevention of SAH has been promoted as the most effective strategy for lowering the morbidity and mortality rates, the management of patients with UIAs remains controversial (16).

Recently, the largest study of UIAs, the International Study of Unruptured Intracranial Aneurysms (1), reported a rupture rate of 0.05% for UIAs <10 mm in diameter and no history of SAH and 0.5% for those with previous SAH. In aneurysms >10 mm, the rate of rupture was approximately 1% for UIAs with or without previous SAH (17). These values are lower than the results reported by other individual centers (15, 18). The study concluded that surgery does not clearly reduce the morbidity and mortality rates of UIAs without history of SAH. More recently, after detailed evaluation of aneurysm location and risk of rupture, the International Study of Unruptured Intracranial Aneurysms published slightly but not markedly higher rates when intracavernous aneurysms were excluded from analysis. Discussion regarding this issue is still ongoing, and more studies are needed before a final conclusion can be reached.

As an alternative to the surgical treatment of ruptured and unruptured aneurysms, the GDC system has proved to be effective, with good outcomes achieved in early clinical and angiographic settings (2–9). In addition, morbidity and mortality rates have improved in recent years, in part because of the increased expertise of interventional neuroradiologists and improved devices used to navigate the vascular tree.

In the study presented by Johnston et al (19), comparing surgical clipping versus coil embolization of UIAs, a morbidity rate of 18.5% was found in the surgical group, 10.6% in the endovascular group, and mortality rates of 2.3% and 0.4%, respectively. The same study also showed a lower hospitalization length, lower risk of discharge to nursing homes or rehabilitation facilities for patients with endovascular treatment, and lower costs for the patient.

We treated 217 patients with UIAs during the last 10 years. This study included a larger number of female patients, with a male:female ratio of 1:3.3. Our population also contained an important amount of elderly patients, and it is recognized that patient age and medical condition significantly impact clinical outcome after surgical interventions (20).

Our results showed that the GDC system was safe for treatment of these unruptured aneurysms. Early

successful anatomic and clinical results and low overall complication rates (5.5% morbidity, 0.9% mortality) were achieved. In addition, during follow-up, our results showed similar rates, with a morbidity rate of 4.2% and an aneurysm-related mortality rate of 3.5%. We did not include three patients with death caused by other conditions unrelated to the aneurysm and endovascular procedure.

Angiographic follow-up showed that two giant, two large, and one small aneurysm with wide necks that had been completely embolized recanalized (6.3% recanalization rate), and 12 aneurysms with neck remnants after initial embolization also recanalized (18.7% recanalization rate). These results confirmed that recanalization of aneurysmal lumen is an important limitation in large and giant aneurysms with wide necks. Complete embolization does not guarantee permanent occlusion in large or giant aneurysms, and the presence of neck remnants increases the risk of compaction of the coils and recanalization. Technical refinements, such as 3D coils and the balloon-assisted technique, have improved our ability to obtain complete neck occlusions and, therefore, to reduce the risk of recanalization. However, even with complete occlusions, that risk persists with GDC technology. Despite the high recanalization rate associated with large and giant aneurysms, we experienced only two delayed ruptures during the follow-up period.

Our results also indicated that GDC embolization can be performed safely even in cases with difficult surgical locations and poor clinical conditions. We did not observe more complications in patients treated for posterior fossa aneurysms than in patients with aneurysms in the anterior circulation. This is completely different from the experience reported in the neurosurgical literature, in which the posterior circulation location has been reported to significantly increase the risk of complications (21, 22). Rice et al (23) reported a successful series in the surgical treatment of posterior circulation aneurysms; however, those results are not comparable with those of our study because they excluded giant aneurysms.

Yundt et al (9) reported hospitalization periods for patients with surgically treated unruptured aneurysms of 10.9 days, including 4.2 days in an intensive care unit. In our study, the average hospitalization period for patients without acute SAH, mass effect, AVMs, or associated tumors was 2.9 days (groups 1 and 4). Therefore, GDC embolization of UIAs requires shorter hospitalization time, with a positive economic impact in the cost of public health.

In the group with mass effect, 32 patients were followed clinically and 15 (46.9%) of the 32 experienced improved neurologic condition, especially those presenting with symptoms of cranial nerve palsy. In addition, the overall recanalization rate was 38.9% (14 of 36 aneurysms with angiographic follow-up), which was higher than in the other groups, probably because of the relatively larger size aneurysms encountered in the mass effect group. Four deaths occurred in this group, three of them as a result of causes not related to the aneurysm or endovascular

procedure. Those three were thus not included in the overall follow-up mortality count. Only one patient died as a result of delayed rupture of the aneurysm. We did not observe more technical complications, and only one case of coil rupture occurred. Our study showed that aneurysms causing mass effect could be effectively treated with GDC embolization, with no higher procedure-related risks and with good recovery of symptoms achieved.

Conclusion

From our results, we can conclude the following. First, GDC technology constitutes safe treatment for unruptured aneurysms, with early successful anatomic and clinical results and low complication rates achieved. Second, recanalization of the aneurysm lumen is an important limitation in large, giant, and wide necked aneurysms. Third, complete embolization does not guarantee permanent occlusion, as shown by our 6.3% recanalization rate after complete packing, and the risk nearly triples (18.7%) when there are neck remnants. Fourth, mass effect symptoms can be effectively reversed by using the GDC technique.

References

1. Murayama Y, Nien YL, Duckwiler G, et al. **Guglielmi detachable coil embolization of cerebral aneurysms: 11 years' experience.** *J Neurosurg* 2003;98:959-966
2. Graves VB, Strother CM, Duff TA, Perl J II. **Early treatment of ruptured aneurysms with Guglielmi detachable coils: effect on subsequent bleeding.** *Neurosurgery* 1995;37:640-648
3. Guglielmi G, Viñuela F, Dion J, Duckwiler G. **Electrothrombosis of saccular aneurysms via endovascular approach: part 2. preliminary clinical experience.** *J Neurosurg* 1991;75:8-14
4. Moret J, Pierot L, Boulin A, Castaings L, Rey A. **Endovascular treatment of anterior communicating artery aneurysms using Guglielmi detachable coils.** *Neuroradiology* 1996;38:800-805
5. Murayama Y, Viñuela F, Duckwiler GR, Gobin YP, Guglielmi G. **Embolization of incidental cerebral aneurysms by using the Guglielmi detachable coil system.** *J Neurosurg* 1999;90:207-214
6. Nichols DA, Brown RD Jr, Thielen KR, Meyer FB, Atkinson JL, Piegras DG. **Endovascular treatment of ruptured posterior circulation aneurysms using electrolytically detachable coils.** *J Neurosurg* 1997;87:374-380
7. Raymond J, Roy D, Bojanowski M, Moumdjian R, L'Esperance G. **Endovascular treatment of acutely ruptured and unruptured aneurysms of the basilar bifurcation.** *J Neurosurg* 1997;86:211-219
8. Viñuela F, Duckwiler G, Mawad M. **Guglielmi detachable coil embolization of acute intracranial aneurysm: perioperative anatomical and clinical outcome in 403 patients.** *J Neurosurg* 1997;86:475-482
9. Yundt KD, Dacey RG Jr, Diringer MN. **Hospital resource utilization in the treatment of cerebral aneurysms.** *J Neurosurg* 1996;85:403-409
10. Moret J, Cognard C, Weill A, Castaings L, Rey A. **Reconstruction technic in the treatment of wide-neck intracranial aneurysms: long-term angiographic and clinical results Apropos of 56 cases [in French].** *J Neuroradiol* 1997;24:30-44
11. Graves EJ. **Detailed diagnosis and procedures, National Hospital Discharge Survey, 1990.** *Vital Health Stat* 13 1992;113:1-225
12. Broderick JP, Brott TG, Duldner JE, Tomsick T, Leach A. **Initial and recurrent bleeding are the major causes of death following subarachnoid hemorrhage.** *Stroke* 1994;25:1342-1347
13. Kiyohara Y, Ueda K, Hasuo Y, et al. **Incidence and prognosis of subarachnoid hemorrhage in a Japanese rural community.** *Stroke* 1989;20:1150-1155
14. Sarti C, Tuomilehto J, Salomaa V, et al. **Epidemiology of subarachnoid hemorrhage in Finland from 1983 to 1985.** *Stroke* 1991;22:848-853

15. Juvela S, Porras M, Poussa K. **Natural history of unruptured intracranial aneurysms: probability of and risk factors for aneurysm rupture.** *J Neurosurg* 2000;93:379–387
16. Bederson JB, Awad IA, Wiebers DO, et al. **Recommendations for the management of patients with unruptured intracranial aneurysms: a statement for healthcare professionals from the Stroke Council of the American Heart Association.** *Stroke* 2000;31:2742–2750
17. International Study of Unruptured Intracranial Aneurysms Investigators. **Unruptured intracranial aneurysms: risk of rupture and risks of surgical intervention.** *N Engl J Med* 1998;339:1725–1733
18. Tsutsumi K, Ueki K, Morita A, Kirino T. **Risk of rupture from incidental cerebral aneurysms.** *J Neurosurg* 2000;93:550–553
19. Johnston SC, Dudley RA, Gress DR, Ono L. **Surgical and endovascular treatment of unruptured cerebral aneurysms at university hospitals.** *Neurology* 1999;52:1799–1805
20. Khanna RK, Malik GM, Qureshi N. **Predicting outcome following surgical treatment of unruptured intracranial aneurysms: a proposed grading system.** *J Neurosurg* 1996;84:49–54
21. King JT Jr, Berlin JA, Flamm ES. **Morbidity and mortality from elective surgery for asymptomatic, unruptured, intracranial aneurysms: a meta-analysis.** *J Neurosurg* 1994;81:837–842
22. Wirth FP, Laws ER Jr, Piepgras D, Scott RM. **Surgical treatment of incidental intracranial aneurysms.** *Neurosurgery* 1983;12:507–511
23. Rice BJ, Peerless SJ, Drake CG. **Surgical treatment of unruptured aneurysms of the posterior circulation.** *J Neurosurg* 1990;73:165–173