



Discover Generics

Cost-Effective CT & MRI Contrast Agents



WATCH VIDEO

AJNR

Lacrimonal Location of Sinus Histiocytosis (Destombes-Rosai-Dorfman Disease)

Robin Azoulay, Hervé Brisse, Paul Fréneaux, Solène Ferey,
Gabriel Kalifa and Catherine Adamsbaum

AJNR Am J Neuroradiol 2004, 25 (3) 498-500

<http://www.ajnr.org/content/25/3/498>

This information is current as
of June 23, 2025.

Case Report

Lacrimal Location of Sinus Histiocytosis (Destombes-Rosai-Dorfman Disease)

Robin Azoulay, Hervé Brisse, Paul Fréneaux, Solène Ferey, Gabriel Kalifa, and Catherine Adamsbaum

Summary: A 7-year-old West African male patient presented with recurrence of multiple cervical lymphadenopathy. Cervical node biopsy disclosed a sinus histiocytosis with massive lymphadenopathy (Rosai-Dorfman-Destombes disease). During follow-up, the patient developed a left orbital mass corresponding to an enlarged lacrimal gland shown by CT. The histologic features of the gland were consistent with the diagnosis, and with steroid treatment, the gland decreased in size. Although rare, the diagnosis of sinus histiocytosis with massive lymphadenopathy has to be considered in cases of lacrimal gland enlargement.

Sinus histiocytosis with massive lymphadenopathy (Rosai-Dorfman-Destombes disease) is a rare benign histiocytosis that affects children and young adults. The clinical presentation is most often a bilateral cervical painless lymphadenopathy. We herein report an unusual location of Rosai-Dorfman-Destombes disease.

Case Report

A 7-year-old West African male patient had presented with multiple cervical lymphadenopathies in his native country at the age of 1 year. The findings of the cervical node biopsy, performed at the age of 3 years, were interpreted as Hodgkin disease, and chemotherapy treatment had been administered (10 cures of mechlorethamine, oncovin, procarbazine, and prednisone). Complete regression of the nodes was then observed.

At the age of 6 years, the patient presented in France with multiple bilateral cervical and supraclavicular lymphadenopathies. The laboratory results showed a hemoglobin rate of 11.1 g/dL, an erythrocyte sedimentation rate of 23, a normal white blood cell count, and a normal gamma globulin rate. A second cervical node biopsy was performed and revealed normal lymph node architecture associated with mixed inflammatory infiltration of lymphocytes, plasma cells, and histiocytes. Large cells were observed in the dilated sinuses of the lymph node, containing lymphocytes in their vacuolized cytoplasm. Immunohistochemistry showed that these large cells expressed a histiocyte antigen (CD68). In contrast, these large cells did not express CD15 and CD30, which discounted Hodgkin disease and large cell lymphoma. They expressed neither epithelial cell antigens nor Langerhans cell antigens (CD1a). Thus, the diag-

nosis of sinus histiocytosis with massive lymphadenopathy, so called *Rosai-Dorfman-Destombes disease*, was assessed. Spontaneous regression was observed.

At the age of 7 years, the patient presented with a supraorbital left mass. He did not have any fever, diplopia, or orbital pain. The general condition was excellent without any weight loss or pallor. Physical examination revealed the mass to be palpable in the supra-external left orbit. Recurrence of cervical and bilateral supraclavicular lymphadenopathy was observed.

CT of the orbits disclosed a homogeneous enhancing soft-tissue mass of the left orbit that was extraconal in respect to muscles, optic nerve, and bone structures. This mass corresponded to an enlarged left lacrimal gland, with its typical supratemporal location (Fig 1A and B). The right lacrimal gland appeared normal.

The lacrimal gland biopsy showed polymorphic plasma cell infiltration with lymphocytes, plasmacytes, histiocytes, and rare phagocytes. Immunohistochemistry showed the polytypic character of the lymphocytes, with various expressions of CD3 and CD20, the histiocyte's expression of CD 68, and no expression of CD1a antigen. These findings were consistent with the diagnosis of sinus histiocytosis. Both left lacrimal gland and cervical adenopathy decreased progressively in size during the oral administration of steroid therapy for a period of 1 month.

Discussion

Rosai-Dorfman-Destombes disease, or sinus histiocytosis, with massive lymphadenopathy is a rare benign histiocytosis that affects predominantly children and young adults, with a slight male predominance (58% for male versus 42% for female) (1). After the initial description presented by Destombes in 1965 (2), this disease was defined by Rosai and Dorfman (1) and Foucar et al (3) as a clinicopathologic entity. In 1990, they published the largest series of 423 patients (1). The registry now contains >600 cases (4). The patients are young, with a mean age of 20.6 years at the onset of the disease (1). Black people from America, the Caribbean, and West-Africa are more frequently affected (43.6%) (1).

Approximately 87% of patients have bilateral cervical painless lymphadenopathy, (1) which can suggest a lymphoma. Other nodal groups are less frequently involved, and 43% of patients have at least one site of extranodal localization, which includes upper respiratory tract, skin, bones, salivary glands, and the CNS (1).

Various clinical and laboratory findings include fever, anemia, neutrophilia, hypergammaglobulinemia, and elevated erythrocyte sedimentation rate (1, 5). Almost 13% of patients have an associated immune disorder, such as autoantibodies against red cells and joint disease (1, 5).

Histologic examination of lymphadenopathy shows

Received February 11, 2003; accepted after revision June 11.

From the Department of Pediatric Radiology (R.A., S.F., G.K., C.A.), Hôpital St-Vincent-de Paul, and the Departments of Radiology (H.B.) and Pathology (P.F.), Institut Curie, Paris, France.

Address reprint requests to Catherine Adamsbaum, Hôpital St-Vincent-de-Paul, 82, Avenue Denfert-Rochereau, 75674 Paris, France.

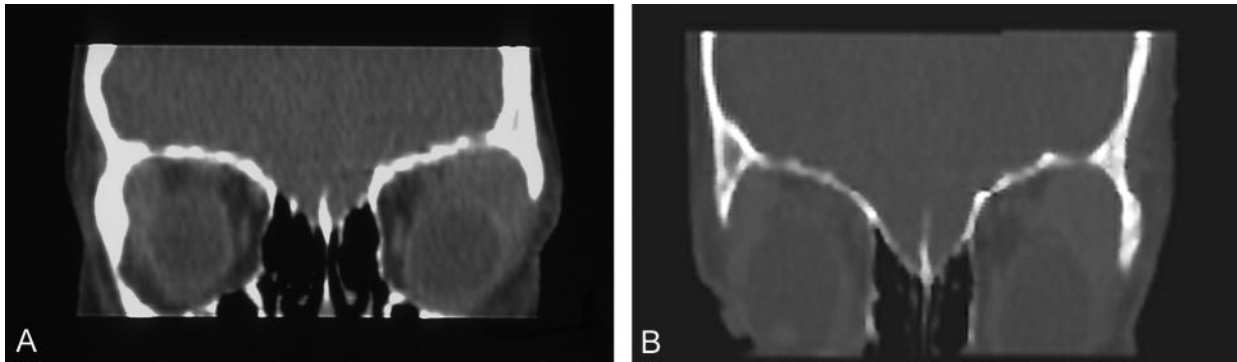


Fig 1. Coronal view CT reconstruction.

- A, Presence of an extraconal mass corresponding to the enlarged lacrimal gland on the left side.
B, Absence of destruction of bone.

a normal structure of the lymph node with a thickened and fibrotic capsule along with polymorphous cellular infiltration of neutrophils and lymphocytes. The dilated sinuses are infiltrated with histiocytes containing phagocytized normal lymphocytes within an abundant cytoplasm (1, 3, 5). Immunohistochemistry shows that these histiocytes are positive for S100 protein and do not express CD1a as in Langerhans cell histiocytosis. The presence of lymphophagocytic histiocytes (as observed in the patient reported herein) associated with S100 protein positivity constitutes a strong indicator (1, 3, 5, 6). Unfortunately, we did not have access to our patient's first histologic slides and were thus unable to review the initial data.

Complete remission frequently occurs over several months or years, either spontaneously or with the administration of steroid treatment, as in our case report. However, systemic involvement rarely has a fatal outcome (1).

Ophthalmic manifestations are rare and seen in 9% to 11% of cases (1, 4). The most frequent ophthalmic manifestation is an orbital soft-tissue mass with proptosis or eyelid (4, 6, 7). To our knowledge, few articles have reported lacrimal gland involvement in children or adults (1, 4, 6, 7–10).

Histologic examination of lacrimal gland can show the presence of inflammatory cells and Rosai-Dorfman cell infiltration (6, 8–12). To our knowledge, only seven case reports of lacrimal involvement in sinus histiocytosis have been presented in the literature. The lacrimal gland involvement can be unilateral or bilateral, as shown by CT (6, 8–12). The pattern of the enlarged gland is not specific, and the trick is to recognize the gland enlargement in respect to all other orbital structures. In our case report, the lack of local bony abnormality was important to check in the aim to rule out a metastatic location of neuroblastoma, a granulocytic sarcoma (chloroma), Langerhans-cell histiocytosis, and, more rarely, a primitive osteogenic tumor. Moreover, the weak enhancement observed on the CT scan appeared interesting to rule out a highly vascularized tumor, such as angioma.

However, the differential diagnoses of other soft-tissue masses that may occur in the lacrimal gland in children have to include a number of possibilities,

such as dacryoadenitis, granulomatous inflammatory diseases, inflammatory idiopathic pseudotumors, and tumors (13, 14). Because most of these diagnoses have the same CT pattern as that of Rosai-Dorfman-Destombes disease, the clinical presentation and the biologic data are important to consider. Dacryoadenitis is most often viral in nature and is very rare in children. Children with dacryoadenitis present with a lacrimal gland swelling and local inflammatory signs, adenopathy, fever, and leukocytosis. The CT scan shows a diffuse unilateral or bilateral lacrimal gland enlargement without bony defect as a lacrimal location of Rosai-Dorfman-Destombes disease (14). Viral dacryoadenitis usually improves spontaneously, and recurrences are unusual. Sarcoidosis and Wegener disease are the most frequent causes of lacrimal gland inflammation. With these two diseases, the lacrimal gland location is unusual and very rarely isolated (14). The CT abnormalities are similar to those associated with Rosai-Dorfman-Destombes disease. Thus, the associated clinical symptoms, the biology, and the lacrimal gland biopsy confirm the diagnosis.

Inflammatory idiopathic pseudotumors can involve the lacrimal gland. Its presentation is usually more acute and more inflammatory than that of Rosai-Dorfman-Destombes disease, mimicking an orbital abscess (14). However, the CT pattern is not specific and the definite diagnosis is based also on the histologic data (14).

Tumors of the lacrimal gland in children are rare and include lymphoproliferative disease and epithelial tumors. Again, CT does not disclose any specific sign (13).

In addition, most of these differential diagnoses are sensitive to steroids, as is Rosai-Dorfman-Destombes disease. Thus, when faced with an apparently isolated chronic lacrimal mass, the diagnosis must rely on the biopsy.

For our patient, we considered the lacrimal gland enlargement to be a recurrence of the sinus histiocytosis on the basis of his history, the presence of a cervical bilateral lymphadenopathy, the cervical node histology, and consistent lacrimal gland histologic findings. Nevertheless, patients with Rosai-Dorfman-Destombes disease can present with a soft-tissue mass

occurring in the lacrimal gland without any sign suggestive of lymphadenopathy (10, 12). For these patients, diagnosis must be based on histologic and immunohistopathologic findings after surgical biopsy.

Acknowledgment

We acknowledge the contributions of Drs. Orbach and Desjardins from Institut Curie in Paris.

References

1. Rosai J, Dorfman RF. Sinus histiocytosis with massive lymphadenopathy: a newly recognized benign clinicopathological entity. *Arch Pathol* 1969;87:63–70
2. Destombes P. Adenitis with lipid excess, in children or young adults, seen in the Antilles or Mali (4 cases). *Bull Soc Pathol Exot Filiales* 1965;58:1169–1175
3. Foucar E, Rosai J, Dorfman R. Sinus histiocytosis with massive lymphadenopathy (Rosai-Dorfman disease): review of the entity. *Semin Diagn Pathol* 1990;7:19–73
4. Rosai J, Dorfman RF. Sinus histiocytosis with massive lymphadenopathy: a pseudolymphomatous benign disorder: analysis of 34 cases. *Cancer* 1972;30:1174–1188
5. Carbone A, Passannante A, Gloghini A, Devaney KO, Rinaldo A, Ferlito A. Review of sinus histiocytosis with massive lymphadenopathy (Rosai-Dorfman disease) of head and neck. *Ann Otol Rhinol Laryngol* 1999;108:1095–1104
6. Dhermy P, Destombes P, Rousselie F. Orbital localization of lymphocytic macrophagic histiocytosis (Rosai's sinus histiocytosis) [in French]. *Arch Ophthalmol Rev Gen Ophthalmol* 1975;35:871–884
7. Foucar E, Rosai J, Dorfman RF. The ophthalmologic manifestations of sinus histiocytosis with massive lymphadenopathy. *Am J Ophthalmol* 1979;87:354–367
8. Beckingsale P, Sullivan T, Whitehead K. A case of Rosai-Dorfman disease involving the lacrimal gland in an elderly patient. *Orbit* 2002;2:169–175
9. Lee-Wing M, Oryschak A, Attariwala G, Ashenurst M. Rosai-Dorfman disease presenting as bilateral lacrimal gland enlargement. *Am J Ophthalmol* 2001;5:677–678
10. Reddy A, Beigi B, Linardos E. Rosai-Dorfman syndrome affecting the lacrimal gland. *Orbit* 2001;3:239–242
11. Quintyn JC, Ranty ML, Courville P, Metayer J, Retout A. Orbital sinus histiocytosis (Rosai-Dorfman disease): a lacrimal gland involvement. *Ophthalmologica* 2002;4:277–280
12. Wang E, Anzai Y, Paulino A, Wong J. Rosai-Dorfman disease presenting with isolated bilateral orbital masses: report of two cases. *AJNR Am J Neuroradiol* 2001;22:1386–1388
13. Shields JA, Shields CA. Ocular tumors of childhood. In: Nelson LB, ed. *Harley's Pediatric Ophthalmology*. 4th ed. Philadelphia: W.B. Saunders Co.; 1998:397–409
14. Stefanaszyn MA, Harley RD, Penne RB. Disorders of the orbit. In: Nelson LB, ed. *Harley's Pediatric Ophthalmology*. 4th ed. Philadelphia: W.B. Saunders Co. 1998:376–396