



## Discover Generics

Cost-Effective CT & MRI Contrast Agents



FRESENIUS  
KABI

WATCH VIDEO

# AJNR

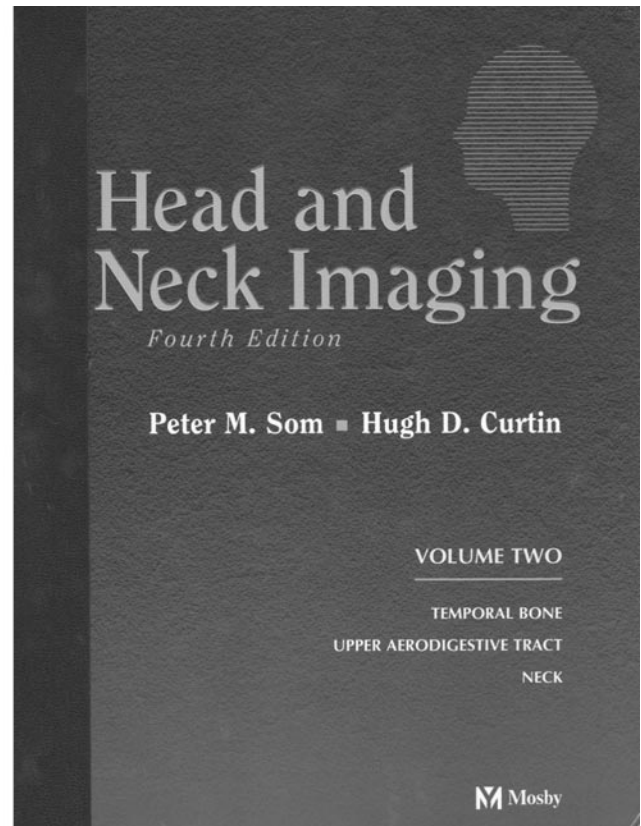
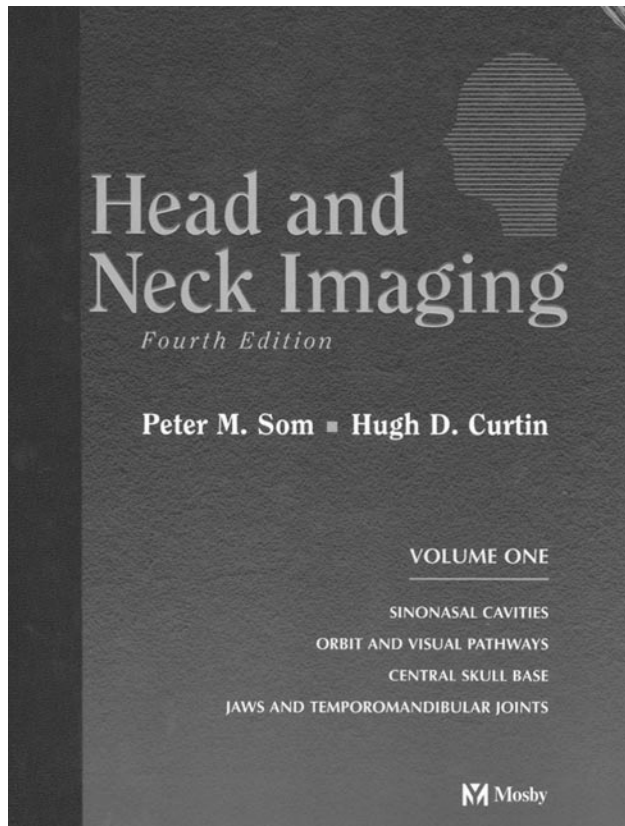
## Head and Neck Imaging

*AJNR Am J Neuroradiol* 2003, 24 (8) 1717-1719  
<http://www.ajnr.org/content/24/8/1717>

This information is current as  
of June 23, 2025.

# Head and Neck Imaging

Peter M. Som and Hugh D. Curtin. 4th ed. 2 vols. St. Louis: Mosby; 2003. 1,950 pages, 4,530 illustrations. \$329.



Few textbooks in radiology deserve to be called “classics,” but Peter Som and Hugh Curtin’s *Head and Neck Imaging* clearly belongs in that category. With this fourth edition, one realizes how far and how quickly the field of ear, nose, and throat (ENT) radiology has progressed. The third edition, published just 7 years ago, was 1,545 pages in length; this newest (2003) edition has been expanded to 2,322 pages. So the immediate impulse is to ask, What in this edition was absent in the previous one?

A few years ago, when I heard that Drs. Som and Curtin were going to produce a new edition of their book, it was unclear to me what amplifications/refinements were necessary. Now we know. There are 777 more pages packed full of more pathology, newer images and techniques, and a deeper look at the clinical aspects of head and neck imaging. The expansion of the book actually understates how much more material is in this edition; the print size of the legends and references are smaller (but just as legible), individual image sizes are in general smaller (without the loss of any vital findings), and the design and layout of the current edition is, to my eye, crisper and cleaner.

Seventy-six authors contributed to this book, and

the list of contributors reads like a who’s who of head and neck imaging. Their work has been divided into seven major sections, namely, “Sinonasal Cavities,” “Orbit and Visual Pathways,” “Central Skull Base,” “Jaws and Temporomandibular Joints,” “Temporal Bone,” “Upper Aerodigestive Tract,” and “Neck.” Nearly each of these sections could stand as a book by itself, so in a sense one is purchasing seven separate books, albeit in two large volumes. Although it is not possible to describe in any sort of detail the entire book, it seems worthwhile to mention a few of the new additions.

There has been a dose of genetics integrated into a few chapters; for instance in the first section, “Sinonasal Cavities” and the opening chapter on embryology and congenital lesions of the midface, Dr. Naidich introduces the reader to cell signaling and signal transduction and describes the role of molecular genetics in understanding morphological derangements of the skull. As with all the other chapters and sections in this book, the images have been updated and the reference lists expanded. The discussion of the anatomy and physiology of the sinonasal cavity has likewise been updated. One ordinarily would not

think that this anatomy could be meaningfully updated, but it has been, with new images and line drawings. A very nice touch, and a unique one as far as I know, is the inclusion of a tear-out listing of the abbreviations for all of the structures labeled in the chapter. This means that one does not have to go flipping back and forth to the legends for the identification of these structures; you can take the removable legends with you as you go from page to page. A gold star for whoever thought of that!

Sinus disease ranks with low back pain as a reason for ordering radiographic studies. That clinical emphasis is reflected in the markedly expanded sections dealing with the osteomeatal complex, functional endoscopic sinus surgery (FESS), complications of FESS, inflammatory sinus disease, sinus tumors, and facial fractures. The current edition contains an additional 100 pages on this material, with state-of-the-art imaging, protocol descriptions, detailed anatomy, and inclusion of nearly every possible imaging abnormality one is likely to encounter in a lifetime of radiology. A sufficient amount of histopathology and a great deal of clinical medicine accompanies many of the subsections of the book. New areas include a flow chart explaining the immunohistochemistry of ENT tumors, classification schemes and survival data on lymphoma, superb line drawings on different surgical approaches to sinus lesions, and, of course, expanded imaging. The images (CT and MR) here and throughout the book are described succinctly, and it is noteworthy that the images are appropriately labeled without an overabundance of arrows, which, when overdone, can obscure and degrade pertinent findings. This mistake the authors have avoided.

The input by Dr. Mafee in the "Orbit and Visual Pathways" section is encyclopedic in nature, with new drawings, greater detail on imaging techniques, new tables on differential diagnoses, helpful charts defining features to be evaluated in the orbit and eye, and, of course, a host of new images. Although most practitioners are very infrequently called on to evaluate the nasolacrimal drainage system, particularly with invasive procedures such as dacryocystography, there is an 80-page chapter that could serve as a complete tutorial on all aspects of imaging the lacrimal apparatus. Material on the visual pathways appears in the book because of the clinical and imaging overlap between intraorbital and intracranial abnormalities; here the material is dealt with in a standard, straightforward manner.

In a departure from the prior edition, the central skull base is presented as a separate entity, removing from the prior chapter "Skull Base" the entire section on the temporal bone, which in turn appears later in volume 2. The section "Central Skull Base" contains line drawings that aid in the understanding of the complex anatomy and the diverse pathology in this area. Newly included in this section is a chapter by Dr. Ginsberg on the perineural spread in head and neck cancer. This is a critical chapter because proper techniques are important and astute observations are needed to establish the correct diagnosis. Again, the

anatomic drawings aid in the understanding of the pathways of the involved pericranial peripheral nerves.

The section "Jaws and Temporomandibular Joints" discusses areas not relished by most neuroradiologists, but this 164-page segment may ignite interest in the topic. From embryology and normal anatomy to dental imaging, jaw lesions, and imaging of temporomandibular joints (TMJs), the material here is comprehensive, and readers will find of additional help the tables listing scanning parameters for TMJs, clinical/imaging classifications for internal TMJ derangements, and good gross pathology specimen associations with this classification. Dental imaging will probably be skipped by most all neuroradiologists, but inclusion of this material makes the book more complete that it would have otherwise been.

Although the subsections of the temporal bone portion of this book are named the same as in the prior edition (embryology/anatomy; imaging; trauma; otosclerosis; tumors; vascular tinnitus), the material contained in each area has dramatically increased. Take the anatomy/embryology as an example; here 15 pages are devoted to an atlas-like CT evaluation of this intricate anatomy, and new line drawings assist in the understanding of this complex area. There are correlations with gross sections, improved labeling of a greater number of slices, and far more material on MR imaging with emphasis on the normal fluid containing structures of the inner ear. Understanding these normal imaging features are important for appreciating new additions to the congenital anomalies section where the authors include material on deformities that are best seen with MR imaging. The thoroughness with which the remaining temporal bone abnormalities are dealt with is remarkable. I particularly appreciated the expanded area of temporal bone trauma, where there is more imaging and greater clinical correlations. Throughout the entire section the images are sharper, with far greater detail than in the prior edition.

With an increase of more than 100 pages, the upper aerodigestive tract is covered in remarkable detail. Subjects include the oral cavity, pharynx, pediatric airway disease, and larynx, all of which were included in the last edition, but added now are separate chapters on the trachea and videofluoroscopic evaluation of oropharyngeal swallowing. As in other areas of the book, the anatomy is fully illustrated and described in understandable detail. Very useful are tables in which the TNM (tumor, nodes, metastasis) classification of the different regional tumors are shown. They allow the radiologist to convey quickly to the referring clinician the tumor extent. The new sections on the trachea and swallowing are excellent additions. The trachea in particular is an area we seldom evaluate in routine imaging unless we are clinically directed to that structure. This new section now can serve as a source material in all aspects of tracheal imaging.

"Neck" is the largest section of the book, encompassing 565 pages, which is nearly double its size in

the previous edition. Mentioning just the new sections (ultrasound; skin and soft tissue lesions; genetics of tumor development; new imaging techniques) does little to convey how much this whole section has been improved. The completeness of all the chapters is staggering—from normal anatomy to the most encompassing review of nodes and nodal disease that I have seen, to the beautiful color plates showing a fascia and spaces of the neck, to the detailed anatomy of the salivary glands, to the most difficult of all areas, the posttreatment neck. Here the various surgical approaches to the neck are described and illustrated, and this in turn serves as a basis for the understanding of the imaging of those patients who have had surgical treatment with or without radiation/chemotherapy. The material on genetics of tumor development and metastasis (20 pages), while perhaps not immediately applicable to the routine imaging, will serve as an introduction to a topic that in the future will be increasingly alluded to in our field. To end this book Drs. Mukherji, Fischbein, and Castelijns beautifully define the current status of PET, SPECT, MR spectroscopy, ultrasmall superparamagnetic iron oxide

contrast for MR imaging of lymph nodes, and the use of radionuclide-labeled monoclonal antibodies for tumor targeting. The description of these cutting-edge techniques puts a final and forward-looking stamp to this all-inclusive book.

Although other radiologists throughout the world have contributed significantly to the field of head and neck radiology, Drs. Som and Curtin are, in this reviewer's opinion, responsible in large measure for establishing radiology of the head and neck as a true specialty area. This book is a major example of why that is and how they have defined the field of ENT radiology. An oft-used bromide in reviews such as this is "This book should be on every radiologist's shelf," but with this book, that is absolutely true, not only for radiologists but for all those physicians who deal with patients with abnormalities in the head and neck. Though the price of this two-volume set is high, there is a saying related to books which goes something like, "If I had to pay for what this book is worth, I couldn't afford it." This outstanding fourth edition of *Head and Neck Imaging* embodies that saying.