



Discover Generics

Cost-Effective CT & MRI Contrast Agents



FRESENIUS
KABI

WATCH VIDEO

AJNR

The Skull and Cervical Spine Radiographs of Tutankhamen: A Critical Appraisal

Richard S. Boyer, Ernst A. Rodin, Todd C. Grey and R. C. Connolly

AJNR Am J Neuroradiol 2003, 24 (6) 1142-1147

<http://www.ajnr.org/content/24/6/1142>

This information is current as
of June 4, 2025.

The Skull and Cervical Spine Radiographs of Tutankhamen: A Critical Appraisal

Richard S. Boyer, Ernst A. Rodin, Todd C. Grey, and R. C. Connolly

BACKGROUND AND PURPOSE: Tutankhamen, the last pharaoh of the XVIIIth dynasty, died unexpectedly at approximately age 18 years. A cause of death has never been established, but theories that the young king was murdered by a blow to the head have been proposed based on skull radiographs obtained by a team from the University of Liverpool in 1968. We recently had the opportunity to evaluate the skull and cervical spine radiographs of Tutankhamen. The purpose of this study was to report our critical appraisal of the radiographs of Tutankhamen regarding the findings alleged to indicate traumatic death.

METHODS: Copies of lateral, anteroposterior, and submental vertex skull radiographs of Tutankhamen were reviewed with special attention to the claims of a depressed skull fracture, intracranial bone fragments, and calcified membrane of a posterior fossa subdural hematoma. A phantom skull was radiographed to reproduce the appearance of the floor of the posterior fossa in the lateral projection.

RESULTS: The skull radiographs of Tutankhamen show only postmortem artifacts that are explainable by an understanding of the methods of mummy preservation used at the time of his death. Some findings also relate to trauma inflicted by an autopsy performed in 1925. The alleged calcified membrane of a posterior fossa subdural hematoma is easily reproduced with a skull phantom.

CONCLUSION: Our critical review of the skull and cervical spine radiographs of Tutankhamen does not support proposed theories of a traumatic or homicidal death.

It is generally agreed that Tutankhamen, the last pharaoh of the XVIIIth dynasty, died unexpectedly at approximately age 18 years. The cause of his death has never been conclusively established. It has been alleged that a blow to the head murdered the young pharaoh. Skull radiographs obtained in 1968 by a team from the University of Liverpool headed by Professor R.G. Harrison have been used as supportive evidence of this allegation (1). A video documentary of the conditions under which the radiographs were obtained and Harrison's conclusions about the radiographic findings was shown on British television in 1969 (2). The radiographs were never published in the medical literature, but an article by Harrison (3)—“Post Mortem on Two Pharaohs: Was Tutankhamen's Skull Fractured?”—was published in the December 1971 issue of *Buried History*. Harrison stated,

“While examining X-ray pictures of Tutankhamen's skull, I discovered a small piece of bone in the left side of the skull cavity. This could be part of the ethmoid bone, which had become dislodged from the top of the nose when an instrument was passed up the nose into the cranial cavity during the embalming process. On the other hand, the X-rays also suggest that this piece of bone is fused with the overlying skull and this could be consistent with a depressed fracture, which had healed. This could mean that Tutankhamen died from a brain hemorrhage caused by a blow to his skull from a blunt instrument.”

This evidence, taken together with the knowledge that the pharaoh was only 18 years old when he died and considered against the troubled times during which he lived, poses an intriguing question. Was Tutankhamen murdered?

A second article by Harrison (and coauthor Abdalla) (4)—“The Remains of Tutankhamun”—was published in *Antiquity*. In that publication, Harrison's team reported that Tutankhamen's body had been dismembered during the first autopsy, which was had been performed by Carter and Derry in 1925 (5). This process was necessary because the mummy was glued to the innermost coffin by an excessive use of unguents and had to be literally chiseled out to unwrap the body and retrieve the artifacts, which are now in

Received December 9, 2002; accepted December 23.

From the Department of Pediatric Medical Imaging, Primary Children's Medical Center, University of Utah, Salt Lake City, UT, and the Department of Human Anatomy and Cell Biology, University of Liverpool, Liverpool, England.

Address reprint requests to Richard S. Boyer, MD, Department of Medical Imaging, Primary Children's Medical Center, 100 North Medical Drive, Salt Lake City, UT 84113.

© American Society of Neuroradiology

the possession of several museums and have been displayed around the world. In the process, the head and cervical spine were severed from the remainder of the spinal column below the seventh cervical vertebra. Harrison (4) described the radiographic findings as follows: "The most prominent feature, however, is the presence of two attenuated shadows, the first along the vertex of the skull, and the second occupying the back (posterior) region of the skull. Each of these shadows possesses a fluid level, suggesting that radio-paque [sic] fluid was introduced into the cranial cavity with the skull lying vertex downwards, and then with the body lying horizontally, so that the posterior region of the skull was most dependent. In addition a small fragment of bone is seen in both lateral and frontal views of the skull, lying in the posterior aspect of the left parietal region of the skull. This, at first sight, looked like a piece of bone from the thin bony roof of the nasal cavity (the cribriform plate of the ethmoid bone), and perusal of the frontal X-ray of the skull confirms that this bone has disappeared from both sides of the floor of the skull. This would be very understandable, and could fit in well with known theories of the practice of mummification. It is a generally accepted view that an instrument is passed through the nostril, up into the nasal cavity to perforate or remove this bone, allowing extraction of the brain, and the introduction of any preservation fluid into the cranial cavity. On closer analysis, however, after further X-rays were developed and became available for study, several main objections to this theory were apparent and an alternative explanation suggested itself. This additional analysis will be discussed in a future publication."

No further publication was produced. However, on the previously mentioned BBC videotape in which the events surrounding the second autopsy as performed by Harrison's team are shown, the radiographic findings are explained by Harrison (2). As recorded on this tape, he regarded the bone splinter as a postmortem artifact. However, in the same video documentary, Harrison raised a question about the appearance of the posterior fossa of Tutankhamen on the lateral radiograph. Pointing to the floor of the posterior fossa, which he called "eggshell thinning" of the occipital bone, he said: "This is within normal limits. But in fact, it could have been caused by a hemorrhage under the membranes overlying the brain in this region, and this could have been caused by a blow to the back of the head, and this in turn could have been responsible for death."

These sentences have since been taken to indicate that the pharaoh had, in fact, been murdered. However, we propose that all findings alleged to indicate a traumatic death are explainable by an understanding of normal anatomy and the process of Egyptian mummification in practice at the time of Tutankhamen's death. Some artifacts are also due to an entry into the cranial vault at the time of the autopsy performed by Carter and Derry in 1925.

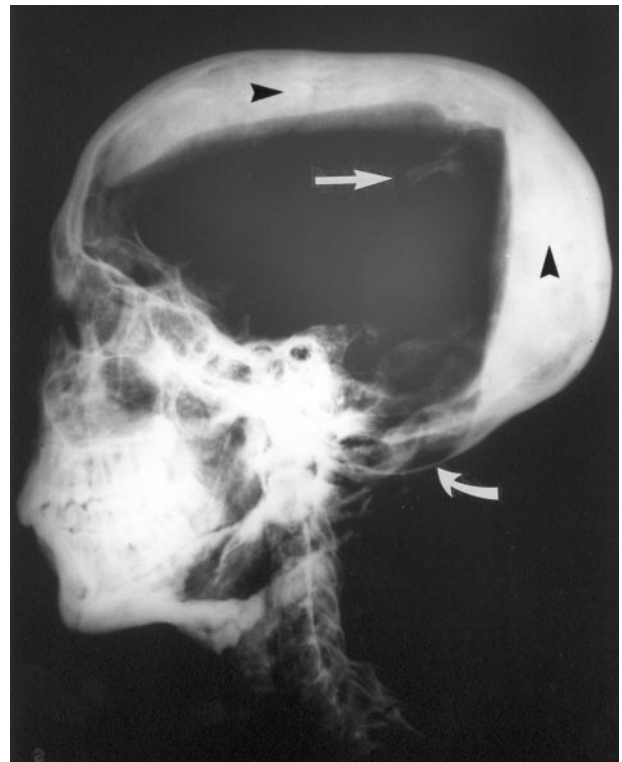


FIG 1. Lateral view radiograph of Tutankhamen's skull and cervical spine. Note the opaque layers of resin in the occipital and vertex regions (arrowheads), the bone fragments (straight arrow) that were probably dislodged during the 1925 autopsy, and the physiological thinning of the floor of the posterior fossa (curved arrow). (Reprinted courtesy of the University of Liverpool.)

Methods

Personal Investigations, Obtaining the Radiographs

One of the authors (E.A. Rodin) has had a longstanding interest in Egyptology. When he read in a German language publication regarding Tutankhamen (6) that radiographic evidence had revealed a skull defect, he pursued the matter further with R.C. Connolly in Liverpool, who was a member of the British investigative team led by Professor Harrison, which radiographed the remains of Tutankhamen in the pharaoh's tomb in 1968. An attempt was made to obtain copies of the radiographs, but this was not successful until Kate Botting contacted Rodin in August 2001 for an interview in anticipation of a Discovery Channel production, which aired in 2002 (7). Rodin agreed to the interview under the condition that Botting would obtain copies of the radiographs for our review from Connolly at the University of Liverpool. Copies of the radiographs were subsequently produced in Liverpool and, along with a copy of the videotape of Harrison's 1969 BBC presentation, were made available to Rodin and coauthors R.S. Boyer and T.C. Grey in September 2001 on the day of videotaping the Discovery Channel production.

Review of the Radiographs

Three radiographic copies of the skull and cervical spine of Tutankhamen were provided for our review (Figs 1–3). The copies were in good condition and had satisfactory resolution and contrast to critically examine the skull and its opaque contents as well as the cervical spine. The radiographs were in our possession for only a few hours before filming, and there was no opportunity for us to exchange views before the taped

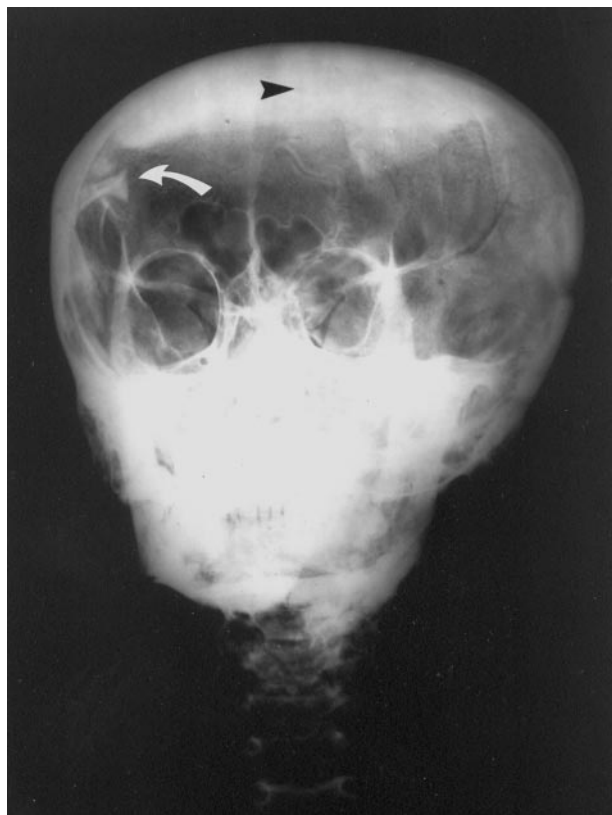

FIG 2. Frontal radiograph of Tutankhamen's skull and cervical spine shows the opaque layer of resin in the vertex region (arrowhead) and the bone fragment (curved arrow). Note that the second fragment is not apparent in this image. (Reprinted courtesy of the University of Liverpool.)

interviews. They were subsequently examined in greater detail by authors Boyer (a pediatric neuroradiologist) and by Grey (a forensic pathologist) in the company of Rodin (a neurologist and epileptologist). The digital images were stored in electronic file format and are available to the interested reader (contact Boyer by e-mail at pcrboyer@ihc.com).

Phantom Study

A skull phantom was radiographed in the lateral projection resting on a sponge ring to simulate the process by which the skull radiographs of Tutankhamen were produced during the 1968 expedition. Slight tilt of the head was created to show the appearance of the posterior fossa when the head is tilted. Images were acquired with a computed radiography system and were archived in an electronic imaging network for review on a workstation.

Video Documentary

The time allotted was insufficient for a detailed examination of the radiographs before the videotaping of the Discovery Channel documentary. This led to the initial assumption by Boyer and Grey that Tutankhamen may have suffered from Klippel-Feil syndrome (7). However, after the videotaping was concluded, subsequent analysis of the radiographs excluded this diagnosis as an acceptable possibility. Most of the authors' observations and conclusions regarding the radiographs were not included in the final video production but are presented herein.

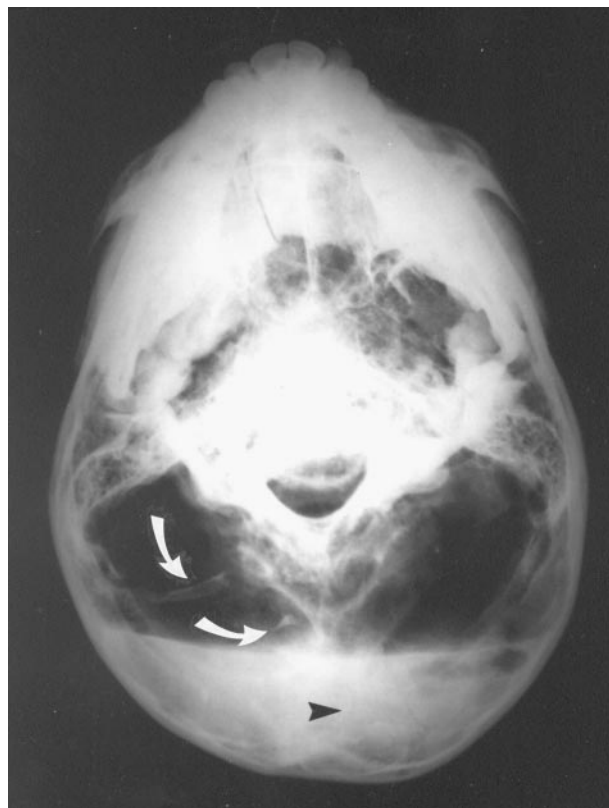


FIG 3. Submental vertex radiograph of Tutankhamen's skull shows the opaque resin layer in the occipital region (arrowhead) and the bone fragments (curved arrows). (Reprinted courtesy of the University of Liverpool.)

Results

Analysis of the Radiographs

Lateral (Fig 1), anteroposterior (Fig 2), and submental vertex (Fig 3) radiographs of the disarticulated skull and cervical spine of Tutankhamen were reviewed. The radiographic images were of sufficient quality to allow a critical appraisal of the skull, spine, and intracranial contents. A digitized print of the lateral view radiograph with contrast reversed (black on white) (Fig 4) showed the two intracranial bone fragments more clearly than did the traditional white on black images.

The cranial-facial proportion appeared appropriate for a young adult male. The calvaria appeared to be intact. No skull fracture was identified. However, as discussed by Harrison (2, 4), two fluid levels were present, which resulted from the resin introduced at the time of embalming. The resin deposits in the vertex and occipital regions of the cranial vault were well seen on the lateral view radiograph (Fig 1). The resin in the vertex was seen on the frontal view radiograph (Fig 2). The sub-mental vertex view showed the resin in the occipital region (Fig 3). The presence of this hardened, opaque resin was actually helpful in understanding and refuting the commonly held theories of skull fracture and subdural hematoma.

Careful inspection of the radiographs showed that there are, in fact, two intracranial bone fragments,

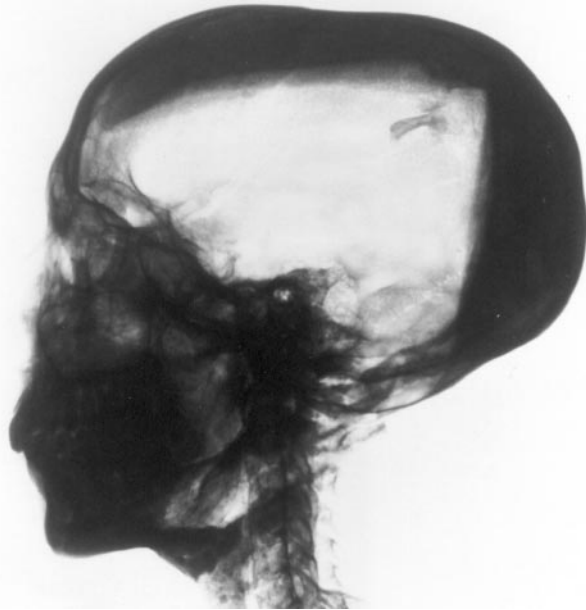

FIG 4. Lateral view radiograph of Tutankhamen's skull and cervical spine with contrast reversed. Intracranial fragments are more conspicuous than on the white on black images. (Reprinted courtesy of the University of Liverpool.)

which are in the right parietal/occipital area, not on the left, as suggested by Harrison. These fragments are separate from the attenuated shadows of the intracranial resin. No other bone fragments or abnormal intracranial contents were detected. The nasal-ethmoid-cribriform plate region appeared to be intact. No fracture or missing parts were noted, in distinction from Harrison's observations. Radio-attenuated material was also seen in both nasal passages. These plugs were placed in the nasal passages to seal the intracranial vault after the embalmers had removed the brain and cauterized the inside of the skull with hot resin, presumably to prevent leakage of resin or liquefied brain. Careful inspection of the bone fragments shown on all three images indicated that the larger of the bone fragments appeared to be a portion of the posterior arch of the first cervical vertebra.

No calcified membrane was seen in the posterior fossa. Two parallel linear opacities in the posterior fossa represented the lateral aspects of the floor of the posterior fossa on which rested the cerebellar hemispheres. Mild tilt of the head on the lateral view radiographs projected the contour of the floor of one side of the posterior fossa above that of the other. A lateral view radiograph of a skull phantom (Fig 5) showed that the parallel lines of the right and left sides of the floor of the posterior fossa project one cephalad to the other when the head was tilted. The appearance of the lateral view radiograph of the phantom was very similar to the appearance of the lateral view radiograph of Tutankhamen, confirming our impression that there was no calcified membrane, as suggested by Brier's consultant (1), but only normal posterior fossa anatomy (except for the resin, as discussed above).

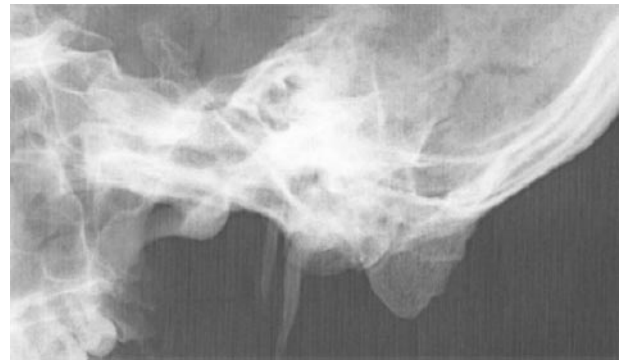

FIG 5. Lateral view radiograph of a slightly tilted skull phantom shows the double contours of the floor of the posterior fossa projecting one cephalad to the other, similar to that seen in the lateral view radiograph of Tutankhamen's skull.

Most of the posterior elements of the upper cervical spine were missing. In addition, there was a continuous beaded-appearing line posterior to the cervical vertebral bodies and disk spaces visible in the lateral view radiograph. The disk spaces were poorly visible, especially in the lateral projection. The cranial-cervical alignment appeared normal. No evidence of platybasia, basilar invagination, cranial-cervical dislocation, cervical spine fracture, or subluxation was observed. No congenital abnormality of the cervical vertebrae or scoliosis was detectable.

Discussion

Intracranial Bone Fragments

Reeves (8) and Brier (1) previously published in the lay literature a photograph of the lateral view radiograph of Tutankhamen showing the bone fragment(s). However, the complete set of three radiographs of Tutankhamen's skull and cervical spine has not been previously published or made available to the scientific community for review. Two bone fragments were noted within the calvaria, a finding not mentioned by other observers. It is not clear why Harrison reported that the fragments were on the left side, when they were clearly on the right. Connolly, a member of the Harrison expedition, confirmed that the markings on the radiographs were correct and that the fragments were thus on the right. If these had been dislodged from the calvaria by a blow causing a skull fracture before death, the fragments would have been imbedded in the resin, which was instilled after death, and hence the fragments would not be visible on the radiographs. Alternatively, it has been suggested that the fragments may have been dislodged in the embalming process, but similar logic applies. Had the embalmers dislodged the fragments, they would have been buried in the resin, which was poured in after the intracranial contents were evacuated. Furthermore, there is no visible donor site in the cribriform plate region, as suggested by Harrison, to suggest a fracture in this region. The nasal plugs placed after instilling the resin were observed to be intact. It is most likely that the fragments were dislodged, not

at the time of embalming but at the time of the autopsy performed by Derry and his associates in 1925. This assumption is supported by a set of radiographs obtained in 1978 by J.E. Harris of the University of Michigan (personal communication). These images showed that the bone fragments were no longer in the superior parietal region but near the base of the skull. The mobility of the fragments within the cranial vault indicated that they were not fixed to the skull or resin but were freely moveable, consistent with postmummification trauma.

The process of mummification of Tutankhamen is typical of that applied by the royal embalmers during the time of the pharaohs. Harris and Weeks (9) and Harris and Wente (10) documented, in two books, the process of extracting the brain from the calvarial vault and partially filling it with a radiopaque resinous material. Several of the royal mummies that they radiographed showed intracranial densities with fluid levels, similar to those seen on the radiographs of Tutankhamen. None of these radiographs showed intracranial bone fragments, consistent with our conclusion that the bone fragments were produced long after the mummification process was complete and the resin was hardened. Likewise, none of the mummies published in these references showed absence of the posterior arch of C1, also consistent with our conclusion that the royal embalmers entered the cranial cavity via a nasal approach, but the approach used by Derry et al was through the foramen magnum, probably introducing fragments of the upper cervical spine into the cranial vault in the process in 1925 (5).

Leek (11), who was also a member of Harrison's team, published additional information regarding Derry's autopsy, which is not available in Carter's book. Leek wrote, "Toward the end of the report, Derry makes two terse observations: first the skull was empty except for some resinous material which was introduced through the nose, and second that the third molar teeth had just erupted the gum."

It is our opinion that because Derry did not have radiographs available, he must have entered the skull with the use of unspecified instruments, creating a sufficiently large window to observe the intracranial vault. This could be more easily achieved through the foramen magnum than through the nose. If the entry was through the foramen magnum, it may well have produced fractures of portions of the upper cervical spine, whereas an entry through the nose could have produced fractures of parts of the nasal, ethmoid, and/or sphenoid bones. This is unlikely, however, because the mentioned plugs in the nasal passages appeared to be undisturbed. Our review of the radiographs indicated that the larger of the bone fragments appeared very similar to the posterior arch of the atlas (C1), which was missing on the radiographs. In our opinion, this observation supports the conclusion that Derry entered the cranial cavity through the foramen magnum, dislodging the posterior arch of C1 in so doing, with the bone fragments then remaining inside the cranial vault where they were radiographed

by Harrison's team. This conclusion is consistent with the report presented by Harrison and Abdalla (4), in which they state, "Some repairs to the head were visible in the form of wax between the atlas and the foramen magnum at the base of the skull, and smooth, recently applied, but solidified, resin under the chin."

Posterior Fossa Bone Thinning

The other observation of Tutankhamen's radiographs that has been used to impute a violent form of closed head trauma as the cause of his death relates to the occipital region on the lateral view radiograph. The reported thinning of the occipital bone can be easily understood by examination of the osseous floor of the posterior cranial fossa. The lateral aspects of the occipital bone expand and thin to accommodate the cerebellar hemispheres, which rest on them. Thinning of the occipital bone in this region is a normal finding. The reason that the thinning appears to be somewhat more pronounced on the lateral view radiograph of Tutankhamen is because the head is somewhat tilted laterally so that one lateral posterior fossa depression projects lower than the other. This tilt of the head also accounts for the horizontal attenuated line seen across the floor of the posterior fossa, thought by a consultant referred to by Brier (1) (who had only a photograph of the radiograph available rather than the actual radiograph) to be a calcified membrane. It is simply one side of the posterior fossa floor projecting above the other. Furthermore, if there were a calcified membrane in the posterior fossa at the time of death, the resin applied postmortem would not have crossed the margin of the membrane, which it obviously does on the lateral view radiograph. No calcified membrane was observed, and no evidence of a subdural hematoma was seen.

Cervical Spine

Likewise, no evidence of injury occurring before death to the cervical spine or the cranial-cervical junction was observed. The resin deposit obscured some of the usual anatomic landmarks in the region of the foramen magnum, but no evidence of basilar invagination or platybasia was seen. The vertebral bodies appeared to be intact and the alignment anatomic. The bright line posterior to the vertebral bodies and the seeming lack of intervertebral spaces on the lateral view radiograph were regarded, at first glance, to be suggestive of juvenile rheumatoid arthritis or Klippel-Feil syndrome. Based on a more detailed examination of the radiographs, this conclusion could not be substantiated. The bright beaded line seen on the lateral view image of the spine posterior to the vertebral bodies and intervertebral disks most likely represents a thin deposit of resin that layered in the anterior portion of the cervical spinal canal, probably in the subdural space. We have observed on MR images of the spine, obtained after posterior fossa surgery, that the cervical subdural space may contain blood and/or CSF. We suspect that the liquid resin

extended from the intracranial vault into the anterior subdural space of the spine, creating the impression of posterior spinous fusion or of a calcified membrane in the region of the posterior longitudinal ligament.

It is also probable that some of the unguents poured over the body at the time of burial were still adherent to the cervical spinous tissues at the time the radiographs were obtained. Burton's photographs taken at the time of the 1925 autopsy show that the cervical spine is rigidly attached to the skull. This can be seen in pictures of Tutankhamen's head presented by Brier (1), Harrison's BBC video documentary (2), Leek's chapters (11), Reeves' book (8), and other publications. The appearance of the spine on the lateral view radiograph that originally suggested congenital or acquired fusion of vertebral bodies, is, therefore, more likely due to the resin that had glued the back of the mummy to the coffin and was removed by Carter's team only to the extent that enabled them to lift out the head. This assumption is also borne out by the report presented by Harrison and Abdalla (4) in 1972 in which it was noted that "in many places black resin still adhered to the rock-hard black tissues."

Conclusion

The radiographs of the skull and cervical spine of Tutankhamen provide no evidence for a depressed skull fracture, a posterior fossa subdural hematoma, or an injury to or congenital malformation of the cervical spine. All previously reported abnormal findings can be accounted for by postmortem artifacts and an understanding of normal skull base anatomy. We have shown that the observation of a curvilinear attenuated line in the posterior fossa does not represent a calcified membrane and can be reproduced with a skull phantom, which is slightly tilted when radiographed. Currently proposed murder theories regarding Tutankhamen's death are not supported by criti-

cal appraisal of the radiographs of the young pharaoh. Because the resin introduced at the time of embalming presents serious obstacles to a definitive evaluation of Tutankhamen's head and neck, it would be interesting to use CT for further investigation. However, the pharaoh's remains reside in his tomb in the Valley of the Kings and cannot readily be moved. Performing such an examination would present a major logistical challenge, which does not seem to be feasible in the foreseeable future. The cause of death of the famous young pharaoh remains enigmatic, but the radiographs of his skull cannot be used to support a theory of homicide.

Acknowledgment

We express appreciation to Kate Botting from Atlantic Productions, Ltd., for assisting in transport of the copies of the radiographs and the BBC videotape between England and the United States.

References

1. Brier B. *The Murder of Tutankhamen: A True Story*. New York: G.P. Putnam's Sons; 1998:172-173
2. *Chronical: Tutankhamen Post Mortem*. Atlantic Productions, Ltd.; TX:25/10/69; VHS/NTSC
3. Harrison RG. **Post mortem on two pharaohs: was Tutankhamen's skull fractured?** *Buried History* 1971;4:114-129
4. Harrison RG, Abdalla AB. **The remains of Tutankhamun**. *Antiquity* 1972;46:8-14
5. Carter H. *The Tomb of Tutankhamen*. London: Century Publishing; 1983:197-222, 310-319, 321-332
6. Vandenberg P. *Nofretete, Echnaton und ihre Zeit*. Klagenfurt: Neuer Kaiser Verlag; 232
7. Atlantic Productions, Ltd. **Assassination of King Tut**. *Discovery Channel Video* 675231; 2002
8. Reeves N. *The Complete Tutankhamun*. London: Thames & Hudson Ltd.; 1960:118
9. Harris JE, Weeks KR. *X-raying the Pharaohs*. New York: Charles Scribner's Sons; 1973:44
10. Harris JE, Wente EF. *An X-ray Atlas of the Royal Mummies*. Chicago: The University of Chicago Press; 1980:183
11. Leek FF. *The Human Remains from the Tomb of Tutankhamun*. London: Oxford University Press; 1972:3-6, 16-19