



Providing Choice & Value

Generic CT and MRI Contrast Agents



**FRESENIUS
KABI**

CONTACT REP

AJNR

Neuroimaging: Clinical and Physical Principles

AJNR Am J Neuroradiol 2003, 24 (5) 1020-1021
<http://www.ajnr.org/content/24/5/1020>

This information is current as
of July 29, 2025.

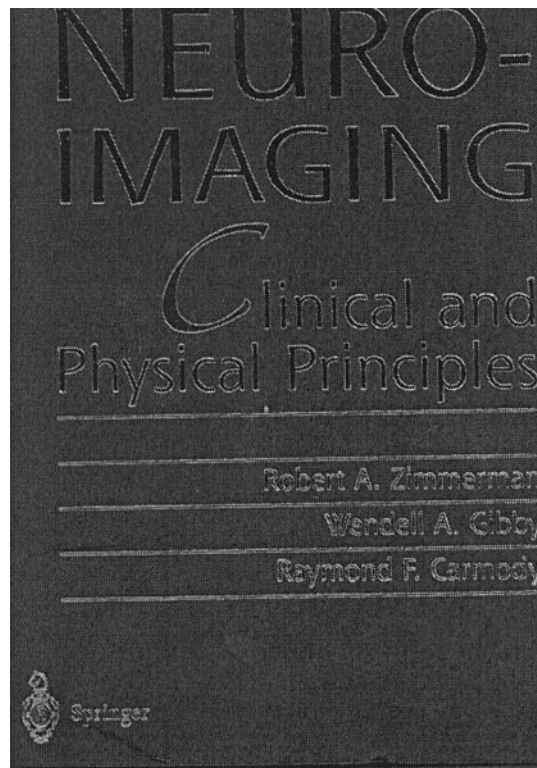
Neuroimaging: Clinical and Physical Principles

Robert A. Zimmerman, Wendell A. Gibby, and Raymond F. Carmody, eds. New York: Springer; 1999 (reprinted 2000 and 2001). 1656 pages, 1621 illustrations. ISBN: 0387949631.

Neuroimaging: Clinical and Physical Principles, edited by Zimmerman, Gibby, and Carmody (1997; reprinted 2000), provides a solid, comprehensive overview of *all* of neuroradiology. This book is big. With 38 chapters covering CT and MR physics, normal anatomy, adult and pediatric brain and skull, orbits and sinuses and skull base, and spine—not to mention appendices on pediatric sedation and nuclear imaging—the overall impression is one of breadth (with varying degrees of depth, depending on the particular chapter's author). Indeed, perhaps the most significant shortcoming of this multiauthored text is its failure to meet its own, self-imposed goal—as stated in the preface—of providing “a *concise* [reviewer's italics] yet thorough overview of neuroradiology.” Weighing in at 4.8 kg, with 1675 well-illustrated pages (including index), it is a weightier tome than its close cousin, the 4.6-kg, 1642-page second edition of *Magnetic Resonance Imaging of the Brain and Spine*, edited by Atlas (Lippincott-Raven, 1996).

Comparison to the second—and not the most recent third—edition of the Atlas textbook is intentional, as both were originally published more than 5 years ago, a lifetime in the rapidly changing world of MR hardware and pulse sequences. Because the first 10 chapters of *Neuroimaging: Clinical and Physical Principles* are essentially a freestanding “textbook within a textbook” on MR and CT imaging, authored solely by Gibby, the age of the manuscript is an important consideration. Not surprisingly, discussion of multisession CT scanning technology is completely lacking, and discussion of advanced MR techniques—such as diffusion, perfusion, spectroscopy, and functional MR imaging—is cursory or absent. Volume rendering is conspicuously missing from the description of image reconstruction techniques. Newer MR and CT contrast agents, as well as CT perfusion imaging, also get short shrift.

Moreover, although the background chapters covering MR and CT physics provide superb technical expertise with regard to the fundamentals, they are often verbose and lack a focused outline format or “take-home” message. For example, chapter 2 would have been easier for the reader to follow had the paragraphs dealing with ionic versus nonionic CT contrast been labeled as such. Similarly, the “pearl” that CT image gray scale is proportional to tissue attenuation appears buried in the text after a three-page discussion. Almost paradoxically, the judicious use of a few equations or precise scientific terminology may have contributed to the text being more, rather than less, simplified; sometimes an equation, like a picture, can be worth a thousand words. On page 210, for example, the relationship $SI_{DWI} = SI_{T2}$



• $e^{-b \cdot ADC}$ (where SI_{DWI} is the diffusion-weighted image signal intensity, SI_{T2} is the T2-weighted image signal intensity, b is the strength of the diffusion gradient, and ADC is the apparent diffusion coefficient) could have been used to concisely convey the concept and determinants of “T2 shine-through.” On page 314, the “simple” statement that the T1 shortening effect of gadolinium is mediated through a dipole-dipole interaction requiring close molecular proximity could similarly have been used to more precisely explain the mechanism of gadolinium enhancement relative to the blood-brain barrier. Having said all this, it should be noted that most of the background physics section is excellent. The discussion of MR imaging artifacts (chap 8, pp 277–311) is well illustrated and clinically relevant, as are the discussions of MR imaging safety (p 153) and radio-frequency coils (p 134).

The clinical chapters might also have benefited from more generous use of summary charts, tables, “pearls,” and mnemonics. The importance of the “swirl sign” (p 704) as a CT marker for a rapidly expanding extra-axial hematoma requiring urgent intervention gets lost in the text. The same is true for the importance of susceptibility and diffusion-weighted MR imaging in the detection and diagnosis

of diffuse axonal injury following trauma (p 723). In the head and neck section, the differential diagnosis of otosclerosis could have been pithily summarized as including osteogenesis imperfecta, Paget disease, and syphilis (p 1190). A notable exception to this—again not surprisingly, given Zimmerman's special expertise in pediatric neuroimaging—is chapter 14, on perinatal injury. This is a model chapter: well illustrated, well referenced, and well outlined, with plenty of useful charts and tables, including a list of the various perinatal insults organized by time, post conception. In light of the varied backgrounds and proficiencies of the individual authors, as well as the “mind-numbing complexity of a book of this scope” [to quote the preface], it is perhaps inevitable that significant variations in style and content of the chapters exist. It is noteworthy that one of the best chapters (chap 23, on interventional neuroradiology)—despite new advances since its publication—was written not by seasoned investigators, but by two neuroradiology fellows!

Although clinical material does not age nearly as quickly as technical material, some of the clinical sections would also clearly benefit from an update. This is particularly true of chapter 20, covering stroke. The goal of modern, advanced imaging of acute stroke is the appropriate selection of patients for intravenous or intra-arterial thrombolytic therapy, a point not sufficiently emphasized or explicated. Moreover, the statement on page 781, that in the early stages of stroke “usually encompassing the first 24 hours, the CT scan is usually normal or nearly normal,” is now known to be false. These observations, however, should not detract from what is otherwise a well-written, comprehensive chapter. To the authors' credit, there is even mention of CT infarct “fogging effect” (table 20, p 784, and Fig 20.24, p 788), an important phenomenon often overlooked in neuroradiology textbooks. Similarly, despite an entire chapter on MR angiography and flow imaging (chap 6), only passing mention is made of the clinical workup of carotid artery occlusive disease vis-à-vis the North American Symptomatic Carotid Endarterectomy Trial (p 199).

One of the great strengths of this textbook is the quality of its clinical figures. With few exceptions, they are excellent, clinically relevant, and provide the

reader with a terrific occasion for radiology board or certificate-of-added qualification review. One of the great disappointments of this textbook is the limited scope of part 3, on normal anatomy and variants. This section consists of only a single chapter on normal *variations*, which, although well illustrated and of high quality, does not live up to the promise of the title by first reviewing *basic* normal anatomy—a noteworthy limitation in a textbook whose stated aim is to offer a comprehensive survey of neuroradiology. Other chapters, however, do in part compensate for this. The illustrations of temporal bone anatomy, for example, in chapter 29, are superb.

Finally—admittedly a minor criticism—appendix B seems misplaced. Why wasn't this chapter covering neuroimaging and nuclear medicine included with the other technical chapters on CT and MR imaging? As with much of this textbook, this chapter once more opts for breadth over depth; for example, the controversy surrounding the value of PET scanning in differentiating recurrent glioma from postradiation changes is not addressed.

Neuroimaging: Clinical and Physical Principles is a good, *big* book; I would definitely recommend it as a worthy addition to the well-stocked neuroradiology library. Perhaps this book's greatest value is as a supplemental reference for both general attending radiologists and neuroradiology fellows studying for their CAQ examinations (who will most appreciate its well-illustrated clinical cases). It is unfortunate, however, that numerous factors—notably its overly broad scope and dated technical chapters—limit the usefulness of this book as a primary teaching text for medical students and beginning radiology residents. For this group, I continue to suggest the concise yet comprehensive introductory text, *Neuroradiology: The Requisites*, by Grossman and Yousem. Like Osborne's “Neuroradiology,” “The Requisites” is teeming with succinct, no-nonsense charts, tables, and take-home messages (not to mention the more than occasional cheap joke). Indeed, it's too bad that *Neuroimaging: Clinical and Physical Principles*—unlike the svelte *Requisites*—must be left at the office each evening; it really does weigh far too much to be carried daily from home to work and back!