



Discover Generics

Cost-Effective CT & MRI Contrast Agents



FRESENIUS
KABI

WATCH VIDEO

AJNR

Functional Cerebral SPECT and PET Imaging

AJNR Am J Neuroradiol 2003, 24 (4) 772-773
<http://www.ajnr.org/content/24/4/772>

This information is current as
of June 3, 2025.

Functional Cerebral SPECT and PET Imaging

Ronald L. Van Heertum and Ronald S. Tikofsky, eds. 3rd ed. Baltimore, MD: Lippincott Williams & Wilkins; 2000. 336 pages, 474 illustrations. \$159.

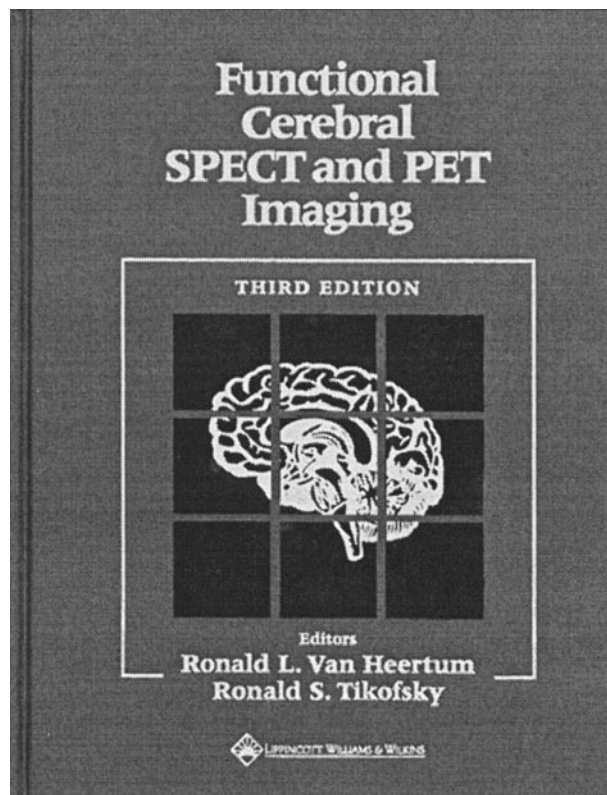
Brain imaging is still evolving decades since positron emission tomography (PET) was introduced as the best functional study. Although MR imaging and, to a lesser extent, CT are the anatomic best imaging methods, for functional imaging in clinical practice, the turf is still contested. Single photon emission CT (SPECT) and PET provide such a means, although functional MR imaging has expanded for this role. In such evolving clinical applications, any serious contribution to the literature is needed and should be appreciated.

Functional Cerebral SPECT and PET Imaging aims at providing useful information to the clinician. After four introductory chapters, the book addresses the potential clinical indications for SPECT/PET separately. The next six chapters offer cases for cerebrovascular disorders, dementias, seizures, trauma, psychiatric disorders, and tumors; to the last chapter, activation and some special cases were attached. Each topic/indication is preceded by a concise clinical and imaging review, with a literature review up to 1998 (plus a few from 1999). It continues with a number of case reports didactically set with clinical presentation and correlative imaging, the SPECT or PET study, with findings and comments, and a useful "teaching point" for most of the cases. It is a successful presentation of most of the cases, which makes the book attractive.

The topic of SPECT is generally covered well, from M. Devous' wonderful introduction to the regional cerebral blood flow studies and a number of thallium (some MIBI) cases. Radioactive amino acid imaging and somatostatin receptor imaging are not included.

The topic of PET is covered only partially. The introduction is based on the old concepts of BGO and NaI crystals and does not provide information regarding radiopharmaceuticals and clinical/research indications/utilization. A limited number of PET cases, mostly fluorine-18-fluorodeoxyglucose, are included in the clinical chapters, and few receptor studies are offered. The vast topic of PET brain imaging is hardly addressed. Considering the quality of images, a good number of cases are well acquired and reproduced for the book; however, a large number of cases are inferior in quality, either because of acquisition reasons (equipment, patient conditions, motion) or selection and reproduction. Considering the clinical significance of the cases, most are well presented and documented and their importance is evident. A large number are marginal with questionable teaching significance.

Chapter 1 presents a good review of the SPECT issues. It is well balanced and includes what is needed



regarding physics, instrumentation, radiopharmacy, and even clinical applications of SPECT.

Chapter 2, the introduction on PET, is selective and not complete. It does not address the new developments (new crystals, fusion, quantitation). It does not mention anything about radiopharmaceuticals or clinical applications, as does Chapter 1 on SPECT.

Chapter 3 is informative, and in their discussion, the authors indicate not to use SPECT/PET for anatomic imaging. However, their selection of images 3-10 through 3-12 as representing the state of the art is not justified. These images do not represent the current normal SPECT scans. The "normal volunteer" cases, presented next, are much better.

Chapter 4 is informative to some extent for the readers of this book. The literature review stops at 1991.

Chapter 5 offers a generous concentration of clinical cases related to cerebrovascular disease. It seems that the authors favored variety rather than quality of images/cases. Most cases are well depicted and include satisfactory images. A few cases are of very low quality, hardly contributing to the teaching value of the chapter. A critical review with sensitivity, specificity, and suggestions for clinical use is missing. Ex-

pert opinion explaining why SPECT or PET is not widely used in cases of cerebrovascular disease in clinical practice is missing.

Chapter 6 deals with dementias, and it is complete and informative. A large number of cases, however, are not optimally reproduced (Cases 3–5, 9, 13, 14, 16, 25, 27–29, and 40). One wonders whether instrumentation failure or patient motion occurred or whether the cause was selection and reproduction. In a case of AIDS-related lymphoma (case 33), the PET-fluorine-18-fluorodeoxyglucose study intended to be diagnostic of a tumor should have been performed 7 to 10 days into the treatment of toxoplasmosis.

Chapter 7, on seizures, has an incomplete introduction. Unless the reader is a specialist, this chapter needs good classification, including a table. The cases are well depicted, although some images are not of the best quality (images 21–24).

Chapter 8, on trauma, includes a good introduction and some good examples. The issue of lack of proved correlation between minor brain trauma diagnosed by SPECT or PET and clinical outcome need greater discussion, because it is critical for clinical indications of the tests.

Chapter 9 begins with a concise review of psychiatric applications of SPECT and PET and presents contradictory results. No conclusion is provided other than a statement, “It seems feasible that future psy-

chiatric diagnostic criteria may include neuroimaging data.” The quality of images of cases 1 through 3 and the questionable significance of cases 6, 9, and 12 cannot support any more optimistic conclusion, although cases 5, 7, and 8 are of good quality.

In a surprise conclusion, brain tumors are summed up in Chapter 10. Some rare cases and activations are presented. Good examples of tumor imaging with thallium (MIBI), fluorine-18-fluorodeoxyglucose, and hexametzime or hexamethylpropyleneamine oxime (meningiomas) are included. Missing are protein synthesis, DNA synthesis, amino acid uptake, and other imaging with PET (and SPECT) and somatostatin receptor imaging. The quality of images is generally acceptable (except in case 13), although questionable findings were reported in cases 14 and 18 through 21. The activation studies are interesting and provide a glimpse into their applications. The clinical indications for tumor SPECT/PET are partially tackled. Preoperative tissue characterization is well presented; differentiation of tumor from infection is less well presented. Therapy planning, evaluation of effectiveness of treatment, diagnosis of recurrence, and functional brain mapping were not addressed.

In conclusion, the book makes an effort to address the issue of SPECT and (less so) of PET imaging of the brain. The results are only modest.