



Discover Generics

Cost-Effective CT & MRI Contrast Agents

 FRESENIUS
KABI

[WATCH VIDEO](#)

AJNR

Developmental Delay in Children: Assessment with Proton MR Spectroscopy

Christopher G. Filippi, Aziz M. Ulug, Michael D. F. Deck, Robert D. Zimmerman and Linda A. Heier

AJNR Am J Neuroradiol 2002, 23 (5) 882-888

<http://www.ajnr.org/content/23/5/882>

This information is current as of June 23, 2025.

Developmental Delay in Children: Assessment with Proton MR Spectroscopy

Christopher G. Filippi, Aziz M. Uluğ, Michael D. F. Deck, Robert D. Zimmerman, and Linda A. Heier

BACKGROUND AND PURPOSE: The cause of developmental delay frequently is unknown, and clinicians and families can be frustrated by the lack of neuroimaging correlation especially when considering therapeutic options and long-term prognosis. We sought to determine if proton MR spectroscopy can depict abnormalities in patients with developmental delay who have structurally normal brain MR images.

METHODS: Children with developmental delay who were older than 2 years (mean age, 5.0 years; range, 3.0–10.0 years) and those aged 2 years or younger (mean age, 1.5 years; range, 0.5–2.0 years) and age-matched control subjects for each patient group underwent brain MR imaging and proton MR spectroscopy. A point-resolved spectroscopy sequence (2000/144 [TR/TE]) was used. Voxels (8 cm³) were placed in the subcortical white matter of the frontal and parieto-occipital lobes bilaterally. *N*-acetylaspartate (NAA)/creatine (Cr) and choline (Cho)/Cr ratios were assessed.

RESULTS: All patients had normal brain MR images. In children with developmental delay who were aged 2 years or younger, no statistically significant differences were detected in the NAA/Cr or Cho/Cr ratios compared with those of the control subjects. In children with developmental delay who were older than 2 years, decreases in the NAA/Cr ratio were observed in frontal ($P < .001$) and parieto-occipital ($P < .017$) subcortical white matter, and elevations in the Cho/Cr ratio were detected in the frontal ($P < .24$) and parieto-occipital ($P < .002$) subcortical white matter compared with age-matched control subjects.

CONCLUSIONS: In children with developmental delay who are older than 2 years, proton MR spectroscopy depicted abnormalities in the NAA/Cr and Cho/Cr ratios. Proton MR spectroscopy should be performed as part of the neuroimaging evaluation of developmental delay. Further studies will be needed to determine if abnormalities detected with proton MR spectroscopy can be used as a diagnostic tool and neuroimaging marker to assess long-term functional outcome.

MR imaging is an important part of the comprehensive evaluation of children with developmental delay, as many specific etiologic and pathophysiologic conditions that lead to developmental delay can be detected easily (1–7). However, children with mild neurodevelopmental delay frequently have normal brain MR imaging examinations, and approximately 15% of

school-aged children have some form of mild developmental delay (5, 7).

Investigators have used proton MR spectroscopy, an emerging MR imaging modality, in children to study neurodegenerative disorders, epilepsy, metabolic disorders, and pediatric neuropsychiatric disorders (8–15). Clinicians have used proton MR spectroscopy to predict outcome in children with acquired brain injuries such as perinatal asphyxia and hypoxic-ischemic encephalopathy (16–22). Whereas MR imaging has been used to examine the normal patterns of brain myelination (23–27), more recently proton MR spectroscopy has been used to further assess normal myelin maturation in children (28–32).

Using proton MR spectroscopy, investigators have studied children who had abnormal brain MR images and/or were at high risk for developmental delay (8, 30, 33). Changes in choline (Cho) levels in children with developmental delay have been attributed to the

Received March 20, 2001; accepted after revision January 7, 2002.

From the Department of Radiology, New York Presbyterian Hospital-Weill Medical College of Cornell University, New York.

Presented at the 38th annual meeting of the American Society of Neuroradiology, 2000, Atlanta, GA.

Address reprint requests to Christopher G. Filippi, MD, New York Presbyterian Hospital-Weill Medical College of Cornell University, Department of Radiology, Box 141, 525 E 68th St, New York, NY 10021.

availability of precursor molecules needed for myelination (10, 34). Normally, the Cho/creatine (Cr) ratio declines rapidly in the first few months of life owing to accelerated myelination, which incorporates Cho into macromolecules associated with myelin (29). In development, as myelination proceeds normally, there is a rise in *N*-acetylaspartate (NAA) levels, which may correspond to dendritic proliferation or increased synaptic density (10, 34, 35). Conditions in children that lead to neuronal injury, neuronal loss, or poor functional outcome have been associated with decreased NAA levels (34–36). NAA, which is only found within mitochondria in neurons, is considered a neuronal marker. The results of these studies suggest the potentially important role of proton MR spectroscopy in the assessment of children with developmental delay. Variations in the NAA/Cr and Cho/Cr ratios in these children may reflect underlying abnormalities of myelination or hypomyelination (10, 34).

In this study, we investigated proton MR spectroscopy in children with the mildest form of neurodevelopmental delay, who had normal brain MR images. We hypothesized that proton MR spectroscopy would enable detection of abnormalities in the NAA/Cr ratios and Cho/Cr ratios in the frontal and parieto-occipital subcortical white matter of children with developmental delay. Information regarding the magnitude and severity of any observed neurometabolic alterations in the NAA/Cr and Cho/Cr ratios may be valuable in understanding the pathophysiology of developmental delay or in assessing the long-term functional outcome in these children.

Methods

During a 1-year period (October 1, 1998 to October 1, 1999), 14 children with developmental delay were studied prospectively with routine MR imaging and MR spectroscopy. A control group that comprised 12 children with normal MR imaging and MR spectroscopic examinations was included for comparison. Since the signal changes of myelin maturation near completion by the end of the 2nd year of development, we chose to examine children with developmental delay who were older than 2 years as one group and those aged 2 years or younger as another group. Children older than 2 years with developmental delay (four boys, three girls; mean age, 5.0 years; age range, 3.0–10.0 years) were compared with age-matched control subjects (three boys, three girls; mean age, 5.7 years; age range 3.0–10.0 years). Children aged 2 years or younger with developmental delay (three boys, four girls; mean age, 1.5 years; age range 0.5–2.0 years) were compared with age-matched control subjects (three boys, three girls; mean age, 1.0 year; age range, 0.5–2.0 years).

All participants had nonfocal neurologic examinations, no psychiatric history, and no noteworthy medical history. Patients who had normal MR imaging findings and normal results on all laboratory tests including blood and CSF tests were considered to be healthy control subjects; MR spectra from these patients were consistent with published data (31) and used as control data. However, all control subjects had been referred for MR imaging because of headache ($n = 2$), migraine ($n = 1$), or rule out seizure ($n = 9$), and imaging was performed to exclude a seizure focus. After medical evaluation, none of these patients was considered to have a seizure disorder. Follow-up MR imaging had not been obtained in the children with developmental delay at the time of this writing.

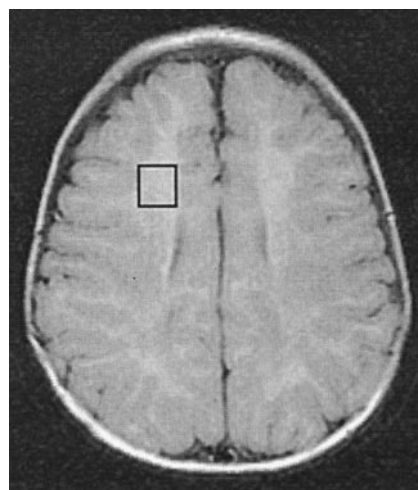


Fig 1. PRESS image (2000/144/8) demonstrates voxel placement in the frontal subcortical white matter (box). Voxels were used to assess NAA/Cr ratios and Cho/Cr ratios.

All participants were studied with a 1.5-T whole-body MR imager (GE Echosped, General Electric, Milwaukee, WI) equipped with high-performance gradients, using a manufacturer-supplied quadrature head coil. Routine sequences performed in all children were sagittal T1-weighted (300/14/1 [TR/TE/excitations]), axial fast spin-echo T2-weighted (3000/91/1), axial fast fluid-attenuated inversion recovery (FLAIR) (10,002/172/1, TI 2.2 seconds), and axial T1-weighted (500/14/1). In general, all axial sequences used 5-mm thickness with intersection gap of 2.5 mm, a 256×192 matrix, the same imaging angle along the orbitomeatal line, and a 22- or 24-cm field of view. Coronal fast FLAIR (10,002/172/1, TI 2.2 seconds) and coronal spoiled gradient recalled acquisition in the steady state (SPGR) T1-weighted volumetric (17/5/1, flip angle 45°) sequences were obtained in 12 of the 26 children. No contrast material was administered for any sequence. Thirteen children were sedated with chloral hydrate 50 mg/kg.

The diagnosis of developmental delay was made by a pediatric neurologist, who referred these patients for brain MR imaging to exclude a structural cause for the developmental delay. The diagnosis of developmental delay was made if a child failed to meet one or more normal developmental milestones in terms of speech and language skills, motor skills, behavioral development, or learning.

Premature infants; children with neurocutaneous syndromes, metabolic disorders, or genetic syndromes; and children with mental retardation, autism, pervasive developmental delay, or cerebral palsy were excluded. The patient population was restricted to those children with isolated developmental delay with no known cause and with normal-appearing MR images on a macroscopic or structural level.

Proton MR spectroscopy was performed in all patients by using a point-resolved spectroscopy (PRESS) sequence (2000/144 [TR/TE]) with 128 averages; voxel sizes of 8.0 cm^3 were used. Voxels were placed in the frontal and parieto-occipital subcortical white matter bilaterally (Fig 1). Although voxels were predominantly centered within subcortical white matter, frontal lobe voxels did encompass cortex medially at the level of the anterior interhemispheric fissure, and voxels placed within parieto-occipital subcortical white matter encompassed cortex of the medial occipital lobe and parietal lobe. Typical acquisition time was 5 minutes 4 seconds per spectral acquisition (20 minutes for all four). For each patient, two authors (CGF, AMU) assessed whether the spectra were diagnostic. Short TE proton MR spectroscopy was not performed for several reasons: time constraints, as the single-voxel long TE spectra added 20 minutes to the routine imaging; our own experience

TABLE 1: MR spectroscopic results for the group aged 2 years or younger

Ratio and Voxel	Patients with Developmental Delay (n = 7)	Control Subjects (n = 6)	P Value
NAA/Cr			
Frontal subcortical white matter	2.11 \pm 0.14	2.09 \pm 0.45	NS
Parieto-occipital subcortical white matter	2.08 \pm 0.21	1.93 \pm 0.39	NS
Cho/Cr			
Frontal subcortical white matter	1.73 \pm 0.16	1.84 \pm 0.27	NS
Parieto-occipital subcortical white matter	1.60 \pm 0.21	1.76 \pm 0.23	NS

Note.—Data are the mean \pm standard deviation. NS indicates not statistically significant.

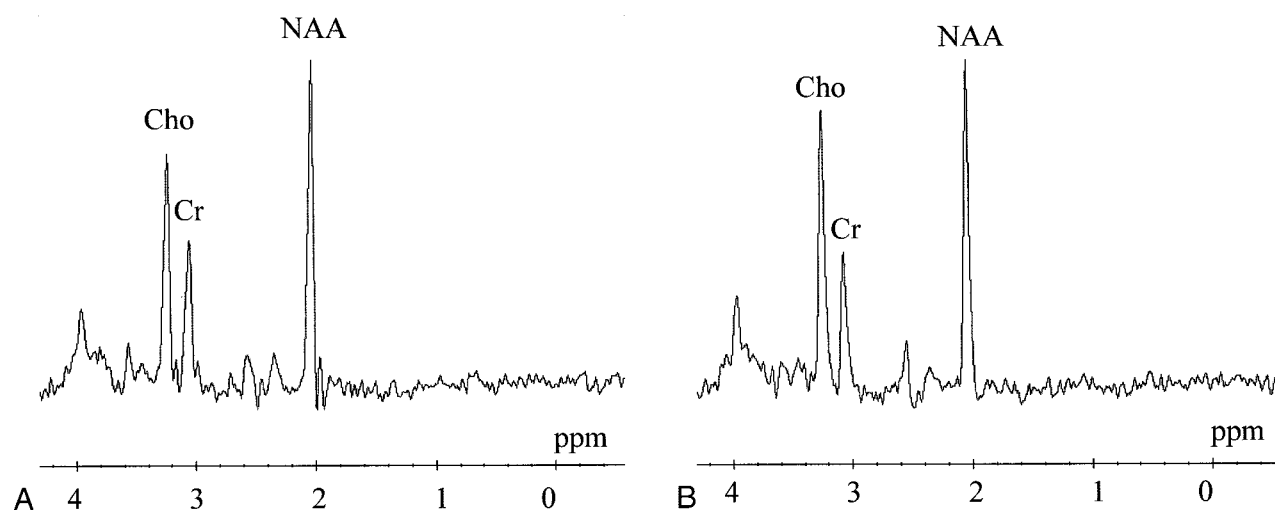


Fig 2. Comparison of patient and control spectra in the group aged 2 years or younger.

A, Proton MR spectrum in left frontal white matter in a 1.5-year-old control subject demonstrates an NAA/Cr ratio of 2.12 and a Cho/Cr ratio of 1.81.

B, Proton MR spectrum from a voxel placed in the subcortical white matter of the left frontal lobe in a 1.5-year-old patient with mild developmental delay demonstrates a slightly higher Cho peak and higher Cho/Cr ratio of 2.01. This value, however, was not significantly different than that in the 1.5-year-old control subject. Likewise, the NAA peak is slightly lower and the NAA/Cr ratio of 1.94 is less than that in the control subject but not significantly different.

in having always used long TE MR spectroscopy in children, which includes normative data collection, which we have not obtained in children by using short TE proton MR spectroscopy; and relative ease for lactate peak detection and its more precise estimation without superimposed fat peaks (15).

The NAA/Cr and Cho/Cr ratios at MR spectroscopy were analyzed without clinical knowledge regarding the participants. The mean values of the NAA/Cr and Cho/Cr ratios in the children with developmental delay were compared with the values obtained in the control children by using a 2-tailed Student *t* test, assuming unequal variance, and using a *P* level of less than .05 for significance.

Results

In the control children aged 2 years or younger, the NAA/Cr ratios in the frontal and parieto-occipital subcortical white matter were $2.09 \pm .45$ and $1.93 \pm .39$, respectively. Among children with neurodevelopmental delay in this age group, similar values were recorded. The NAA/Cr ratio in the frontal subcortical white matter was 2.11 ± 0.14 and in the parieto-occipital subcortical white matter was $2.08 \pm .21$. There were no statistically significant differences between these groups (Table 1, Fig 2).

Similarly, no statistically significant differences were noted in the Cho/Cr ratios (Table 1, Fig 2). The

control children aged 2 years or younger had mean Cho/Cr ratios of 1.84 ± 0.27 in frontal subcortical white matter and $1.76 \pm .23$ in the parieto-occipital white matter. Children with developmental delay in this age group had similar values: 1.73 ± 0.16 in the frontal white matter and $1.60 \pm .21$ in the parieto-occipital white matter.

Control children older than 2 years had MR spectra resembling those of healthy adults, with NAA/Cr values of 2.53 ± 0.15 in the frontal subcortical white matter and 2.44 ± 0.21 in the parieto-occipital subcortical white matter. Compared with the control spectra, the proton MR spectra of the children with developmental delay in this age group were significantly different, with much smaller NAA peaks and decreased values of the NAA/Cr ratios in both the frontal and parieto-occipital subcortical white matter (Table 2, Fig 3). On average, the NAA/Cr ratio in the frontal white matter was decreased to 2.14 ± 0.10 ($P < .001$) compared with that of the control patients and decreased to 2.06 ± 0.29 ($P < .017$) in the parieto-occipital white matter.

Similarly, a statistically significant difference was noted in the Cho/Cr ratios between the children in the older age group. Control children older than 2

TABLE 2: MR Spectroscopic results for the group older than 2 years

Ratio and Voxel	Patients with Developmental Delay (n = 7)	Control Subjects (n = 6)	P Value
NAA/Cr			
Frontal subcortical white matter	2.14 \pm 0.10	2.53 \pm 0.15	<.001
Parieto-occipital subcortical white matter	2.06 \pm 0.29	2.44 \pm 0.21	<.017
Cho/Cr			
Frontal subcortical white matter	1.65 \pm 0.22	1.37 \pm 0.19	<.024
Parieto-occipital subcortical white matter	1.76 \pm 0.23	1.36 \pm 0.14	<.002

Note.—Data are the mean \pm standard deviation.

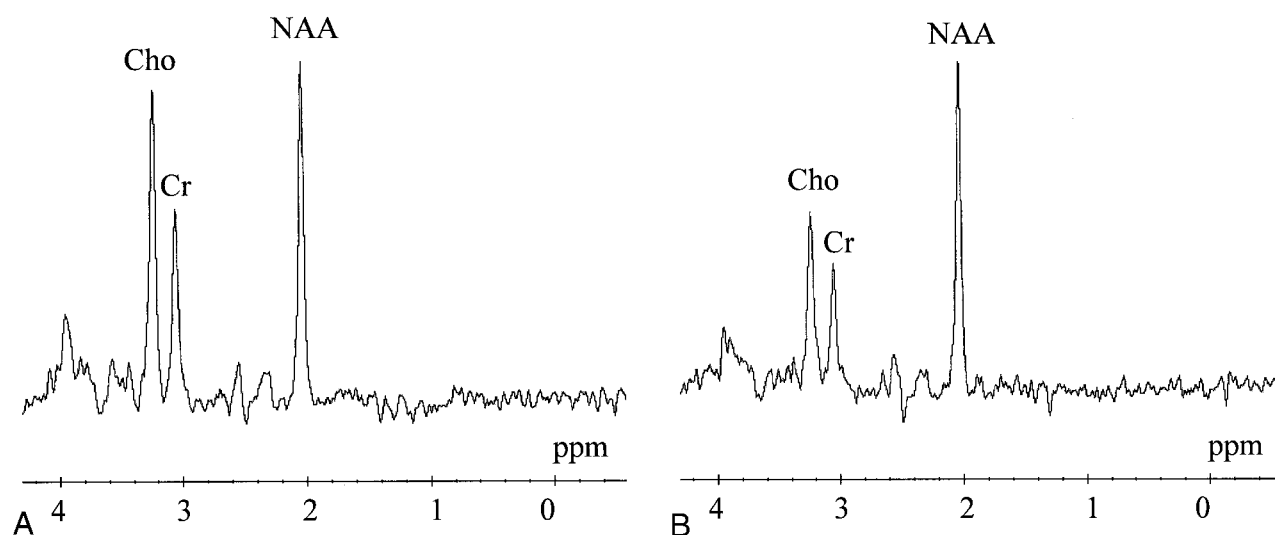


FIG 3. Comparison of patient and control spectra in the frontal lobe subcortical white matter in the group aged older than 2 years.

A, Proton MR spectrum in a 5-year-old patient with mild developmental delay in language and coordination demonstrates marked increase in the Cho/Cr ratio to 1.79. There is a decrease in the NAA/Cr ratio to 2.06, which resembles the MR spectrum of a much younger child such as seen in the 1.5-year-old children in Fig 2.

B, Proton MR spectrum in a 5-year-old control patient demonstrates a pattern resembling that of an adult, with an NAA peak that is 2 times higher than the Cr peak and a Cho peak that is slightly elevated compared with the Cr peak. The NAA/Cr ratio of 2.50 and Cho/Cr ratio of 1.42 are normal.

years had Cho/Cr ratios of $1.37 \pm .19$ in the frontal subcortical white matter and 1.36 ± 0.14 in the parieto-occipital white matter. Children with developmental delay in this age group had larger Cho peaks and higher Cho/Cr ratios, specifically, mean Cho/Cr ratios of 1.65 ± 0.22 ($P < .024$) in the frontal subcortical white matter and 1.76 ± 0.23 ($P < .002$) in the parieto-occipital white matter (Table 2, Fig 3).

Discussion

In this study, we specifically chose to investigate children with mild developmental delay with no known predisposing etiologic or pathophysiologic condition and who had normal brain MR imaging examinations. Approximately 15% of school-aged children are believed to have some form of mild neurodevelopmental delay (5, 7). In these cases of mild developmental delay, a definite cause is rarely established, and these cases may represent the lower portion of the normal bell curve distribution of intellectual development (4). The lack of neuroimaging findings can frustrate clinicians and parents alike, especially when therapeutic intervention and long-term prognosis are considered.

We chose to study these patients with proton MR spectroscopy because this emerging noninvasive MR modality is now in more routine clinical use and provides unique information regarding in vivo brain metabolism and neuronal function. Investigators have used proton MR spectroscopy to assess brain maturation and white matter development in healthy children (25, 29, 31, 32). After birth, the brain undergoes major developmental changes including neuronal organization, proliferation and differentiation of glial cells, and myelination (25). The infant brain has a higher water content than does the adult brain, but the water content rapidly decreases over the first few months of life. Autopsy studies (37, 38) and quantitative in vivo MR spectroscopic studies (29) have documented this. As cerebral maturation proceeds, NAA levels rise (29). The NAA/Cr ratio increases rapidly from age 1 month to age 1 or 2 years (25, 30, 32). In infants, the Cho/Cr ratio is higher than that of adults. The Cho/Cr ratio declines rapidly from ages 1 month to 1 year, then declines more slowly until age 2 years (25, 31, 32).

NAA, which is present in neuronal cells and made in mitochondria, is considered to be a marker for neuronal

development. It is the most sensitive central nervous system metabolite, and neuronal damage or loss will result in decreased NAA levels (11). In the current study, all children older than 2 years with mild developmental delay had markedly abnormal proton MR spectra compared with those of the control children. The abnormal proton MR spectra resembled those of healthy children much younger than 2 years (Fig 3). All these children had statistically significant decreases in the NAA/Cr ratio ($P < .001$ in frontal white matter and $P < .017$ in parieto-occipital white matter). We hypothesize that children with developmental delay and normal brain MR images may have hypomyelination or decreased synaptic density as an underlying cause, which was detected with proton MR spectroscopy but missed with routine MR imaging. If there is a decreased NAA/Cr ratio owing to damaged myelin, loss of normal myelin, or decreased numbers of normal neurons, this could be occult to routine MR imaging and still detectable with proton MR spectroscopy.

Cho, which is a membrane component, has been used to infer information about myelination and cell membrane turnover (11, 14, 15, 39). It has been thought of as a membrane stability marker because Cho is a structural component of all cell membranes, including myelin (11, 12). Changes in Cho levels in children with developmental delay have been attributed to the availability of precursor molecules needed for myelination (10, 34). The decrease in the Cho/Cr ratio that is normally observed in the first few months of life is due to accelerated myelination, which incorporates Cho into macromolecules associated with myelin (29).

In the current study, all children with developmental delay who were older than 2 years had statistically significant elevations in the Cho/Cr ratio ($P < .024$ in frontal white matter and $P < .002$ in parieto-occipital white matter). During the first 2 years of life, there should be a rapid decline in the Cho/Cr ratio, and the proton MR spectra of children older than 2 years should begin to resemble that of healthy adults. The observed increase in the Cho/Cr ratio, which we detected in children with developmental delay who were older than 2 years, may reflect an inability to properly incorporate Cho-containing molecules into myelin, which would not likely be detected on routine MR images as a signal intensity abnormality. Other explanations are possible including loss or disruption of normal myelin, which would increase the availability of such Cho-containing compounds, which has been observed in dysmyelinating disorders (40) and the acute stages of demyelinating disease (11).

Prior MR investigators have reported the normal patterns of myelin maturation in children, which near completion by the end of the 2nd year of development (23–27). We chose to examine two groups of children with developmental delay using that age as a cutoff criterion. We examined children aged 2 years or younger, when myelination is not complete, and compared this group with age-matched healthy children. We also examined children older than 2 years with

developmental delay and compared these children with age-matched control subjects.

To assess myelin maturation, voxels for the proton MR spectroscopy were placed in the parieto-occipital and frontal subcortical white matter bilaterally. We chose a PRESS sequence with a long TE to have a maximum signal-to-noise ratio. We were specifically interested in assessment of NAA/Cr and Cho/Cr ratios and were not interested in the detection of glutamine or glutamate peaks. We wanted to exclude the presence of lactate, which could indicate an underlying metabolic disorder (ie, mitochondrial disease), which is easier to detect with the long TE MR spectroscopic sequence.

Because ratios are given, it is theoretically possible that Cr levels could account for the observation of decreased NAA/Cr and elevated Cho/Cr levels in children with developmental delay. This seems unlikely given that the major physiologic processes at work during brain maturation are myelination development and declining brain water content (25, 29, 31, 32).

We observed no statistically significant difference in the NAA/Cr or Cho/Cr ratios in children aged 2 years or younger with developmental delay compared with the control children in this age group, and the spectra of these children looked similar (Fig 2). This may be a reflection of small sample size. It may be that a more formal quantitative determination of metabolite concentrations could have yielded a difference. However, we specifically wanted to restrict ourselves to the use of readily available, clinical proton MR spectroscopic sequences, which generate ratios, to assess their role in children with developmental delay. In children older than 2 years who had developmental delay, statistically significant trends were observed. The NAA/Cr ratio was decreased, whereas the Cho/Cr ratio was elevated. A larger, longitudinal study must be performed to determine whether these ratios are persistently abnormal and whether these ratios can serve as a diagnostic neuroimaging marker of hypomyelination and developmental delay.

Regarding the values of NAA/Cr and Cho/Cr, we did not observe significant differences in terms of regional variation (parieto-occipital lobe vs frontal lobe) or in terms of right hemisphere versus left hemisphere. Any minor differences could be attributable to differences in myelination, dendrite or synapse development, or volume averaging gray cortex with white matter in the regions of interest (voxels) chosen for MR spectroscopy.

The diagnosis of developmental delay remains a clinical one that is age-dependent. Before the development of clinical proton MR spectroscopy, investigators thought that serial MR imaging examinations would be needed to differentiate arrested myelination from slow but progressive development (24, 41). Likewise, serial proton MR spectroscopy may be needed to make a similar assessment, particularly in children aged 2 years or younger, which reaffirms the need for a larger, longitudinal study. In this study, none of the patients returned for a follow-up examination, but all

spectra were compared with those of age-matched healthy control subjects. Before the routine clinical use of proton MR spectroscopy, normative data should be acquired since the metabolites that are detected in the brain parenchyma with proton MR spectroscopy fall within narrow ranges depending on age, and this age-dependent distribution of metabolites in the brain is not necessarily uniform (29, 16, 22, 42, 43).

The neurometabolic alterations in the NAA/Cr and Cho/Cr ratios that we observed in the parieto-occipital and frontal subcortical white matter of children with developmental delay may yield insight into the pathophysiology of this process. The observed increase in the Cho/Cr ratio may reflect an inability to properly incorporate Cho-containing molecules into myelin, which would not likely be detected on routine MR images as a signal intensity abnormality. Other explanations such as a loss or disruption of normal myelin, which increases the availability of such Cho-containing compounds, are plausible. The observed decrease in the NAA/Cr ratio may be the result of hypomyelination, decreased numbers of normal neurons, or decreased synaptic density as an underlying cause, which may be missed on routine MR images. If there is damaged myelin or loss of normal myelin, this may be occult to routine MR imaging and still detectable with proton MR spectroscopy.

Abnormalities detected with proton MR spectroscopy in children with developmental delay who have normal-appearing white matter on brain MR images may be a relatively nonspecific finding at present. Thus, these abnormalities should be interpreted in a prudent manner, especially since NAA/Cr and Cho/Cr ratios vary rapidly in early brain development. Although the use of ratios is less sensitive and specific than direct quantification of metabolites, their use is becoming widespread in clinical practice. Information regarding the magnitude and severity of observed changes in the NAA/Cr or Cho/Cr ratio could be valuable in assessing long-term functional outcome even though the exact nature of these changes is not clear. Abnormal proton MR spectra, if followed longitudinally, may offer another diagnostic or objective quantifiable assessment of neurodevelopment, especially as more children with developmental delay are studied with proton MR spectroscopy.

Conclusion

In children with developmental delay who are older than 2 years, proton MR spectroscopy typically detected abnormalities in the NAA/Cr and Cho/Cr ratios in the frontal and parieto-occipital subcortical white matter despite a normal-appearing brain MR image. Proton MR spectroscopy should be performed as part of the neuroimaging evaluation of children who have developmental delay, particularly for children older than 2 years, as it can suggest a diagnosis of hypomyelination. Further longitudinal studies will be needed to determine whether the abnormalities detected at proton MR spectroscopy can be used as a

diagnostic neuroimaging marker of developmental delay and whether these abnormalities correlate with long-term prognosis or functional outcome.

Acknowledgments

We thank the following MR technicians and nurses for their help in obtaining diagnostic proton MR spectra in these children: Richard Fisher, Chul Lee, John Crespo, John McCormack, Thomas Farrell, Keith Clay, Carmen Vargas, and Maria Bollwein. We also thank Richard Watts for his assistance with the generation of the DICOM images.

References

1. Cunningham RD Jr. Neuroimaging studies in children with developmental delay [comment]. *J Pediatr* 1996;128:302
2. Filipek PA. Neuroimaging in the developmental disorders: the state of the science. *J Child Psychol Psychiatry* 1999;40:113-128
3. Bouhadiba Z, Dacher J, Monroe M, Vanhulle C, Menard J, Kalifa G. MRI of the brain in the evaluation of children with developmental delay. *J Radiol* 2000;81:870-873
4. Aicardi J. The etiology of developmental delay. *Semin Pediatr Neurol* 1998;5:15-20
5. Schaefer GB, Bodensteiner JB. Radiological findings in developmental delay. *Semin Pediatr Neurol* 1998;5:33-38
6. Battaglia A, Bianchini E, Carey JC. Diagnostic yield of the comprehensive assessment of developmental delay/mental retardation in an institute of child neuropsychiatry. *Am J Med Genet* 1999;82:60-66
7. Shevell MI. The evaluation of the child with a global developmental delay. *Semin Pediatr Neurol* 1998;5:21-26
8. Hashimoto T, Tayama M, Miyazaki M, et al. Differences in brain metabolites between patients with autism and mental retardation as detected by in vivo localized proton magnetic resonance spectroscopy. *J Child Neurol* 1997;12:91-96
9. Castillo M, Kwok L, Courvoisie H, Hooper SR. Proton MR spectroscopy in children with bipolar affective disorder: preliminary observations. *Am J Neurol* 1999;21:832-838
10. Moore GJ. Proton magnetic resonance spectroscopy in pediatric neuroradiology. *Pediatr Radiol* 1998;28:805-814
11. Zimmerman RA, Wang ZJ. The value of proton MR spectroscopy in pediatric metabolic brain disease. *AJNR Am J Neuroradiol* 1997;18:1872-1879
12. Wang Z, Zimmerman RA, Sauter R. Proton MR Spectroscopy of the Brain: Clinically Useful Information Obtained in Assessing CNS Diseases in Children. *AJR Am J Roentgenol* 1996;167:191-199
13. Shevell MI, Ashwal S, Novotny E. Proton magnetic resonance spectroscopy: clinical applications in children with nervous system diseases. *Semin Pediatr Neurol* 1999;6:68-77
14. Tzika AA, Vigneron DB, Ball WS Jr, Dunn RS, Kirks DR. Localized proton MR spectroscopy of the brain in children. *J Magn Reson Imaging* 1993;5:719-729
15. Novotny E, Ashwal S, Shevell M. Proton magnetic resonance spectroscopy: an emerging technology in pediatric neurology research. *Pediatr Res* 1998;44:1-10
16. Barkovich AJ, Baranski K, Vigneron J, et al. Proton MR spectroscopy for the evaluation of brain injury in asphyxiated, term neonates. *AJNR Am J Neuroradiol* 1999;20:1399-1405
17. Hanrahan JD, Cox IJ, Azzopardi D, et al. Relation between proton magnetic resonance spectroscopy within 18 hours of birth asphyxia and neurodevelopment at 1 year of age. *Dev Med Child Neurol* 1999;41:76-82
18. Holshouser BA, Ashwal S, Luh GY, et al. Proton MR spectroscopy after acute central nervous system injury: outcome prediction in neonates, infants, and children. *Radiology* 1997;202:487-496
19. Shu SK, Ashwal S, Holshouser BA, Nystrom G, Hinshaw DB Jr. Prognostic value of 1H-MRS in perinatal CNS insults. *Pediatr Neurol* 1997;17:309-318
20. Leth H, Toft PB, Peitersen B, Lou HC, Henriksen O. Use of brain lactate levels to predict outcome after perinatal asphyxia. *Acta Pediatr* 1996;85:859-864
21. Penrice J, Cady EB, Lorek A, et al. Proton magnetic resonance spectroscopy of the brain in normal preterm and term infants, and early changes after perinatal hypoxia-ischemia. *Pediatr Res* 1996;40:6-14

22. Cady EB, Amess P, Penrice J, Wylezinska M, Sams V, Wyatt JS. **Early cerebral-metabolite quantification in perinatal hypoxic-ischemic encephalopathy by proton and phosphorous magnetic resonance spectroscopy.** *Magn Reson Imaging* 1997;15:605-611
23. Dietrich RB, Bradley WG, Zaragoza EJ, et al. **MR evaluation of early myelination patterns in normal and developmentally delayed infants.** *AJR Am J Roentgenol* 1988;150:889-896
24. Harbord MG, Finn JP, Hall-Craggs MA, Robb SA, Kendall BE, Boyd SG. **Myelination patterns on magnetic resonance of children with developmental delay.** *Dev Med Child Neurol* 1990;32:295-303
25. Hashimoto T, Tayama M, Miyazaki M, et al. **Developmental brain changes investigated with proton magnetic resonance spectroscopy.** *Dev Med Child Neurol* 1995;37:398-405
26. Brody BA, Kinney HC, Kloman AS, Gilles FH. **Sequence of central nervous system myelination in human infancy: an autopsy study of myelination.** *J Neuropath* 1987;46:283-301
27. Barkovich AJ, Kjos BO, Jackson DE Jr, Norman D. **Normal maturation of the neonatal and infant brain: MR imaging at 1.5 T.** *Radiology* 1988;166:173-180
28. Cady EB, Penrice J, Amess PN, et al. **Lactate, N-acetylaspartate, choline, and creatine concentrations and spin-spin relaxation in thalamic and occipito-parietal regions of developing human brain.** *Magn Reson Med* 1996;36:878-886
29. Kreis R, Ernst T, Ross BD. **Development of the human brain: in vivo quantification of metabolite and water content with proton magnetic resonance spectroscopy.** *Magn Reson Med* 1993;30:424-437
30. Kimura H, Fujii Y, Itoh S, et al. **Metabolic alterations in the neonate and infant brain during development: evaluation with proton MR spectroscopy.** *Radiology* 1995;194:483-489
31. Kadota T, Horinouchi T, Kuroda C. **Development and aging of the cerebrum: assessment with proton MR spectroscopy.** *AJNR Am J Neuroradiol* 2001;22:128-135
32. Toft PB, Leth H, Lou HC, Pryds O, Henriksen O. **Metabolite concentrations in the developing brain estimated with proton MR spectroscopy.** *J Magn Reson Imaging* 1994;4:674-680
33. Peden CJ, Cowan FM, Bryant DJ, et al. **Proton MR spectroscopy of the brain in infants.** *J Comput Assist Tomogr* 1990;14:886-894
34. Yeo RA, Hill D, Campbell R, Vigil J, Brooks WM. **Developmental instability and working memory ability in children: a magnetic resonance spectroscopy investigation.** *Dev Neuropsych* 2000;17:143-159.
35. Friedman SF, Brooks WM, Jung RE, et al. **Quantitative ¹H-MRS predicts outcome following traumatic brain injury.** *Neurology* 1999;52:1384-1396
36. Ford CC, Griffey RH, Matwyoff NA, Rosenberg GA. **Multivoxel MRS of stroke.** *Neurology* 1992;42:653-659
37. Lentner C. *Geigy Scientific Tables*. Vol 1. Basel: Ciba-Geigy; 1981
38. Lentner C. *Geigy Scientific Tables*. Vol 3. Basel: Ciba-Geigy; 1984
39. Scarabino T, Popolizio T, Bertolino A, Salvolini U. **Proton magnetic resonance spectroscopy of the brain in pediatric patients.** *Eur J Radiol* 1999;30:142-153
40. Kruse B, Barker PB, van Zijl PCM, Duyn JH, Moonen CTW, Moser HW. **Multislice proton magnetic-resonance spectroscopic imaging in X-linked adrenoleukodystrophy.** *Ann Neurol* 1994;36:595-608
41. Squires LA, Krishnamoorthy KS, Natowicz MR. **Delayed myelination in infants and young children: radiographic and clinical correlates.** *J Child Neurol* 1995;10:100-104
42. Michaelis T, Merboldt KD, Bruhn H, Hanicke W, Frahm J. **Absolute concentrations of metabolites in the adult human brain in vivo: quantification of localized proton MR spectra.** *Radiology* 1993;187:219-227
43. Provencher SW. **Estimation of metabolite concentrations from localized in vivo proton NMR spectra.** *Magn Reson Med* 1993;30:672-679