



## Discover Generics

Cost-Effective CT & MRI Contrast Agents



FRESENIUS  
KABI

WATCH VIDEO

# AJNR

## NeuroImaging

*AJNR Am J Neuroradiol* 2002, 23 (10) 1812-1813  
<http://www.ajnr.org/content/23/10/1812>

This information is current as  
of June 3, 2025.

### NeuroImaging.

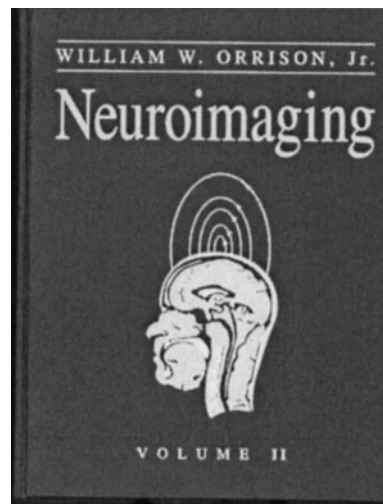
William W. Orrison. Philadelphia, PA: W.B. Saunders Company; 2000. Volumes 1 and 2, 1776 pages, \$415.

This two-volume textbook of neuroradiology was “created to serve as a master reference file on the field of neuroimaging.” It is intended to be a resource for physicians and neuroscientists in different fields, including neuroradiology, radiology, neurology, neurosurgery, psychiatry, psychology, neurophysiology, and neurobiology. Dr. Orrison has assembled chapters from a number of experts in neuroimaging and the neurosciences from throughout the United States.

The content is divided into four sections: section one, history and technology; section two, brain; section three, head, neck, and spine; and section four, pediatrics. Unlike many neuroradiology textbooks, which focus on CT and MR imaging, this text has included material on myelography, cerebral angiography, and newer applications such as MR angiography, CT angiography, and functional MR imaging. In addition, there are chapters in section one on imaging techniques often ignored by neuroradiology texts, including positron emission tomography, single photon emission CT, magnetic source imaging, neurosonography, and transcranial Doppler sonography. As neuroradiology transitions from an anatomic based subspecialty to a physiological and anatomic based subspecialty, these additional modalities are becoming more important to the field. An informative chapter on the history of neuroradiology is also presented and serves as a useful introduction for trainees and younger practitioners. One notable omission from section one is the lack of a dedicated MR spectroscopy chapter. The technology section uses color prints very effectively, particularly for illustration of functional imaging studies.

The section on the brain is fairly comprehensive and includes basic topics typically seen in neuroradiology textbooks, including discussions of tumors, cerebral vascular disease, infection, white matter disease, neurodegenerative disorders, hemorrhage, and trauma. The introductory chapter, “The Normal Brain,” is a very good presentation of functional and topographic neuroanatomy, which is particularly important considering the proliferation of functional neuroimaging techniques. In addition, chapters on normal variants of the CNS and seizure imaging are useful, relevant additions not included in most textbooks.

Neuroradiology textbooks often focus on the brain and the spine. Orrison's *NeuroImaging* includes a comprehensive discussion on extracranial head and neck imaging, which typically is part of routine neuroradiology practice. Some of these chapters have direct relevance to the CNS, specifically those on the skull base and the orbit and visual system. However, discussions of the temporal bone, nasal cavity and sinuses, pharynx and oral cavity, parapharyngeal and



masticator spaces, thyroid and parathyroid, salivary glands, lymph nodes, temporal mandibular joint, larynx, and hypopharynx frequently are discussed in dedicated head and neck radiology textbooks. The presentations of normal anatomy in the extracranial head and neck chapters are especially well done. Section three also includes chapters regarding the spine that are commonly included in neuroradiology texts, including discussions of degenerative diseases, neoplasms, infections and inflammatory diseases, and trauma. The chapters in section three focus primarily on CT and MR imaging, although plain films are included where appropriate and newer 3D imaging techniques are used to illustrate studies of both the spine and the head and neck.

The final section, pediatrics, is a comprehensive discussion of pediatric neuroradiology, including normal development as well as congenital malformations of the brain and spine. Pediatric tumors, metabolic diseases, anoxic ischemic injury, hydrocephalus, neurocutaneous syndromes, and traumatic brain injury are other areas covered. A separate section on pediatric neuroimaging is justified because this is an area that is complex and reference material is frequently sought in many clinical practice settings. This section could have been strengthened by the addition of more information on MR spectroscopy, which has become a more important adjunct to cross-sectional imaging in pediatric neurologic disease during the 2 years since *NeuroImaging* was published.

The entire volume is well illustrated with high quality radiologic images and anatomic diagrams. Some use of pathologic and histologic specimens is present, although radiologic-pathologic correlation is not a focus of this text. The material is comprehensive and

authoritative. These two volumes comprise a very useful reference, particularly for neuroradiologists but also for other radiologists and clinicians. The material may be too extensive to serve as a primary source for a junior radiology resident, but senior radiology residents and neuroradiology fellows will ben-

efit tremendously from this comprehensive work. Scientists outside clinical practice will find this to be a useful reference that puts clinical neuroimaging in perspective. In short, Dr. Orrison has succeeded in putting together a comprehensive reference work regarding state-of-the-art neuroimaging.