



Discover Generics

Cost-Effective CT & MRI Contrast Agents



FRESENIUS
KABI

WATCH VIDEO

AJNR

CT and MR Imaging of Solitary Extramedullary Plasmacytoma of the Nasal Tract

Alex Sik-Chung Ching, James Boon-Kheng Khoo and
Vincent Fook-Hin Chong

This information is current as
of June 4, 2025.

AJNR Am J Neuroradiol 2002, 23 (10) 1632-1636
<http://www.ajnr.org/content/23/10/1632>

CT and MR Imaging of Solitary Extramedullary Plasmacytoma of the Nasal Tract

Alex Sik-Chung Ching, James Boon-Kheng Khoo, and Vincent Fook-Hin Chong

BACKGROUND AND PURPOSE: Solitary extramedullary plasmacytoma (SEP) is rare. The purpose of this study was to determine the CT and MR imaging features of SEP of the nasal tract.

METHODS: We retrospectively reviewed three CT and two MR images of three histologically proved cases in two men and one woman aged 43–66 years.

RESULTS: The plasmacytomas predominantly involved the nasopharynx in two cases and the nasal cavity in one. Two of the tumors were bulky solid masses, whereas the third showed infiltrative features. They were predominantly masses or infiltrative lesions with soft-tissue attenuation on CT scans. The lesions were isointense and hyperintense on T1- and T2-weighted MR images, respectively. The tumors revealed moderate-to-marked contrast enhancement and may have been associated with lytic bone destruction.

CONCLUSION: The imaging features of SEP are nonspecific. However, this entity should be included in the differential diagnosis of tumors in the nasopharynx and nasal cavity.

Dalrymple and Bence-Jones first identified a plasma dyscrasia in 1846 when they described a condition with diffuse bone pain and marked proteinuria. However, it was not until 1873 when Rustizky et al successfully recognized it as a distinct histopathologic entity: multiple myeloma. Since then, this plasma cell neoplasm has been classified into one of three categories: the disseminated form, multiple myeloma, and the localized forms of medullary and extramedullary plasmacytomas. The last variant, solitary extramedullary plasmacytoma (SEP), accounts for less than 2% of all neoplastic plasma dyscrasias and occurs in any part of the body, especially in the head and neck (1). Nevertheless, this rare tumor represents only less than 1% of all malignancies in the head and neck region (2). About 75–80% of these tumors originate in the submucosa of the upper aerodigestive tract; of these, 75% involve the nasal tract (1–3). Patients typically present with localized disease that has an insidious natural clinical course (3). Despite the characteristic histologic and immunohistochemical features, SEP remains a diagnostic challenge to both clinicians and radiologists (2). A review of the literature revealed sporadic reports of imaging findings of SEP in the nasal cavity (1, 4–7). Knowledge of the

imaging features of this entity in the literature is limited. In this study, we sought to describe the CT and MR imaging appearances of SEP in the nasal or nasopharyngeal region in three patients.

Methods

The clinical data and imaging studies of three patients with SEP involving the nasal tract were retrospectively reviewed. In these patients, SEP was diagnosed over a period of 22 months (February 2000 to December 2001) from the tertiary referral institution, the National Cancer Centre, in Singapore. The study included two men and one woman aged 43–66 years (mean age, 57.3 years). One patient was Chinese; one, Indian; and one, Eurasian. Two patients underwent both contrast-enhanced CT and MR imaging examinations of the sinonasal and nasopharyngeal areas, and one patient underwent contrast-enhanced CT examination of the nasopharynx. The CT scans were obtained by using a spiral CT scanner (Somatom Plus 4; Siemens, Erlangen, Germany) with 5-mm collimation and a 5-mm interval from the orbital roof to the root of the neck during quiet inspiration with the injection of the contrast agent. The images were obtained with soft tissue and bone algorithms and in the respective window settings. MR imaging was performed by using a 1.5-T MR unit (Signa; GE Medical Systems, Milwaukee, WI) equipped with a head coil. Two patients underwent an axial T1-weighted spin-echo sequence (TR/TE/NEX, 470–500/19–21/1–2; field of view, 21 cm; section thickness, 5 mm with no gap; matrix size, 256 × 202) and a coronal T2-weighted fast spin-echo sequence (5000–5400/93–99/1–2; echo train length, 14; field of view, 21 cm; section thickness, 5 mm with no gap; matrix size, 256 × 202). In addition, contrast-enhanced T1-weighted spin-echo images were obtained in the axial and coronal planes after a bolus injection of 0.1 mmol/kg of gadolinium dimeglumine. Images were reviewed by consensus by two radiologists (A.S.C.C., V.F.H.C.) with knowledge of only the histologic diagnosis. Both CT and MR images were evaluated for the location, characteristics, and local extent of

Received March 6, 2002; accepted after revision June 26.

From the Department of Diagnostic Imaging, National Cancer Centre, Singapore, Singapore.

Address reprint requests to Dr. Alex S. C. Ching, Radiology Department, North District Hospital, No. 9 Po Kin Road, Sheung Shui, New Territories, Hong Kong.

© American Society of Neuroradiology

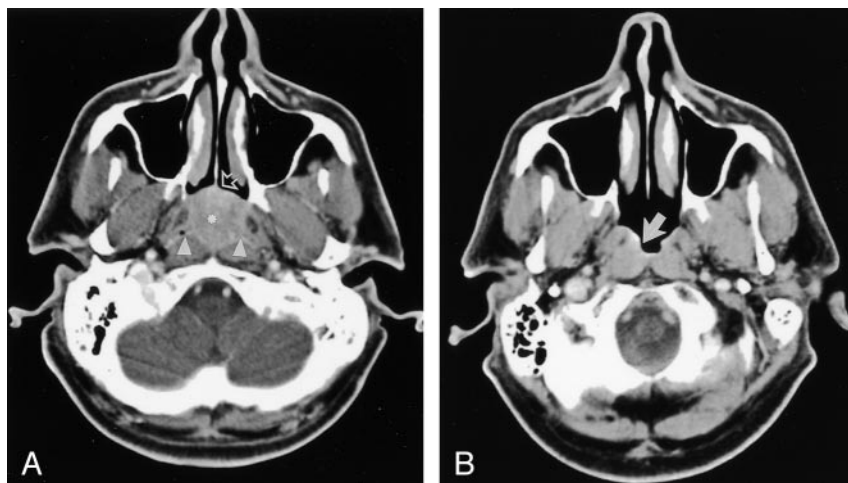


FIG 1. Case 1. Images in a 43-year-old man with a 3-week history of epistaxis caused by SEP of the nasopharynx.

A, Contrast-enhanced axial CT scan shows an inhomogeneous mass (*asterisk*) that fills the entire postnasal space, anteriorly abuts the posterior nasal septum (*arrow*), and posteriorly obliterates bilateral pharyngeal recesses (*arrowheads*).

B, Nine months after local radiation therapy, this contrast-enhanced CT scan shows minimal residual disease (*arrow*).

the tumor; any bone destruction; and any soft-tissue involvement.

Endoscopic examination of the upper aerodigestive tract was performed in all patients under anesthesia. Histologic evaluation and immunohistochemical studies were performed on the biopsy specimens obtained from the tumors. The diagnosis of extramedullary plasmacytoma was established on the basis of the presence of large aggregates of atypical plasma cells that often infiltrated adjacent structures. The monoclonal nature of the plasma cells was confirmed by means of immunoperoxidase staining for kappa and lambda immunoglobulin light chains. Multiple myeloma was excluded by means of normal bone marrow biopsy and skeletal survey.

Results

Presenting symptoms were nasal obstruction ($n = 1$), epistaxis ($n = 1$), and headache ($n = 1$). The mean duration of symptoms before presentation was 4.3 months (range, 3 weeks to 9 months). Results of urinalysis for the Bence-Jones protein, serum electrophoresis, and serum protein electrophoresis were all negative. In two patients, a complete response to radiation therapy was noted. In the remaining patient, the treatment response was poor, and local recurrence was noted. As of this writing, all patients were surviving, and no patient had progressed to multiple myeloma.

Tumor Location and Extent

In two patients, disease was confined predominantly to the nasopharynx. Of these, one patient had a solitary soft-tissue mass in the roof and the posterior pharyngeal wall with extension to the posterior nasal cavity and nasal septum (Fig 1). One patient had a diffuse lesion effacing the right fossa of Rosenmuller and posterior pharyngeal wall (Fig 2). In one patient, the disease site was in the nasal cavity with a soft-tissue mass of the nasal septum. Involvement of both sides of the nasal cavity was observed with destruction of the nasal turbinates and extension into the hard palate and nasopharynx. Adjacent maxillary sinus involvement was noted (Fig 3).

Bone Destruction

Osteolytic erosion with no sclerosis was present in one patient. Erosion of the medial maxillary wall was present in the patient with maxillary extension. In this patient, the adjacent middle and inferior turbinates were also involved.

Soft-Tissue Involvement

MR imaging possesses advantages over CT because of its excellent soft-tissue contrast. In two patients with MR images, tumors were of homogeneous signal intensity similar to the signal intensity of muscle on T1-weighted images. On T2-weighted images, the signal intensity was moderately higher than that of muscle but lower than that of the mucosa. Moderate-to-marked heterogeneous enhancement occurred in all involved soft tissues on CT and MR images. In one patient, the diffuse lesion showed local infiltration to the ipsilateral medial pterygoid muscle and carotid space, as well as prevertebral musculature (Fig 2). No fluid or mucus retention was noted in the sinonasal cavity. No soft-tissue involvement of the buccinator spaces, infratemporal fossa, or temporalis muscle was observed. No substantially enlarged parapharyngeal or cervical lymph nodes were noted in any cases.

Discussion

SEP of the nasal tract is rare neoplasm of B-lymphocyte populations (8). They account for less than 1% of all head and neck malignancies and 4% of nonepithelial tumors of the nasal tract with an overall incidence of three per 100,000 population per year (2, 4). The incidence is higher in men aged 60–80 years, with a male-to-female ratio of more than 3:1. No racial predilection is noted. Most recorded tumors are located mainly in the head and neck and involve the sinonasal or nasopharyngeal regions (75%), followed by the larynx (18%) and the oropharynx (12%). Manifestations in rare sites, including the tongue, tonsils, minor salivary glands, posterior pharyngeal wall, thyroid, parotid gland, and middle ear have been

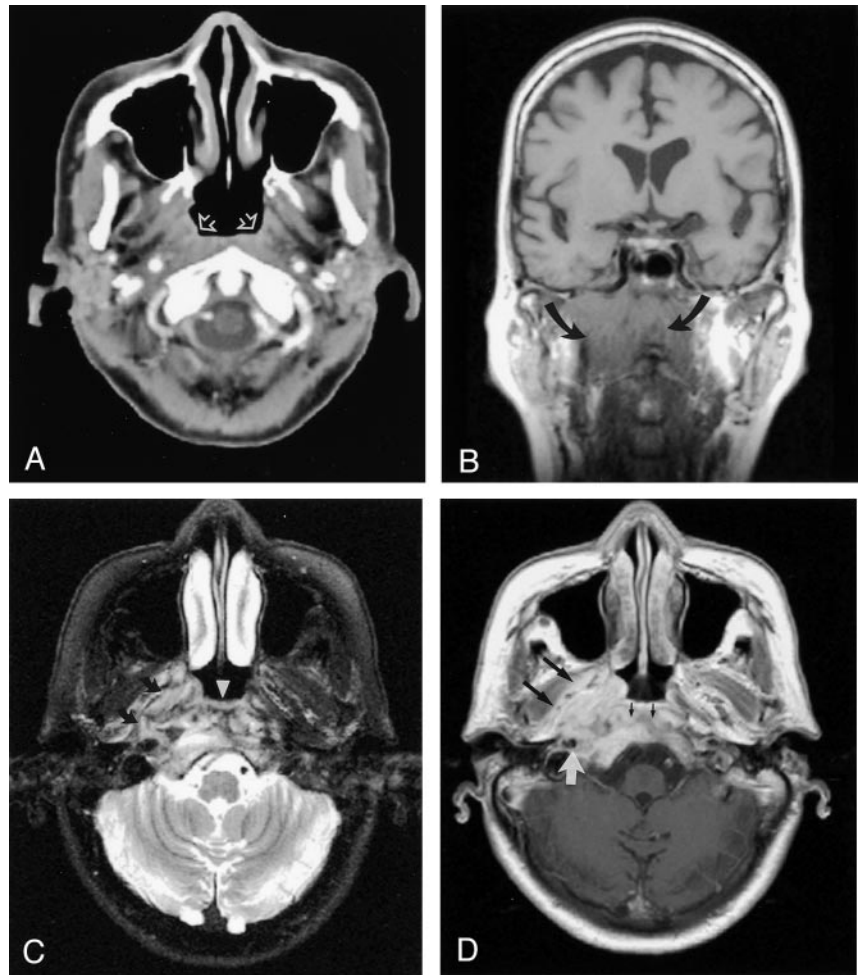
FIG 2. Case 2. Images in a 66-year-old woman with nasopharyngeal extramedullary plasmacytoma who presented with a 9-month history of headache.

A, Contrast-enhanced axial CT scan shows subtle asymmetry of the bilateral fossae of Rosenmüller (arrows).

B, Coronal T1-weighted spin-echo MR image (TR/TE, 500/2) shows a diffuse isointense mass infiltrating the mucosal and submucosal regions (arrows).

C, Axial T2-weighted fast spin-echo MR image (5400/99) shows a hyperintense lesion at the posterior pharyngeal wall (arrowhead) infiltrating the right parapharyngeal region (arrows).

D, Contrast-enhanced T1-weighted spin-echo image (490/18) shows moderate-to-marked enhancement of the lesion and involvements of right medial pterygoid muscle (large black arrows), right carotid space (white arrow), clivus, and prevertebral musculature (small black arrows).



reported (1, 4, 9). Virtually any part of the body, including the liver and colon, can be affected (10, 11). SEP appears as a slowly growing mass; therefore, a delay in diagnosis is common. The clinical presentation is mainly due to mass effect and depends on the site of involvement. The two most common clinical findings are a soft-tissue swelling and nasal obstruction (80%). Epistaxis, nasal discharge, pain, proptosis, cervical lymphadenopathy, and cranial nerve palsy are less common and nonspecific findings in the initial presentation. Obtaining biochemical clues before biopsy is difficult because only 25% of the patients have increased levels of M-protein in their blood or urine (4, 12).

In this study, two nasal tract SEPs were bulky and appeared as mildly heterogeneous, soft-tissue-attenuating masses with moderate-to-marked contrast enhancement on CT scans. CT examination would be useful in showing the underlying bony abnormality. One tumor showed expansion with remodeling of the adjacent bone and lytic bone destruction. One of our cases showed a subtle unilateral superficial lesion involving the nasopharynx, which represented an early superficial lesion; this finding was unclear on the CT scans. MR imaging offers advantages over CT on account of its high soft-tissue contrast and multiplanar depictions. The T1-weighted MR images revealed

intermediate signal intensity, and the T2-weighted images showed moderate-to-high signal intensity. After the introduction of gadolinium-based contrast agent, moderate-to-marked enhancement was observed. These imaging features are not specific, and bone erosion, although suggestive of the diagnosis, could be caused by other aggressive lesions. Imaging alone cannot be used to reliably distinguish this tumor from other malignancies of the nasal tract such as squamous cell carcinoma, lymphoma, adenocystic carcinoma, esthesioneuroblastoma, rhabdomyosarcoma, and Wegener granulomatosis. Together, CT and MR imaging are the methods of choice for assessing local disease, but the diagnosis of SEP of the nasal tract still requires histologic and immunohistochemical evidence. Macroscopically, SEP has variable appearances. It can appear as a fleshy, yellowish gray to dark red sessile, polypoid, or pedunculated lesion. This disorder is histopathologically characterized by florid monomorphic infiltrates of plasma cells with a variable degree of cellular atypia in a delicate, reticular stroma. The demonstration of a monoclonal pattern of immunoperoxidase staining for kappa and lambda immunoglobulin light chains distinguishes plasmacytomas from reactive plasmacytosis (13). The use of gene rearrangement molecular techniques has been advocated to demonstrate the monoclonal pattern.

This tumor is highly radiosensitive. Treatments with

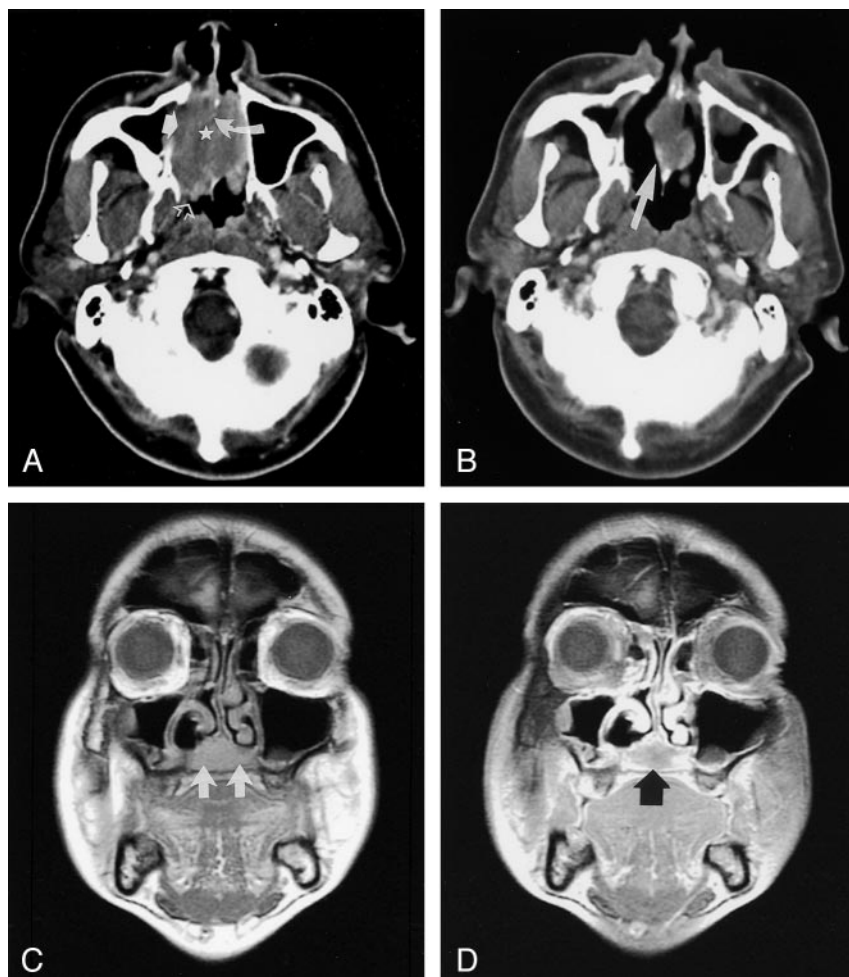


FIG 3. Case 3. Images in a 63-year-old man with a 3-month history of nasal blockage caused by nasal extramedullary plasmacytoma.

A, Contrast-enhanced axial CT scan shows a large soft-tissue mass (star) filling the entire nasal cavity, with erosion of the nasal septum (curved solid arrow) and right medial maxillary wall (straight solid arrow) extending posteriorly to the nasopharynx (open arrow).

B, Eight-month follow-up contrast-enhanced CT scan shows a considerable decrease in the size of the tumor (arrow) after regional radiation therapy. This finding indicates partial remission.

C, Ten-month follow-up coronal T1-weighted spin-echo MR image (470/19) shows a new isointense area in the hard palate (arrows) that suggests recurrence.

D, Coronal T2-weighted fast spin-echo image (5000/93) shows moderate inhomogeneous enhancement of the tumor (arrow).

either local radiation therapy or surgery are equally effective (3, 14). As demonstrated in our study, radiation therapy achieved fairly local and regional control. The prognosis is good, with more than 70% of patients with SEP surviving longer than 10 years (15). The five patterns of biologic behavior of SEP are related to the clinical course. The two most common patterns (75–80%) are 1) localized disease controlled by surgery, radiation therapy, or both and 2) locally recurrent disease controlled by additional therapy. Other patterns include local disease with subsequent dissemination (15–36%), regional lymphadenopathy without dissemination (8–12%), and death due to uncontrollable local extension (5%) (4, 13).

This study has possible methodologic limitations. Potential selection bias cannot be excluded. Our sample was small because relatively few patients have this rare disease. This limitation may have prevented the demonstration of more variations in the imaging features of this disorder. In addition, the radiologists were not blinded to the patient's clinical history. This bias might have increased the CT or MR imaging findings. Because of the retrospective nature of this study, further studies are required to investigate correlations between the extent of the tumor; the imaging characteristics; and the stage of disease; and, ultimately, the clinical outcome.

Conclusion

SEP shows nonspecific CT and MR imaging features. However, features that may suggest the diagnosis are a bulky soft-tissue mass or infiltrative lesion. The tumor does not usually become disseminated, but it may be locally aggressive and demonstrate marked involvement and destruction of the adjacent structures. CT and MR imaging are complementary techniques in evaluating the local extent of this rare plasma cell tumor. SEP should be included in the differential diagnosis of a nasal tract lesion because it has imaging findings similar to those of other more common lesions such as nasopharyngeal carcinoma and lymphoma.

References

1. Susnerwala SS, Shanks JH, Banerjee SS, Scarffe JH, Farrington WT, Slevin NJ. Extramedullary plasmacytoma of the head and neck region: clinicopathological correlation in 25 cases. *Br J Cancer* 1997;75:921–927
2. Rodriguez A, Montgomery W, Weber AL. Extramedullary laryngeal plasmacytoma. *Ann Otol Rhinol Laryngol* 1996;105:483–486
3. Holland J, Trenker DA, Wasserman TH, Fineberg B. Plasmacytoma: treatment results and conversion to myeloma. *Cancer* 1992; 69:1513–1517
4. Wax MK, Yun KJ, Omar RA. Extramedullary plasmacytomas of the head and neck. *Otolaryngol Head Neck Surg* 1993;109:877–885

5. Hidaka H, Ikeda K, Oshima T, Ohtani H, Suzuki H, Takasaka T. A case of extramedullary plasmacytoma arising from the nasal septum. *J Laryngol Otol* 2000;114:53-55
6. Fueredi GA, Czarnecki DJ, Cooley PA. Evaluating extramedullary plasmacytoma with computed tomography. *Wis Med J* 1989;88:15-16
7. Bhimani S, Griffin W, Virapongse C, Altmeyer V, Kier EL. CT findings in a nasopharyngeal extramedullary plasmacytoma. *J Comput Assist Tomogr* 1983;7:1081-1083
8. Jaffe ES, Harris NL, Diebold J, Hermelink HKM. World Health Organization Classification of neoplastic diseases of the hematopoietic and lymphoid tissues: a progress report. *Am J Clin Pathol* 1999;111(supp 1):S8-S12
9. Rothfield RE, Johnson JT, Staurides A. Extramedullary plasmacytoma of the parotid. *Head Neck* 1990;12:352-354
10. Weichhold W, Labourie E, Merlio JP, Masson B, de Mascarel A. Primary extramedullary plasmacytoma of the liver. A case report. *Am J Surg Pathol* 1995;19:1197-1202
11. Ligato S, El-Naggar A, Cleary KR, Manning J. Extramedullary plasmacytoma mimicking primary colonic carcinoma in a patient with Crohn's disease: case report and literature review. *Arch Pathol Lab Med* 1996;120:279-282
12. Yacoub GS, Dubaybo BA. Plasmacytoma and upper airway obstruction. *Am J Otolaryngol* 1999;20:257-259
13. Mock PM, Neal GD, Aufdemorte TB. Immunoperoxidase characterization of extramedullary plasmacytoma of the head and neck. *Head Neck Surg* 1987;9:356-361
14. Ikeda K, Takasaka T. Endoscopic laser sinus surgery using KTP/532 laser. *Lasers Med Sci* 1996;11:133-138
15. Sadek SA, Dogra TS, Khan MK, Baraka ME, Sidhom NN. Plasmacytoma of the nasopharynx: a case report with a follow-up of twelve years. *J Laryngol Otol* 1985;99:1289-1292