



## Discover Generics

Cost-Effective CT & MRI Contrast Agents



FRESENIUS  
KABI

WATCH VIDEO

# AJNR

## Endovascular Treatment of Hemorrhage after Tonsillectomy in Children

Michael J. Opatowsky, J. Dale Browne, William F. McGuirt Jr and P. Pearse Morris

*AJNR Am J Neuroradiol* 2001, 22 (4) 713-716

<http://www.ajnr.org/content/22/4/713>

This information is current as of June 4, 2025.

## Endovascular Treatment of Hemorrhage after Tonsillectomy in Children

Michael J. Opatowsky, J. Dale Browne, William F. McGuirt Jr, and P. Pearse Morris

**Summary:** Endovascular therapy for hemorrhage after tonsillectomy or adenoidectomy is an important adjunct to the definitive treatment of this life-threatening occurrence. We report two cases of hemorrhage after tonsillectomy and/or adenoidectomy and describe the endovascular management of this complication in children.

Removal of the adenoids and tonsils remains one of the most commonly performed childhood surgeries, with an estimated 286,000 such procedures performed in the United States in 1994 (1). Although a number of complications related to this surgery have been well characterized in the literature, the most common and potentially life threatening is post-tonsillectomy and adenoidectomy hemorrhage (PTAH). We present two pediatric cases of severe PTAH refractory to cauterization and surgical ligation in which bleeding was ultimately controlled through endovascular techniques.

### Case Reports

#### Case 1

A 10-year-old girl with no significant medical history underwent tonsillectomy and adenoidectomy at another hospital. In the recovery room, she experienced coughing, vomiting, and bleeding from the surgical site. She was intubated and returned to the operating room twice after conservative attempts to control bleeding failed. The anterior and posterior tonsillar pillars were oversewn, but bleeding persisted. The patient's hemoglobin level dropped significantly, to 7.1 g/dL, with an associated drop in blood pressure and an elevated pulse rate, necessitating 3 U of packed red blood cells and crystalloid for stabilization. After fluid resuscitation and blood replacement, coagulopathy was found to be present, with a partial thromboplastin time of 43.8 s and a prothrombin time of 15 s. By report from the outside hospital, a vessel on the right near the junction of the tonsillar bed and soft palate had been ligated. The patient was airlifted to our institution for further management.

On arrival, she was intubated and sedated. Examination of the oral cavity revealed a suture visible on the left and right tonsillar pillars extending along the soft palate. Bulging of the soft palate was noted, which was greater on the right, with

continued slow bleeding from both tonsillar fossae under the oversewn tonsillar pillars. To establish secure control of hemorrhage in this child, we elected to proceed with endovascular embolization of the bleeding vessel(s).

Under general anesthesia, the right common femoral artery was punctured, and a 5F sheath was inserted. A 5F catheter was used to select the right common carotid artery, right external carotid artery (ECA), right ascending pharyngeal artery, and left common carotid artery. Biplane arteriography of the head was performed. The right internal carotid artery (ICA) was intact, although deviated in its course, presumably as a result of a hematoma within the adjacent soft tissues. No active extravasation was encountered, although the right ascending palatine artery had a suspicious appearance with an elongated and truncated configuration thought to correspond in location to the junction area of the tonsillar bed and soft palate (Fig 1A). In the absence of active extravasation of contrast material, the precise site of arterial injury was difficult to confirm; however, the appearance of the ascending palatine artery on the right was sufficiently suspicious to warrant intervention, particularly given recent clinical events. After coaxial selection with a TurboTracker 18 microcatheter (Target Therapeutics, Fremont, CA), three 10-mm fiber coils (Target Therapeutics) were placed consecutively along the distal course of the right ascending palatine artery, resulting in a satisfactory angiographic appearance of distal occlusion of that vessel (Fig 1B). No other embolization was performed in the absence of identifiable arterial abnormalities. The patient tolerated the procedure well, recovered without incident, and was discharged on the fourth hospital day. Subsequent evaluation after our intervention confirmed the presence of type I von Willebrand disease.

#### Case 2

A 5-year-old girl underwent tonsillectomy at another hospital and returned to the clinic 1 week postoperatively with bleeding from the left tonsillar bed. Her hematocrit had dropped to 24 at that time, mandating surgical exploration. A vessel was reportedly ligated on the left. A blood transfusion increased the hematocrit to 32. The patient was discharged but returned 1 week later with recurrent bleeding and a hemoglobin of 7.2. She again went to the operating room and her tonsillar bed was "aggressively" cauterized. A larger bleeding vessel was oversewn. Transfusion with packed red blood cells resulted in a hematocrit elevation to 36. The patient was transferred to our institution for continuing care.

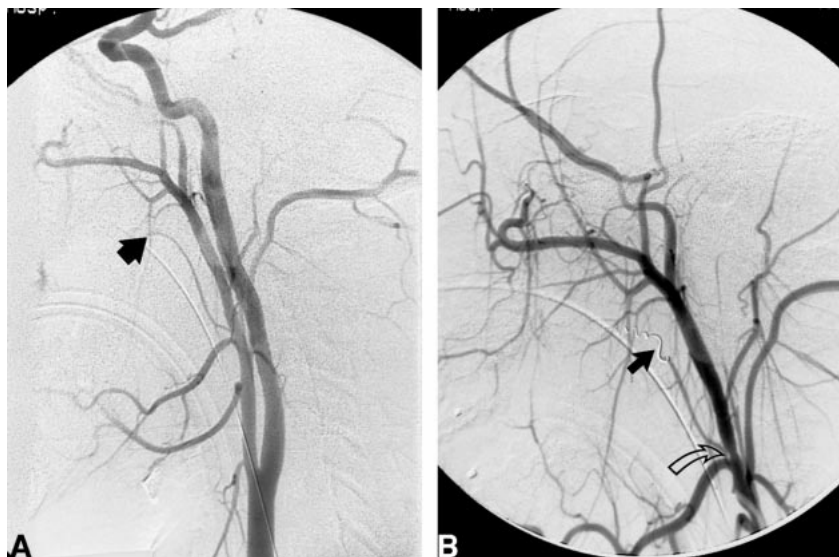Upon arrival in the emergency department, she was hemodynamically stable. Given her clinical course, angiographic assessment was deemed prudent, particularly given a further reduction in her hematocrit to 29.2. Under general anesthesia, the right common femoral artery was punctured and a 5F sheath was placed. The left ECA was selected and injected with contrast material, revealing irregularities of the proximal lingual artery (Fig 2A). The ascending pharyngeal artery was selected first and polyvinyl alcohol (PVA) particles measuring 150 to 250  $\mu$ m were injected. In addition, a 3-  $\times$  7-mm platinum coil was deployed in the ascending pharyngeal artery. The lingual artery was then selected and injected. Free extrav-

Address reprint requests to P. Pearse Morris, M.B., B.Ch., Department of Radiologic Sciences, Wake Forest University School of Medicine, Medical Center Blvd, Winston-Salem, NC 27157.

FIG 1. Case 1: 10-year-old girl with PTAH.

A, Right common carotid artery angiogram shows elongation and abrupt truncation of the ascending palatine artery (*arrow*). This finding was considered suspicious in light of recent PTAH.

B, An ECA angiogram reveals coil embolization of the distal ascending palatine artery (*solid arrow*). Mild catheter-induced spasm is noted along the main ECA trunk (*open arrow*) that is not apparent in A.



asation of contrast material was noted in the surrounding extraluminal space. Multiple 3- × 7-mm platinum coils were deployed as well as three 0.2- × 8.0-cm Guglielmi detachable coils. As the catheter was retracted, the origin of the lingual artery was closed using three 3- × 7-mm platinum coils, and occlusion of the vessel was confirmed angiographically (Fig 2B). After embolization, the patient remained stable and tolerated a full oral diet. She was discharged 2 days after embolization, and no subsequent bleeding episodes were reported.

### Discussion

Approximately 4300 cases of PTAH occur each year in this country, with a reported incidence of less than 1% to greater than 10% (2). More recent references have placed the incidence at approximately 2% to 3% (3, 4). PTAH accounts for the majority of fatalities arising from tonsillectomy and adenoidectomy and represents the most common cause of prolonged postprocedural hospitalization.

A number of articles have addressed strategies for the management of PTAH, including clot removal, silver nitrate or electrocautery, injection of vasoconstricting drugs, local pressure, suture ligation of bleeding vessels in the tonsillar bed, par-

enteral oxytocin, and, as a last resort, ligation of the ECA or its branches (5, 6). The two cases reported here represent successful attempts to use endovascular embolization techniques to control PTAH. Few descriptions of this potentially life-saving intervention have appeared in the literature (7, 8). Primary PTAH is generally regarded as bleeding arising from the operative site within 24 hours after surgery. This type of hemorrhage is thought to be related to surgical technique, vessel injury, or difficulties encountered in achieving complete hemostasis. In the first case of primary PTAH reported here, the patient was subsequently found to have type I von Willebrand disease, which has been identified as a risk factor for PTAH (9). Acutely, this child had a superimposed dilutional coagulopathy. Although one potential approach to this situation might have been to correct the coagulopathy before pursuing an endovascular procedure, the clinical status of the patient with continued bleeding warranted a more expedient intervention.

Secondary hemorrhage occurs beyond the first 24 hours postoperatively, most commonly, 5 to 10 days after surgery, and is thought to be unrelated

FIG 2. Case 2: 5-year-old girl with PTAH.

A, An ECA angiogram shows proximal irregularity of the lingual artery (*arrow*). A subsequent selective lingual artery injection showed free extravasation of contrast material from this point, confirming the source of PTAH.

B, Coil embolization of the proximal lingual artery (*solid arrow*). A portion of the distal lingual artery is reconstituted via generous collateral ECA branches (*open arrow*). This situation is commonly encountered in the ECA territory and can contribute to rebleeding, which may be minimized by embolization distal and proximal to the site of injury.

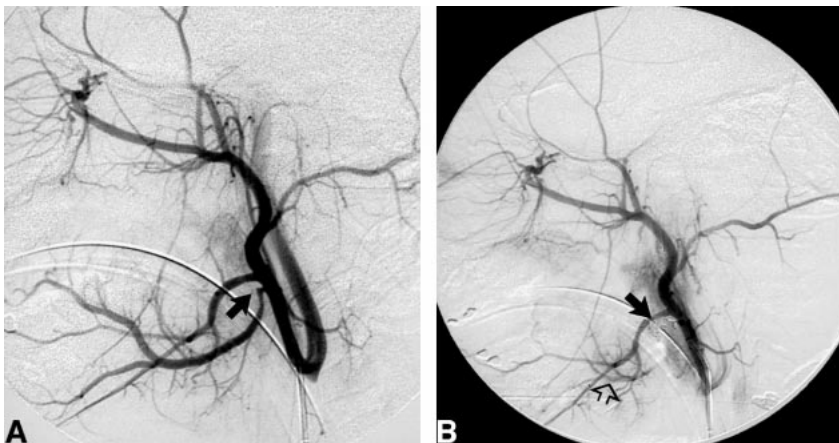

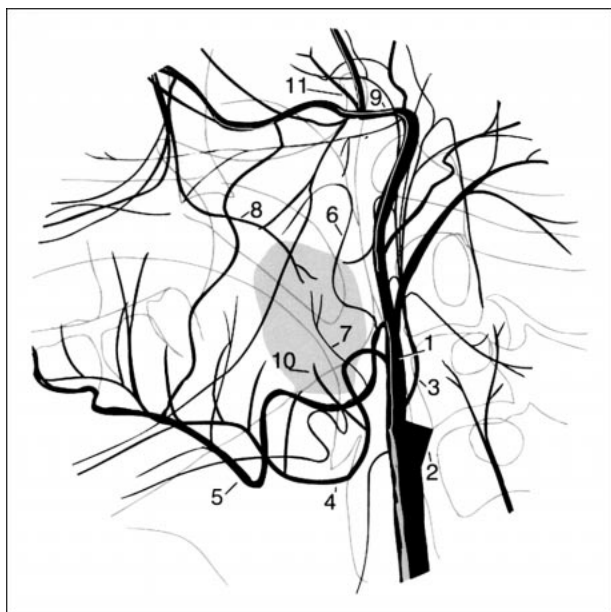


FIG 3. Drawing shows major arterial supply to the palatine tonsil and adenoidal area. 1, ECA; 2, ICA; 3, ascending pharyngeal artery; 4, lingual artery; 5, facial artery; 6, ascending palatine artery; 7, tonsillar artery; 8, descending palatine artery; 9, internal maxillary artery; 10, dorsal lingual artery; 11, accessory meningeal artery.

to surgical technique (2). Our patient with secondary PTAH presented to our hospital 14 days postoperatively. A number of factors have been suggested as increasing the risk of secondary PTAH, including elevated postoperative mean arterial pressure, excessive intraoperative blood loss, older age, a history of chronic tonsillitis, and use of nonsteroidal anti-inflammatory drugs (4, 10).

Achieving complete hemostasis after tonsillectomy or adenoidectomy traditionally has been regarded as a challenge. This is due in part to the generous arterial supply to the palatine tonsils, which includes the descending palatine artery arising from the internal maxillary artery, the ascending pharyngeal artery, the dorsal lingual artery arising from the lingual artery, and the ascending palatine artery and tonsillar artery originating from the facial artery (Fig 3). The proximity of these smaller feeding vessels to adjacent major caliber arteries provides an opportunity for endovascular embolization of postsurgical bleeding in this area.

Bleeding related to tonsillectomy or adenoidectomy may at times be refractory to conservative treatment. Many investigators have advocated surgical reexploration and ligation of bleeding vessels arising from the ECA as a method of definitive treatment. Unfortunately, serious bleeding may not cease after ligation of the ECA or other arterial branches (11). In fact, this proved to be the situation in both the cases described here.

Before initiating endovascular intervention for the control of PTAH, it is key to ensure that the patient is stabilized, which may require transfusion of packed red blood cells. Packing or oversewing

suspected sites of PTAH may also be beneficial. In addition, encouraging a dialogue between surgeon and radiologist offers the opportunity to target the suspected site(s) of PTAH before initiating endovascular therapy. This has the natural advantage of limiting preembolization angiographic assessment, with an attendant reduction in overall procedure time. Prior knowledge of involvement of an adenoidal site of bleeding would expand the angiographic assessment to additional vessels to include the accessory meningeal artery. The procedure is performed with the patient under general anesthesia, with the anesthesiologist paying strict attention to control of the airway. In this manner, the patient's airway and lungs remain protected from the complications that would arise from bleeding that may ensue during an angiographic procedure.

We begin our examination with digitally subtracted angiographic assessment of the common carotid artery in the anteroposterior and lateral projections before selecting the ECA. In this way, injury to the ICA can be evaluated. Arterial anomalies can be more fully elucidated, particularly those that might impact the subsequent procedure, including potentially dangerous anastomoses between the ECA and internal carotid or ophthalmic artery. Every attempt is made to comprehensively study the ECA and its branches before introducing a guidewire into the vessel or its branches. This serves to limit the chance of eliciting procedurally limiting vasospasm. Selective arteriograms of the internal maxillary, facial, and lingual arteries are obtained when necessary.

An ever-expanding armamentarium of embolization materials is available for use in the head and neck. Coil embolization is generally considered the favored choice for PTAH. An adjunct in these procedures is the use of PVA particles or gelatin sponges. The reason for this is twofold. First, microcatheter-directed coils can be discretely deposited into the intended vessel, and many types can be retracted and repositioned to allow for the most optimal placement. Second, when using PVA particles, the proximity of the carotid bifurcation represents an ever-present risk for unintended embolization of particles into the ICA circulation. The use of PVA particles can be a viable option in embolization procedures via the ascending pharyngeal artery, since the risk of reflux into the ICA is notably lessened by virtue of the typical distance of this vascular territory from the carotid bifurcation. When using PVA particles, a size in excess of 150  $\mu\text{m}$  is deemed favorable as a means to prevent unintended mucosal necrosis, damage to adjacent structures, or embolization of the ICA or ophthalmic artery via angiographically occult collateral channels.

Our embolization procedures are typically performed with a 0.010- or 0.018-inch microcatheter via a 5F or 6F sheath placed within a common femoral artery. In medium to large vessels, the site of injury is isolated or trapped by both distally and



proximally situated coils. This serves to diminish the likelihood of subsequent collateralization and rebleeding, a distinctly common occurrence in the ECA vascular territory (Fig 2B). In smaller injured branch end-vessels, distally placed gelatin sponges or coils are generally sufficient to achieve complete embolization, since the risk of collateralization and rebleeding is significantly reduced.

Endovascular embolization in the treatment of refractory PTAH has several advantages. Both the diagnostic angiographic assessment and subsequent intervention can be accomplished in the same procedure. Feeding arteries can be identified and individually treated under direct observation. No further bleeding was encountered in either of our cases. The possible procedure-related complications include branch-vessel perforations with extravasation of embolic material or contrast material, ischemic injury to mucosal surfaces and cranial nerves, inadvertent embolization of the ICA, catheter- or wire-induced vasospasm, and postprocedure pain. As is the case with other types of endovascular embolization procedures of the ECA territory, it is possible to encounter a situation in which no definitive source of hemorrhage can be identified despite clinical evidence of continued bleeding.

### Conclusion

Endovascular intervention in the setting of refractory PTAH will most likely prove to be an im-

portant and commonly used adjunct in the management of this potentially life-threatening complication.

### References

1. Hall MJ, Kozak LJ, Gillum BS. **National survey of ambulatory surgery: 1994.** *Stat Bull Metrop Insur Co* 1997;78:18-27
2. Chowdhury K, Tewfik TL, Schloss MD. **Post-tonsillectomy and adenoidectomy hemorrhage.** *J Otolaryngol* 1988;17:46-49
3. Colclasure JB, Graham SS. **Complications of outpatient tonsillectomy and adenoidectomy: a review of 3,340 cases.** *Ear Nose Throat J* 1990;69:155-160
4. Myssiorek D, Aijaz A. **Post-tonsillectomy hemorrhage: an assessment of risk factors.** *Int J Pediatr Otorhinolaryngol* 1996;37:35-43
5. Steketee KG, Reisdorff EJ. **Emergency care for post tonsillectomy and postadenoidectomy hemorrhage.** *Am J Emerg Med* 1995;13:518-523
6. Franco KL, Wallace RB. **Management of postoperative bleeding after tonsillectomy.** *Otolaryngol Clin North Am* 1987;20:391-397
7. Weber R, Keerl R, Hendus J, et al. **The emergency: traumatic aneurysm in the area of the head and neck.** *Laryngorhinootologie* 1993;72:86-90
8. Mitchell RB, Pereira KD, Lazar RH, et al. **Pseudoaneurysm of the right lingual artery: an unusual case of severe hemorrhage during tonsillectomy.** *Ear Nose Throat J* 1997;76:575-576
9. Allen GC, Armfield DR, Bontempo FA, et al. **Adenotonsillectomy in children with von Willebrand disease.** *Arch Otolaryngol Head Neck Surg* 1999;125:547-551
10. Smith I, Wilde A. **Secondary tonsillectomy hemorrhage and non-steroidal anti-inflammatory drugs.** *J Laryngol Otol* 1999;113:28-30
11. Gardner JF. **Sutures and disasters in tonsillectomy.** *Arch Otolaryngol* 1968;88:551-555