

# Generic Contrast Agents

Our portfolio is growing to serve you better. Now you have a *choice*.



FRESENIUS  
KABI

[VIEW CATALOG](#)

# AJNR

## **In Re: Histologic and Morphologic Comparison of Experimental Aneurysms with Human Intracranial Aneurysms**

WE Stehbens

*AJNR Am J Neuroradiol* 2000, 21 (9) 1770

<http://www.ajnr.org/content/21/9/1770>

This information is current as  
of May 29, 2025.

### MR Findings of the Brain Stem in Arterial Hypertension

In their case reports, de Seze et al (1) describe edema of the brain stem in two patients with arterial hypertension. Their article once again draws attention to an often unrecognized syndrome that is potentially life-threatening. There have been earlier descriptions of brain stem edema in patients with hypertensive encephalopathy on MR images in patients with brain stem signs (2), but this is the first published with such beautiful FLAIR images.

The authors claim that the particular MR pattern helps to understand the change in hypertensive encephalopathy. In my opinion, it merely underlines the more or less accepted role of edema. The pathogenesis of hypertensive encephalopathy warrants more study, despite some excellent work in the past (3, 4). Furthermore, I would like to emphasize the life-threatening nature of hypertensive encephalopathy, especially if brain stem edema is present. Treatment is available, however, and it is well tolerated (2). Because of this, the clinician must be informed of the MR findings as soon as possible. Lastly, in order to maintain a uniform nomenclature it might have been preferable to refer to the described entity as "hypertensive encephalopathy" not only in the text but in the title of their article as well.

A.J. Colon

*Atrium Medisch Centrum  
The Netherlands*

### References

1. de Seze J, Mastain B, Stojkovic T, Ferriby D, et al. **Unusual MR Findings of the Brain Stem in Arterial Hypertension.** *AJNR Am J Neuroradiol* 2000;21:391-394
2. Colon AJ. **Considérations sur l'Encéphalopathie Hypertensive d'après un cas atypique.** *Rev med Suisse Rom* 1998;118:505-507
3. Auer LM. **The Pathogenesis of Hypertensive Encephalopathy.** *Acta Neuroch* 1978;27:1-111
4. Kontos HA, Wei EP, Dietrich WD, et al. **Mechanisms of Cerebral Arteriolar Abnormalities after Acute Hypertension.** *Am J Physiol* 1981;240:H511-H527

### Imaging Macrophage Activity in the Brain by Using Ultrasmall Particles of Iron Oxide

We have read with great interest the two articles by Dousset et al reporting on the use of ultrasmall particles of iron oxide (USPIO) to detect macrophage activity in a rat model of experimental autoimmune encephalomyelitis (EAE) (1, 2). Iron oxides have now proved to be extremely sensitive contrast agents for MR imaging of blood-brain-barrier (BBB) disruption (3), with the exact cellular distribution within the brain parenchyma dependent on the type of particle (4).

We are concerned that using the term "imaging of macrophage activity" is misleading, because it

suggests uptake of USPIO in brain macrophages, which was not shown to occur in either of the articles by Dousset et al. Instead, the presented histopathologic characteristics, including iron-specific Prussian Blue stains and electron micrographs, demonstrate uptake of USPIO in endothelial cells (not macrophages), most likely as a result of a leaky BBB. Because such a leaky BBB is caused indirectly by the presence of macrophages, the term "imaging of macrophage activity" in itself is not technically incorrect, but it should have been made clear that it refers to the indirect effects of macrophages on the BBB.

As the authors point out in their articles, the integrity of the BBB can be a very transient and dynamic process. Therefore, the momentary lack of Gd-DOTA enhancement during the first 10 minutes after injection should not lead to a conclusion that no defects in the BBB were present over an extended period, with the implication that the USPIO must have been transported into the brain via cells (including macrophages). The blood half-life of USPIO in rats is over 5 hours; the prolonged intravascular presence of the particles offers a far greater window of opportunity to enter the brain through a momentary defect in the BBB (5).

Unlike the available mouse EAE models and the human disease multiple sclerosis (MS), the Lewis rat EAE model is histopathologically characterized by an abundance of macrophages with relatively few T cells present. It remains to be seen if the histopathologic observations in current ongoing clinical trials with USPIO in MS patients will be comparable with those obtained in the rat. If they turn out to be comparable, then it supports the hypothesis that the USPIO brain uptake is nonspecific through a leaky BBB, irrespective of the predominant inflammatory cell type. This very interesting article deserves further studies, but caution should be taken when interpreting the imaging findings.

Jeff W.M. Bulte

Joseph A. Frank

*Laboratory of Diagnostic Radiology Research  
National Institutes of Health  
Bethesda, MD*

### References

1. Dousset V, Ballarino L, Delalande C, et al. **Comparison of ultrasmall particles of iron oxide (USPIO)-enhanced T2-weighted, conventional T2-weighted, and gadolinium-enhanced T1-weighted MR images in rats with experimental autoimmune encephalomyelitis.** *AJNR Am J Neuroradiol* 1999;20:223-227
2. Dousset V, Delalande C, Ballarino L, et al. **In vivo macrophage activity imaging in the central nervous system detected by magnetic resonance.** *Magn Reson Med* 1999;41:329-333
3. Bulte JWM, DeJonge MWA, Kamman RL, et al. **Dextran-magnetite particles: contrast-enhanced MRI of blood-brain barrier disruption in a rat model.** *Magn Reson Med* 1992;23:215-223
4. Muldoon LL, Pagel MA, Kroll RA, Roman-Goldstein S, Jones RS, Newelt EA. **A physiological barrier distal to the anatomic**

blood-brain barrier in a rat model of transvascular delivery. *AJNR Am J Neuroradiol* 1999;20:217-222

5. Xu S, Jordan EK, Brocke S, et al. Study of relapsing remitting experimental allergic encephalomyelitis SJL mouse model using MION-46L enhanced in vivo MRI: early histopathologic correlation. *J Neurosci Res* 1998;52:549-558

### Reply

Bulte and Frank raise interesting questions about the positioning of USPIO in diseases in which macrophages are involved.

First, the cells that are displayed in the articles are clearly not endothelial cells, because they are located behind the basal membrane, which is the anatomic frontier used to differentiate endothelial cells and so-called pericytes from nonendothelial cells. They also have the typical form of macrophages; ie, they are ameboid, their cytoplasm is full of vesicles, and they have a large nucleus. Furthermore, the histologic examination with ED I antibody macrophage markers overlaid the sites of the abnormal signal on images.

Second, the images were performed 24 hours after IV injection, which is five times that of the blood half-life of the USPIO in rat. We agree with Bulte and Frank that the iron particles may have crossed the BBB during this window, but no particles were detectable in the extracellular space at the 24-hour electron microscopy examination. As we pointed out in the articles, an active cellular uptake of USPIO is necessary for the particles still to be present in the parenchyma after five blood half-lives. We also agree with Bulte and Frank that endothelial cells capture USPIO, although CNS endothelial cells have less capabilities of phagocytosis than other endothelial cells. It, however, is not the predominant phenomenon in models in which macrophages are involved (1-5). Macrophages are known to have the highest USPIO uptake, far beyond any other cells (6). This is well demonstrated for MR lymphography, where normal lymph node macrophages are filled by iron particles 24 hours after IV injection (7). In EAE, 24 hours after IV injection of USPIO, the major uptake is realized either by activated microglia (intrinsic macrophages) or by blood monocytes or both that have transported the USPIO (Trojan horse) in the site of inflammation through the BBB (1).

Third, it is very well known and established that macrophages are involved in all steps of the development of MS lesions (between 1997 and 1999, more than 140 scientific published articles were related to macrophages in MS). Macrophages accompany the lymphocytes during inflammation, they remove the myelin debris (lipid-laden macrophages), and they are present during the process of myelin repair (8). In such conditions, USPIO imaging may work on MS patients to display the lesions in which macrophages are active.

Fourth, in references 3 and 4 cited by Bulte and Frank, the animal models are traumatic (freezing) and osmotic models of BBB rupture, models in

which macrophages are lacking. Furthermore, in those experiments, imaging and histologic analysis were performed within 60 minutes after USPIO injection, which is very different from the 24 hours that we have proposed. Interestingly, in those experiments, USPIO were located on the basal membrane. Thus, this gives credit to the fact that macrophages are required to make the USPIO enter the brain parenchyma after several hours. In reference 5, quoted by Bulte and Frank, a mouse EAE model was tested and Xu et al noted that USPIO could be detected on Prussian blue iron stain in the vascular endothelium, the perivascular space, and in macrophages within perivascular cuffs and areas of inflammation and demyelination. Bulte and Frank are coauthors of the article. It is interesting to note that the MR studies were performed 6 hours after IV injection. In one rat only, they have performed an MR study 24 hours after injection, and they did not observe abnormalities. I would recommend to perform MR and histologic studies 24 hours after USPIO injection in more animals. With this scanning delay, I would not be surprised that USPIO will be found in macrophages and at much lower levels in the vascular endothelium. The scanning delay is critical for performing macrophage activity imaging (3).

USPIO will be available for human use soon, and it will be of a great interest to investigate the potential of this technique in diseases with active macrophages.

Vincent Dousset M.D., Ph.D.

Laboratory of Myelin Diseases Neurobiology  
University Victor Segalen Bordeaux 2  
Bordeaux France

### References

1. Dousset V, Ballarino L, Delalande C, et al. Comparison of ultrasmall particles of iron oxide (USPIO) T2-weighted, conventional T2-weighted and gadolinium-enhanced T1-weighted MR images in rats with experimental autoimmune encephalomyelitis. *AJNR Am J Neuroradiol* 1999;20:223-227
2. Dousset V, Delalande C, Ballarino L, et al. In vivo macrophage activity imaging in the central nervous system detected by magnetic resonance. *Magn Reson Med* 1999;41:329-333
3. Dousset V, Gomez C, Petry KG, Delalande C, Caillé JM. Dose and scanning delay using USPIO for central nervous system macrophage imaging. *MAGMA* 1999;8:185-189
4. Ruehm SG, Quick W, Corot C, et al. MR imaging of atherosclerotic plaque with ultrasmall superparamagnetic iron oxide (USPIO) in hyperlipidemic rabbits. Proceedings of the International Society for Magnetic Resonance in Medicine 1999;81 (Author please provide day, month, and site of conference.)
5. Hauger O, Delalande C, Trillaud R, et al. MR imaging of intrarenal macrophage infiltration in an experimental model of nephrotic syndrome. *Magn Reson Med* 1999;41:156-162
6. Weissleder R, Cheng H-C, Bogdanova A, et al. Magnetically labeled cells can be detected by MR imaging. *JMRI* 1997;7:258-263
7. Guimaraes R, Clément O, Bittoun J, Carnot F, Fria G. MR lymphography with superparamagnetic iron nanoparticles in rats: pathologic basis for contrast enhancement. *AJR Am J roentgenol* 1994;162:201-207
8. S. Brück W, Sommermeier N, Bergmann M, et al. Macrophages in multiple sclerosis. *Immunobiology* 1996;195:588-600

### **In Re: Histologic and Morphologic Comparison of Experimental Aneurysms with Human Intracranial Aneurysms**

A fundamental precept in education and science is that errors and misleading statements should not go unchallenged. This commentary aims to draw attention to unwarranted conclusions, methodological deficiency, and misrepresentations of the literature in two recent experimental investigations extolling the elastase infusion model of intracranial aneurysms (1, 2).

Cawley et al (1) produced 15 aneurysms in rabbits using the proximal 0.75 cm of the external carotid artery which was ligated distally. A catheter from the femoral artery inserted 0.5 cm into the sausage-shaped arterial stump was fastened by a cinch tie at the origin of the artery and the "aneurysm" emptied of blood was infused with varying doses of porcine pancreatic elastase for 45 minutes. The cinch tie and catheter were then removed and the femoral artery was ligated. The "aneurysms" were harvested 2 to 12 weeks postoperatively and only six were patent. Histologic loss of the elastic tissue, inflammatory cell infiltration, smooth muscle cell hyperplasia, and intimal fibrosis were found in all "aneurysm" walls, which allegedly were otherwise of normal arterial architecture. This contention could not be confirmed from the low magnification photomicrographs provided. Similar infusion of a segment of rat aorta by Halpern et al (3) resulted in dramatic medial necrosis, loss of both elastin and collagen, and a conspicuous pleomorphic inflammatory cell infiltration, increasing significantly during the 6 days of the experiment. Over this time, a dramatic activation of multiple endogenous proteinases was found, though these may have been associated with resolution and repair of the damage rather than pathogenic activity, causing dilatation of the severely damaged wall.

Cawley et al (1) were not justified in claiming to have produced true arterial saccular aneurysms with degeneration of elastic laminae or that the aneurysm more closely approximated the pathophysiology of naturally occurring cerebral aneurysms. The endothelium in the arterial stumps was allegedly "undisturbed" despite the dissection, two ligatures, elastase infusion, anoxia for 45 minutes, and insertion and withdrawal of the catheter. No attempt was made to confirm the absence of traumatic artifact or to assess the effect of the perfusate on the endothelium. Thrombosis in 60% of their specimens contradicts their allegation of normal endothelium.

Rabbits in which aneurysms were produced bilaterally would be quite unacceptable for long-term studies because of the possible long-term deleterious secondary hemodynamic effects of bilateral internal carotid and femoral artery ligation.

In their second study (2) two experimental models of aneurysms were compared with human in-

tracranial aneurysms. The first model consisted of blind stumps of four ligated extracranial rabbit arteries created using the same elastase infusion technique as previously (1), a procedure far removed from the physiological conditions in which cerebral aneurysms develop and progress. There were no control animals. The severity of cellular and matrix damage incurred was unknown and histologic detail inadequately demonstrated. Such tissue requires more than an allocation of 2 weeks to recover, and the absence of intimal proliferation after such treatment is not surprising. The lesions in no way remotely resemble human cerebral aneurysms. The "thin wall" was actually thicker than that of the internal carotid artery in their photomicrograph and the discussion of thrombus and clot suggests confusion and lack of understanding of the structural differences. Thrombus does not form in a blind cul-de-sac *ex vivo* in the absence of flow.

Experimental venous pouch aneurysms (the second model) in adult pigs had thick walls, as expected in such a large animal (2). To suggest that gross fibromuscular intimal proliferation had developed and extended throughout the wall within 2 weeks is not believable. This is particularly so in view of considerable inflammatory cell infiltration and a prominent and intact internal elastic lamina and media were observed throughout the pouches. Substantial thrombosis was present in two venous pouch aneurysms, yet patency was alleged to be excellent in all four. The reported extensive mural inflammatory cell infiltration and thrombosis at 2 weeks are suggestive of severe damage, infection, or trauma. Significant mural thickening in venous pouch aneurysms occurs over several months as elastic tissue and muscle progressively disappear (4-7).

Fashioning an aneurysmal sac of a thin-walled vein in any species variously as a lateral, berry or fusiform (or spherical) aneurysm reproduces the hemodynamic conditions found in humans. Using a thin-walled vein of viable tissue is more physiological and valid for long-term experimental observations than their first model (1). The wall would be stronger (ie, more fatigue resistant) than that of weak-walled, early, spontaneous cerebral aneurysms in humans. Though the walls usually heal rapidly postoperatively as did control arteriotomies and phlebotomies in the same animals, aneurysms progressively develop atherosclerosis (histologically [4-7] and ultrastructurally [8]), and complications including mural tears, thrombi, and rupture over time (4, 5). Such changes do not represent adaptation but are responses to the degenerative effects of intraaneurysmal hemodynamic stresses.

Models must be suitable for studies of aneurysmal growth and behavior under physiological conditions analogous to those in humans. The authors (2) incorrectly alleged venous pouch aneurysms do not manifest the mural changes of true arterial aneurysms nor are their postoperative changes of only



2 weeks' duration indicative of behavioral changes in aneurysm models. I have never stated that venous pouch aneurysms develop extreme intimal proliferation within 2 weeks or that they progress to near obliteration. The authors also allege I denied enlargement of venous-pouch aneurysms when this is not correct (5).

In the second study (2), their knowledge of the structure of cerebral aneurysms is deficient, and expertise is not acquired from examining nonserial sections of five small sacs. Mural thickness in human aneurysms of the dimensions discussed varies substantially with site and plane of section. It is my opinion, based upon study of serial sections of 154 human cerebral aneurysms (9, 10), that the description and measurements of Abruzzo et al (2) are erroneous and reference 10 provides photomicrographs of 15 human cerebral aneurysms and of other small developing aneurysms. To allege intimal thickening is universally absent in human cerebral aneurysms is also false. A characteristic feature of cerebral aneurysms is intimal proliferation, which is a secondary formation with no media between it and the thinned adventitia. This was the feature that correlated with the medial raphe at branch sites and was used to provide spurious support to the now obsolete "congenital theory" (11). The loss of the internal elastic lamina and underlying media constitutes an "atrophic" lesion of atherosclerosis produced by the enhanced hemodynamic stress (12). The early elastic elements in the compensatory mural thickening (proliferative lesion of atherosclerosis) that follows is intimal proliferation in which the early elastic element soon undergoes progressive degeneration, as occurs in tiny experimental or naturally occurring aneurysmal sacs.

Mural thickness of the berry aneurysm wall at the neck or base differs according to the plane of section, tapering when the fork is cut longitudinally to provide Y-shaped sections, but not when cut in a plane at a right angle to the latter, as seems to be the case in the five human aneurysms of Abruzzo et al (2). Their Figure 5C does not appear to be a recently ruptured sac as alleged. The two large organized thrombi that incompletely filled the sac indicate the primary leakage was not recent, the mural thickness at that site being more than twice the mural thickness at any other location.

Cerebral berry aneurysms in humans develop and enlarge slowly over years (11) and neither of these experimental models (1, 2) reproduces the pathophysiological conditions occurring in the production of the human lesion nor can either be used to deduce their etiology.

The mean of three wall measurements does not represent the mean mural thickness of any aneurysm type. To compare mural thickness of three different aneurysmal types involving three different vessels in three different species and sizes of animals serves no useful purpose, and like other methodological deficiencies, is at variance with sound investigative procedure. Cawley et al and Abruzzo

et al (1, 2) published articles with poor design, misrepresentation of the literature, and little cognizance of the scientific method. In addition, my name was spelled incorrectly eight times (text and references) (2). More importantly, the conclusions and generalizations were unwarranted and misleading.

WE Stehbens, MD  
University of Otago  
Wellington School of Medicine  
Dept. of Pathology  
Wellington South, New Zealand

### References

1. Cawley CM, Dawson RC, Shergelaia G, Bonner G, Barrow DL, Colahan ART. **Arterial saccular aneurysm model in the rabbit.** *AJNR Am J Neuroradiol* 1996;17:176-1766
2. Abruzzo T, Shergelaia GG, Dawson RC, Owens DJ, Cawley CK, Gravanis MB. **Histologic and morphologic comparison of experimental aneurysms with human intracranial aneurysms.** *AJNR Am J Neuroradiol* 1998;19:1309-1314
3. Halpern VJ, Nackman GB, Gandhi RH, et al. **The elastase infusion model of experimental aortic aneurysms: synchrony of induction of endogenous proteinases with matrix destruction and inflammatory cell response.** *J Vasc Surg* 1994;20:51-60
4. Stehbens WE. **Chronic changes in the walls of experimentally produced aneurysms in sheep.** *Surg Gynec Obstet* 1979;149:43-48
5. Stehbens WE. **Histological changes in chronic experimental aneurysms surgically fashioned in sheep.** *Pathology* 1997;29:374-379
6. Stehbens WE. **Chronic changes in experimental saccular and fusiform aneurysms in rabbits.** *Arch Pathol Lab Med* 1981;105:603-607
7. Stehbens WE. **Chronic vascular changes in the walls of experimental berry aneurysms of the aortic bifurcation in rabbits.** *Stroke* 1981;12:643-647
8. Stehbens WE. **The ultrastructure of experimental aneurysms in rabbits.** *Pathology* 1985;17:87-95
9. Stehbens WE. **Histopathology of cerebral aneurysms.** *Arch Neurol* 1963;8:272-285
10. Stehbens WE. **Pathology of the Cerebral Blood Vessels.** St Louis, Missouri: CV Mosby, 1972:351-470
11. Stehbens WE. **Aneurysms.** In: *Vascular Pathology*. Stehbens WE, Lie JT, Eds. London, England: Chapman & Hall; 353-414
12. Stehbens WE. **Atherosclerosis and degenerative diseases of blood vessels.** In: *Vascular Pathology*. Stehbens WE, Lie JT, Eds. London, England: Chapman & Hall; 175-269

### Reply

Recent clinical reports have indicated an aneurysm recurrence rate of 15% following Guglielmi detachable coil (GDC) embolization (1). Future research must emphasize the development of biologically active embolization devices, which accelerate endoluminal fibrosis in cerebral aneurysms, to prevent recanalization. While animal studies employing vein pouch aneurysms have consistently revealed complete fibrous organization of endoaneurysmal thrombus within 6 months of GDC embolization, several human investigations have revealed persistence of unorganized thrombus in cerebral aneurysms for as long as 8 months (2-5). This discrepancy has raised serious questions about the validity of the vein pouch aneurysm model in neurointerventional research. Studies have shown

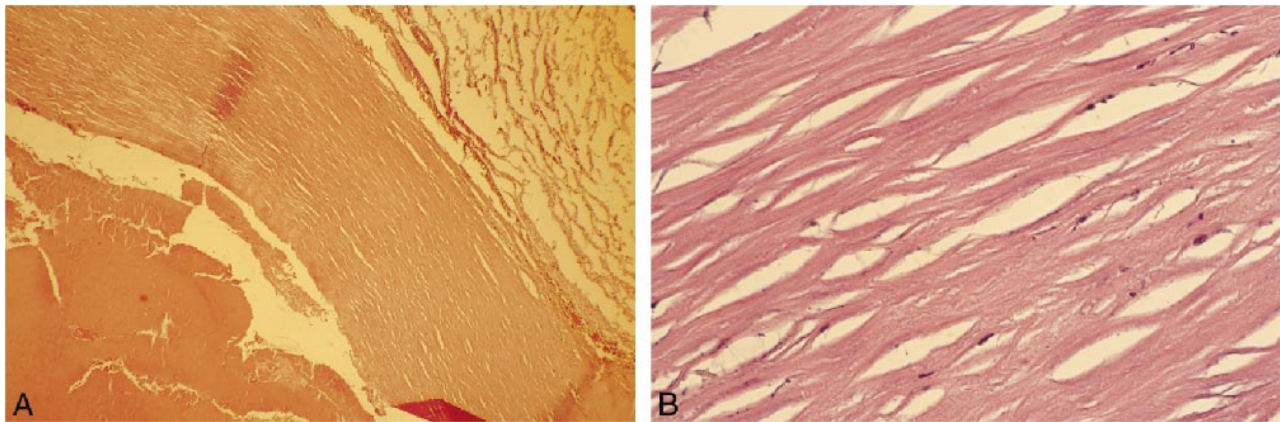


FIG 1. Longitudinal cross section of the wall of a human cerebral aneurysm (hematoxylin and eosin). A, Original magnification  $\times 40$ . B, Original magnification  $\times 20$ .

that vein pouch aneurysms have similar histologic responses to embolization devices, whether or not the devices are modified with biologically active materials (6). The results may simply reflect the exuberant fibrous tissue reaction of a healthy surgical wound to implantation of a foreign body. Current research objectives require a valid aneurysm model that can be easily reproduced.

Although the elastase infusion model does not approximate the pathophysiology of cerebral aneurysms in humans, neither does the vein pouch aneurysm model. Physiologic aneurysm models have been described by Hashimoto et al (7); however, these models are not practical for the study of endovascular occlusion devices. The rat model consists of vessels, and aneurysms too small to permit endovascular embolization. The primate model is impractical as a result of the long latency period for aneurysm formation (1 year). In addition, both of Hashimoto's models are inefficient, resulting in aneurysm formation in only 10–40% of animals.

Stehbens doubts that aneurysmal arterial lesions can be created with elastase. Numerous investigators have reported the formation of aneurysms following elastase digestion of the arterial wall (8–

11). Although Cawley et al did not use controls to assess the effects of elastase and exclude the possibility of traumatic artifact, the controlled series of experiments recently conducted by Cloft et al (9, 11) should dispel any notion that the morphologic and histologic changes produced by elastase infusion represent a form of artifact.

Although, Stehbens contends that “fashioning an aneurysmal sac” as a “lateral, berry, or fusiform aneurysm reproduces the hemodynamic condition found in humans,” laboratory studies conducted by Strother et al (12) have proven otherwise. In experimental terminal and bifurcation aneurysms, Strother et al found rapid flow, without vortex formation or endosaccular stasis. In contrast, they found central vortex formation with prolonged endosaccular stasis, lasting up to several minutes, in side-wall aneurysms. Kerber et al (13) illustrated how the orientation of the aneurysmal ostia to slip-stream vectors in the parent artery determine whether or not an incompletely occluded aneurysm will continue to grow and rupture. Graves et al (14) have shown that hemodynamic forces strongly affect the compaction and migration of embolic agents in the sac of experimental aneurysms. The

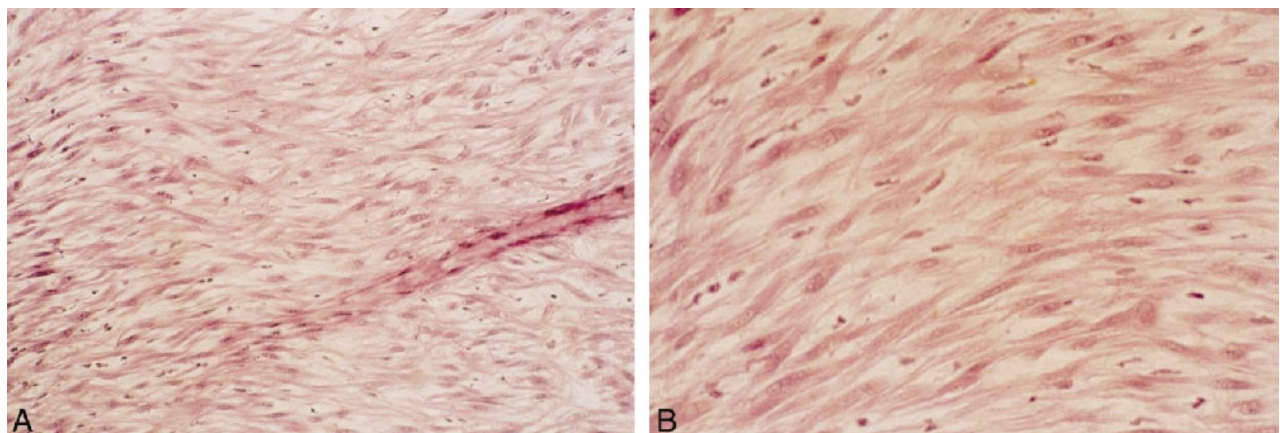


FIG 2. Longitudinal cross section of the wall of a swine vein pouch aneurysm (hematoxylin and eosin). A, Original magnification  $\times 20$ . B, Original magnification  $\times 40$ .



technical success of embolization in a side-wall model cannot be extrapolated to the clinical setting because the hemodynamic vectors that effect coil migration, coil compaction, persistent flow into incompletely occluded sacs, and formation of thromboemboli are disparate.

We did not allege that Stehbens denied enlargement of vein pouch aneurysms. We did indicate that his reports of enlargement contradicted the findings of other investigators (8). Although Stehbens claims that he observed progressive enlargement of vein pouch aneurysms, he never performed serial angiography (15–17). Others have failed to demonstrate expansion of vein pouch aneurysms when serial angiography was performed (18).

A major difference between human cerebral aneurysms and vein pouch aneurysms that cannot be easily reconciled is the vast difference in saccular structure. Human cerebral aneurysms are thin walled, acellular structures (Fig 1A and B). Although Stehbens argues that the morphologic measurements of human aneurysms we reported are erroneous, our measurements agree closely with those published by Suzuki and O'Hara (19) in their study of 45 human cerebral aneurysms. Although it is true that the walls of some aneurysms thicken as the sac undergoes expansion, and mural tears develop, leading to the intramural deposition of fibrin and foci of intimal hyperplasia, most cerebral aneurysms possess strikingly acellular sacs (19, 20). Stehbens (21) has previously reported that "larger and presumably older sacs usually had relatively acellular walls". It is misleading to suggest that intimal hyperplasia within aneurysms is "characteristic." In striking contrast, the walls of vein pouch aneurysms are uniformly cellular (Fig 2A and B). When comparing vein pouch aneurysms to human cerebral aneurysms, it is particularly troublesome that 27% of the vein pouch aneurysms in one series reported by Stehbens underwent osseous metaplasia (17).

Stehbens denies stating that intimal proliferation develops in vein pouch aneurysms within 2 weeks. However, he has previously published that "within 2 weeks, there was considerable intimal thickening of the sac wall with stellate cells and abundant intercellular matrix as if edematous" (15). Furthermore, according to his own observations, vein pouch aneurysms developed "hypertrophy of medial bundles of muscle" within 2 weeks of grafting (15). Stehbens also wrote that within 11 days "intimal thickening was present in both venous and arterial segments of the aneurysm" (17). Other investigators have reported that intimal hyperplasia in vein grafts develops as early as 3–5 days after grafting, and increases rapidly during the first 7 days (22).

Regarding the criticism that interspecies comparison of pathologic models is without meaning, we would like Stehbens to consider that all animal models of disease are developed for comparison to the human condition. We have selected rabbits as

the species for our elastase aneurysm model because the carotid artery approximates the size of the human middle cerebral artery, enabling a more realistic assessment of microcatheter interventions. We employed the swine vein pouch aneurysm in our study because it has become entrenched in the literature as the favored model. We believe that creation of vein pouch aneurysms in rabbits is more difficult and less reliable. In a rabbit model of vein pouch aneurysms, Spetzger et al reported a 24% operative mortality, a 24% technical failure rate secondary to thrombosis of the parent artery, and procedure times routinely exceeding 3 hours (18). Currently, in our laboratory, rabbit carotid artery aneurysms are created in less than 60 minutes by using elastase infusion, with uniform technical success and minimal mortality.

Stehbens points out that our recent comparison of experimental aneurysms to human intracranial aneurysms was without controls. We hope that our readers understand the difference between a comparative study and a controlled scientific experiment, and appreciate that each is a form of scientific inquiry. Stehbens suggests that the human aneurysm depicted in Figure 5 of our recent report could not have ruptured "recently," since it contained organizing thrombus near the rupture site. However, organization of the thrombus that seals the site of rupture in human cerebral aneurysms is completed within 3 weeks (19). Stehbens confuses the meaning of angiographic patency by criticizing our reporting of "excellent patency" as being inconsistent with our microscopic findings (8). We have used the terms thrombus and clot to describe the material in the lumina of vein pouch aneurysms, since the material has features of both. We stand by our study design and results. We would like to apologize for any spelling errors and paraphrases that may have been perceived as misquotes.

Todd Abruzzo, M.D.

Harry J. Cloft, M.D., Ph.D.

George G. Shengelaia, M.D.

Emory University School of Medicine  
Atlanta, Georgia

## References

1. Byrne JV, Sohn MJ, Molyneux MB. Five year experience in using coil embolization for ruptured intracranial aneurysms: outcomes and incidence of late rebleeding. *J Neurosurg* 1999; 90:656–663
2. Guglielmi G, Vinuela F, Sepetka I, et al. Electrothrombosis of saccular aneurysms via endovascular approach. Part I: Electrochemical basis, technique and experimental results. *J Neurosurg* 1991;75:1–7
3. Mawad ME, Mawad JK, Cartwright J, Jr, et al. Long term histopathologic changes in canine aneurysms embolized with Guglielmi Detachable Coils. *AJNR Am J Neuroradiol* 1995; 16:7–13
4. Tenjin H, Fushiki S, Nakahara Y, et al. Effect of Guglielmi Detachable Coils on experimental carotid artery aneurysms in primates. *Stroke* 1995;26:2075–2080

5. Manabe H, Fujita S, Hatayama T, Suzuki S, Yagihashi S. **Rerupture of coil embolized aneurysm during long term observation.** *J Neurosurg* 1996;88:1096–1098
6. Murayama, Y, Vinuela F, Suzuki Y, et al. **Ion implantation and protein coating of detachable coils for endovascular treatment of cerebral aneurysms: concepts and preliminary results in swine models.** *Neurosurgery* 1997;40:1233–1244
7. Hashimoto N, Kim C, Kikuchi H, Kojima M, Kang Y, Hazama F. **Experimental induction of cerebral aneurysms in monkeys.** *J Neurosurg* 1987;67:903–905
8. Abruzzo T, Shengelaia GG, Dawson RC, III, Owens DS, Cawley CM, Gravanis MB. **Histologic and morphologic comparison of experimental aneurysms with human intracranial aneurysms.** *AJNR Am J Neuroradiol* 1998;19:1309–1314
9. Cawley CM, Dawson RC III, Shengelaia GG, Bonner G, Barrow DL, Colohan RT. **Arterial saccular aneurysm model in the rabbit.** *AJNR Am J Neuroradiol* 1996;17:1761–1766
10. Miskolczi L, Guterman LR, Flaherty JD, Hopkins LN. **Saccular aneurysm induction by elastase digestion of the arterial wall: a new animal model.** *Neurosurgery* 1998;43:595–600
11. Cloft HJC, Altes TA, Marx WF, et al. **Endovascular creation of *in vivo* bifurcation aneurysm model in rabbits.** *Radiology* 1999; 213:223–228
12. Strother CM, Graves VB, Rappe A. **Aneurysm hemodynamics: an experimental study.** *AJNR Am J Neuroradiol* 1992;13: 1089–1095
13. Kerber CW, Hecht ST, Knox K, Buxton RB, Meltzer HS. **Flow dynamics in a fatal aneurysm of the basilar artery.** *AJNR Am J Neuroradiol* 1996;17:1417–1421
14. Graves VB, Strother CM, Partington CR, Rappe A. **Flow dynamics of lateral carotid artery aneurysms and their effects on coils and balloons: an experimental study in dogs.** *AJNR Am J Neuroradiol* [year];13:189–196
15. Stehbens WE. **Chronic changes in the walls of experimentally produced aneurysms in sheep.** *Surg, Gyn, Obs* 1979;149:43–48
16. Stehbens WE. **Chronic vascular changes in the walls of experimental berry aneurysms of the aortic bifurcation in rabbits.** *Stroke* 1981;12:643–647
17. Stehbens WE. **Chronic changes in experimental saccular and fusiform aneurysms in rabbits.** *Arch Pathol Lab Med* 1981;105: 603–607
18. Spetzger U, Reul J, Weis J, Bertalanffy H, Thron A, Gilsbach JM. **Microsurgically produced bifurcation aneurysms in a rabbit model for endovascular coil embolization.** *J Neurosurg* 1996; 85:488–495
19. Suzuki J, O'Hara H. **Clinicopathological study of cerebral aneurysms.** *J Neurosurg* 1978;48:505–514
20. Maurice-Williams RS. **Subarachnoid Haemorrhage, Aneurysms and Vascular Malformations of the Central Nervous System.** Bristol: Wright;1987:25–48
21. Stehbens WE. **Histopathology of Cerebral Aneurysms.** *Archives of Neurology* 1963;8:56–59
22. Zwolak RM, Adams MC, Clowes AW. **Kinetics of vein graft hyperplasia: association with tangential stress.** *J Vasc Surg* 1987;5:126–136