



## Discover Generics

Cost-Effective CT & MRI Contrast Agents



WATCH VIDEO

# AJNR

## CNS Involvement of Virus-associated Hemophagocytic Syndrome: MR Imaging Appearance

Kirsten P.N. Forbes, Donald A. Collie and Alistair Parker

*AJNR Am J Neuroradiol* 2000, 21 (7) 1248-1250

<http://www.ajnr.org/content/21/7/1248>

This information is current as of June 6, 2025.

## Case Report

# CNS Involvement of Virus-associated Hemophagocytic Syndrome: MR Imaging Appearance

Kirsten P.N. Forbes, Donald A. Collie, and Alistair Parker

**Summary:** The MR imaging appearance of a case of virus-associated hemophagocytic syndrome complicated by diffuse CNS infiltration is presented. Virus-associated hemophagocytic syndrome is a rare condition, precipitated by viral infection and characterized by proliferation of benign histiocytes with phagocytosis. In severe cases, the CNS may be involved.

### Case Report

A 22-year-old man was admitted to a neurologic unit with a history of deteriorating visual acuity and progressive lower limb numbness and weakness. He had a known history of virus-associated hemophagocytic syndrome that was previously diagnosed based on bone marrow aspirate (Fig 1). He had experienced multiple relapses and remissions affecting bone marrow and liver, which were successfully treated with courses of immunosuppression.

An examination revealed evidence of a spastic paraparesis, with a sensory level at T10. Ophthalmoscopy revealed bilateral optic atrophy. The remainder of the cranial nerves was normal, and no cerebellar signs were elicited. Laboratory investigation of the CSF revealed an elevated protein level (10.4 g/L) and 5 WBC/mm<sup>3</sup>.

MR imaging of the brain showed diffuse white matter changes throughout the brain and cervical spine, without mass effect. The administration of contrast material revealed extensive leptomeningeal enhancement, with additional enhancement of the cerebral perivascular spaces (Fig 2). Despite management with high-dose immunosuppression, neurologic symptoms progressed during the next year to involve the cerebellum and lower cranial nerves.

### Discussion

Viral infection of immunocompromised patients may result in benign proliferation of tissue histiocytes showing hemophagocytosis, which is termed *virus-associated hemophagocytic syndrome* (1). It is thought that viral infection provokes an abnormal immune response, resulting in secretion of cytokines, including macrophage colony stimulating factor, by T-helper cells. This results in massive histiocytic proliferation and indiscriminate phago-

cytosis of both erythrocytes and white blood cells (2). Viruses implicated include Epstein-Barr virus, human herpesvirus 6, and cytomegalovirus (3), although bacteria and parasites may also rarely induce a similar syndrome. Histiocytic proliferation characteristically occurs in the liver, spleen, and bone marrow, although it may, in severe cases, be seen in other organs, such as the brain, lungs, and heart.

The syndrome begins after a short history of a nonspecific viral illness, commonly resulting in pyrexia, hepatosplenomegaly, and pancytopenia (2). The disease may follow a relapsing and remitting course or progress rapidly to multiorgan failure and death. Virus-associated hemophagocytic syndrome should be distinguished from familial hemophagocytic lymphohistiocytosis (4), which is an autosomal recessive condition that presents with similar symptoms and pathologic features in early childhood and runs a more severe course. For pathologic categorization, both conditions are classed together because of common microscopic findings (5).

With CNS involvement, infiltration of leptomeninges by lymphocytes and erythrophagocytic histiocytes is commonly seen (6, 7). This is associated with a sterile CSF lymphocytosis with elevated protein levels (8). With more severe involvement, infiltrates extend into the perivascular spaces, where they elicit reactive astrocytic and microglial cell proliferation (8). Massive tissue infiltration

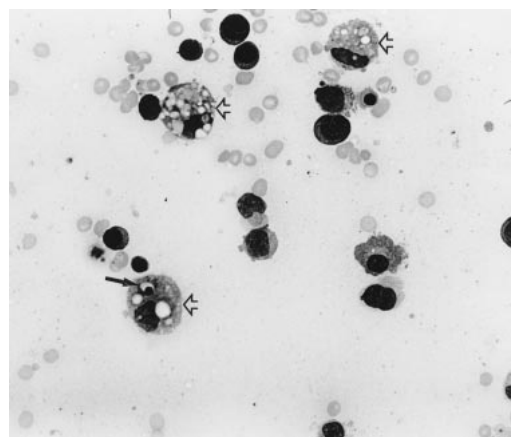


FIG 1. Marrow aspirate of patient with virus-associated hemophagocytic syndrome (hematoxylin and eosin; original magnification,  $\times 100$ ). Multiple macrophages (open arrows) show ingestion of erythrocytes and cell debris. In addition, one macrophage has ingested a nucleated white blood cell (black arrow).

Received June 3, 1999; accepted after revision February 8, 2000.

From the Departments of Hematology (A.P.) and Neuroradiology (K.P.N.F., D.A.C.), Western General Hospital, Edinburgh, Scotland.

Address reprint requests to D.A. Collie, MD, Department of Neuroradiology, Western General Hospital, Crewe Road South, Edinburgh, EH4 2XU, Scotland.

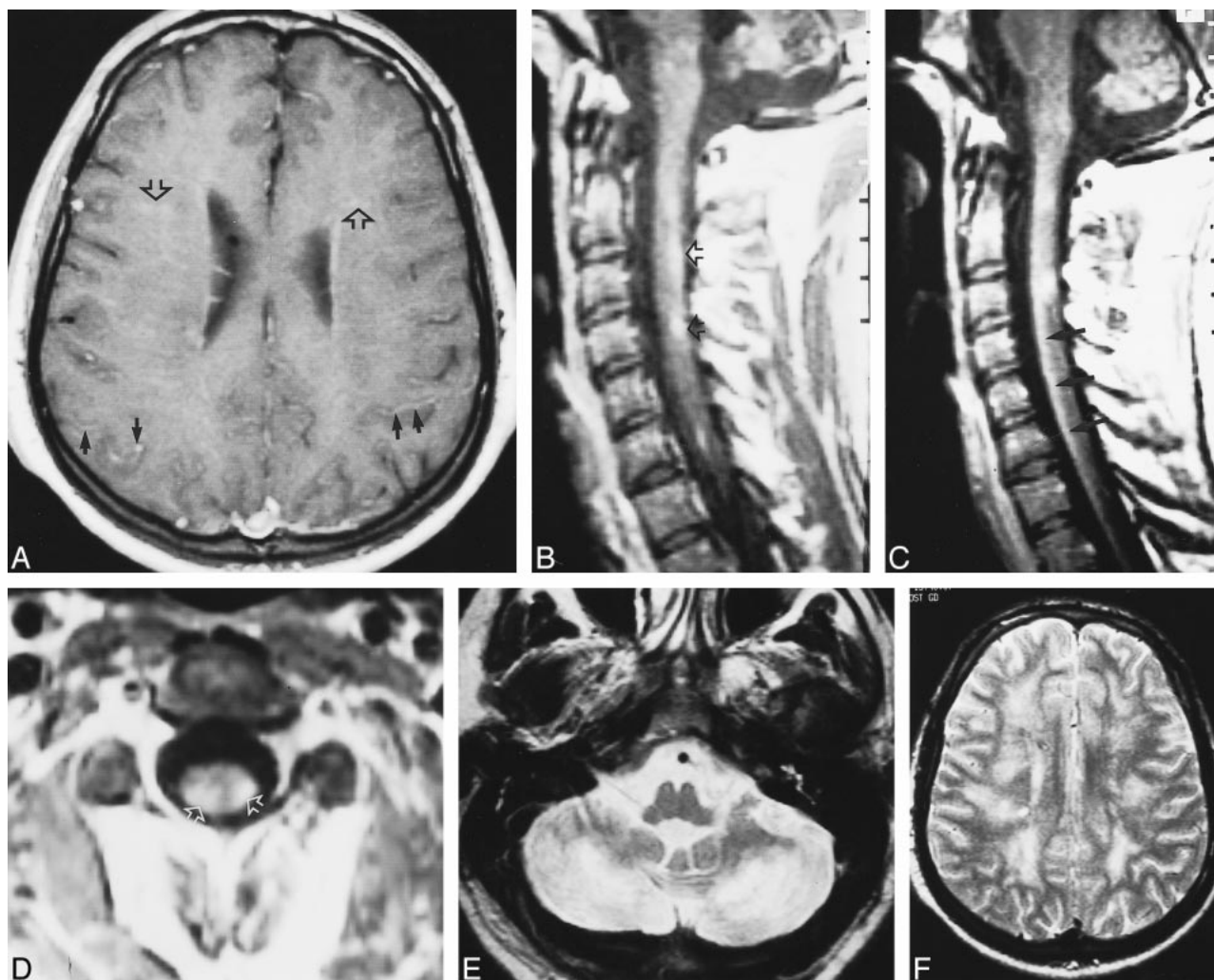


FIG 2. CNS involvement of viral-associated hemophagocytic syndrome.

A, Axial-view contrast-enhanced T1-weighted MR image of the cerebrum. Pial enhancement can be seen (*black arrow*). Additional enhancement of the Virchow-Robin perivascular spaces (*open arrow*) occurred because of extensive infiltration by lymphocytes and hemophagocytic histiocytes.

B and C, Sagittal-view contrast-enhanced T1-weighted MR images of the cervical cord. Enhancement of the Virchow-Robin perivascular spaces of the cervical cord white matter (*open arrow*) occurred because of extensive infiltration by lymphocytes and hemophagocytic histiocytes. Pial enhancement can be seen in the anterior cord (*black arrow*).

D, Axial-view contrast-enhanced T1-weighted MR image of the cervical cord at the C3 level. Enhancement of the white matter (*open arrow*) occurred because of extensive infiltration by lymphocytes and hemophagocytic histiocytes.

E, Axial-view T2-weighted MR image shows marked hyperintensity of the cerebellar hemispheres, presumed to be caused by secondary demyelination.

F, Axial-view T2-weighted MR image of the cerebrum shows that similar diffuse cerebral hemispheric white matter high signal changes are also present with no mass effect.

may follow, particularly affecting the white matter and occasionally resulting in areas of necrosis (6, 7). In addition to cellular proliferation, evidence of hemophagocytosis may also be seen. In a few cases, perivascular demyelination has been recorded, prompting comparison with postinfective or vaccination encephalomyelitis (9).

MR imaging findings of the brain in this case of virus-associated hemophagocytic syndrome correlate well with those of previous pathologic studies and with findings in cases of familial hemophagocytic lymphohistiocytosis. The presence of diffuse

leptomeningeal and perivascular enhancement is likely an indication of the extent of infiltration by lymphocytes and histiocytes. Furthermore, the widespread nature of white matter changes in the cerebrum, cerebellum, and cervical cord most likely reflect the presence of widespread tissue infiltration, perhaps associated with demyelination. It is suggested that virus-associated hemophagocytic syndrome should be added to the differential diagnosis of leptomeningeal and perivascular space enhancement, particularly if diffuse white matter changes are seen.

## References

1. Risdall RJ, McKenna RW, Nesbit ME, et al. **Virus-associated hemophagocytic syndrome: a benign histiocytic proliferation distinct from malignant histiocytosis.** *Cancer* 1979;44:993–1002
2. Tsuda H, Shirono K. **Successful treatment of virus-associated haemophagocytic syndrome in adults by cyclosporin A supported by granulocyte colony-stimulating factor [comment].** *Br J Haematol* 1997;97:508–510
3. Janka G, Imashuku S, Elinder G, Schneider M, Henter JJ. **Infection- and malignancy-associated hemophagocytic syndromes: secondary hemophagocytic lymphohistiocytosis.** *Hematol Oncol Clin North Am* 1998;12:435–444
4. Farquhar J, Claireaux A. **Familial haemophagocytic reticulosis.** *Arch Dis Child* 1952;519–525
5. Henter JJ, Elinder G, Ost A. **Diagnostic guidelines for hemophagocytic lymphohistiocytosis: The FHL Study Group of the Histiocyte Society.** *Semin Oncol* 1991;18:29–33
6. Akima M, Sumi SM. **Neuropathology of familial erythrophagocytic lymphohistiocytosis: six cases and review of the literature.** *Hum Pathol* 1984;15:161–168
7. Henter JJ, Nennesmo I. **Neuropathologic findings and neurologic symptoms in twenty-three children with hemophagocytic lymphohistiocytosis.** *J Pediatr* 1997;130:358–365
8. Haddad E, Sulis ML, Jabbou N, Blanche S, Fischer A, Tardieu M. **Frequency and severity of central nervous system lesions in hemophagocytic lymphohistiocytosis.** *Blood* 1997;89:794–800
9. Martin JJ, Cras P. **Familial erythrophagocytic lymphohistiocytosis: a neuropathologic study.** *Acta Neuropathol (Berl)* 1985;66:140–144