



**Providing Choice & Value**

Generic CT and MRI Contrast Agents



**FRESENIUS  
KABI**

**CONTACT REP**

**AJNR**

**A New Sonographic Technique for Assessing  
Carotid Artery Disease: Extended-Field-of-View  
Imaging**

Yoshie Hara, Mitsugu Nakamura and Norihiko Tamaki

*AJNR Am J Neuroradiol* 1999, 20 (2) 267-270

<http://www.ajnr.org/content/20/2/267>

This information is current as  
of July 29, 2025.

# A New Sonographic Technique for Assessing Carotid Artery Disease: Extended-Field-of-View Imaging

Yoshie Hara, Mitsugu Nakamura, and Norihiko Tamaki

**Summary:** We describe a new sonographic technique, extended-field-of-view imaging, and its clinical application for carotid artery disease. The technique identifies identical structures on two successive images for position registration to make a panoramic image in real time without position sensors. In 39 of 41 subjects, this technique provided high-quality panoramic images that could not be obtained with conventional real-time sonography, and made findings in the carotid artery more interpretable.

Compared with other imaging examinations, such as CT angiography and MR angiography, sonography is superior for evaluating pathologic changes of the intimal and medial layers of the carotid artery (1–6). However, the field of view (FOV) of a real-time sonogram is limited by the probe width, which is typically 4 to 6 cm. When larger or longer structures, like the carotid artery, are imaged with conventional real-time sonography, the examiner must piece together multiple frames to document the entire structure and to locate lesions within the relevant anatomic regions.

The extended-FOV imaging technique provides high-quality panoramic B-mode images in real time by free-hand scanning with standard probes. We applied this technique to the detection of carotid artery disease.

## Methods

### *Extended-FOV Imaging Technique*

Extended-FOV imaging software (SieScape; Siemens Medical Systems, Issaquah) was implemented on an all-digital real-time sonographic imaging system (Sonoline Elegra; Siemens Medical Systems) equipped with a specialized integrated programmable image processor, which uses a digital signal-processing tip. All scans were obtained with a hand-held linear-array probe with a footprint 4 cm in length (7.5 L40; Siemens Medical Systems) operated at 9 MHz. No positioning devices, such as articulated arms or position sensors, were applied to the sonographic probe for image acquisition or reconstruction.

This technique identifies identical structures that appear on two successive sonograms for position registration, and real-

time images are reconstructed to make a panoramic, extended-FOV along the long axis of the sonographic probe (7). While the operator moves the transducer slowly in the lateral direction over the region of interest, a programmable image processor integrated into the sonographic scanner estimates probe motion from sequentially acquired frames and reconstructs a large panoramic compound image in real time. Extended-FOV imaging relies on the similarity of imaging features within the area of overlap between successive imaging frames (k-1) and (k). To measure the geometric transformation between the two frames, frame (k) is divided into a grid of small nonoverlapping blocks. A minimum-sum absolute-difference search strategy is used to compute how each block must be shifted in order to match it with the corresponding block in the previous frame (k-1). A local vector describing this shift is assigned to each block. From the local motion vectors, a global transformation (translocation and rotation) is then calculated to describe the motion of the transducer from frame (k-1) to frame (k). Using the global motion information from each frame, the software smoothly blends the individual frames in a successive manner to generate the composite panoramic image. The in-process panoramic image has two portions: a real-time portion, which advances with the probe motion, and a static portion, which is the blended compound image from previous probe locations. When the scanning process is finished, the real-time portion is frozen and blended with the static portion to generate the total composite image. The algorithm allows the operator to halt during forward transducer movement or to move backward to correct part of the acquired composite image. SieScape imaging software can create extended-FOV images from regions up to 60 cm in length. Together with the final composite image, the multiple original frames that form the panoramic image are stored in the scanner's cine memory. The operator can select an individual image from the cine memory and display it side by side with the panoramic image.

### *Subjects*

Thirty-six patients and five healthy volunteers underwent sonographic examination using the extended-FOV technique for both carotid arteries. The patients included 11 with cerebral infarction, seven with brain tumors, seven with dural arteriovenous fistulas, five with cerebral aneurysms, two with acute cervical internal carotid artery (ICA) occlusion, two with cervical spondylosis, one with cerebral arteriovenous malformation, and one with Moyamoya disease. Of 36 patients, 27 had undergone digital subtraction catheter angiography (DSA). Both common carotid arteries (CCAs) were selectively catheterized and filming was done in the anteroposterior and lateral planes. MR angiography was performed in 10 patients. Both DSA and MR angiography were performed in nine patients (see Table). One patient underwent carotid endarterectomy on one side 4 months before the sonographic examination.

The volunteers and patients were positioned supine with the neck extended and rotated to the opposite side. The CCA, carotid bifurcation, and cervical ICA were scanned through an anterior oblique or posterior longitudinal approach. Conventional B-mode and color Doppler sonography were performed in all subjects. B-mode and extended-FOV sonograms were

Received February 9, 1998; accepted after revision July 20, 1998.

From the Department of Neurosurgery, Kobe University School of Medicine, 7-5-7 Kusunoki-cho, Chuo-ku, Kobe, 650, Japan.

Address reprint requests to Yoshie Hara, MD.

© American Society of Neuroradiology

**Normal and abnormal findings of the carotid artery as shown by extended-FOV sonography, conventional B-mode sonography, DSA, and MR angiography**

Methods		Normal	Abnormal
Sonography only (26 arteries)	Extended-FOV	19	7
	B-mode	19	7
Sonography + DSA (32 arteries)	Extended-FOV	28	4
	B-mode	28	4
	DSA	31	1
Sonography + MR angiography (two arteries)	Extended-FOV	2	0
	B-mode	2	0
	MR angiography	2	0
Sonography + DSA + MR angiography (18 arteries)	Extended-FOV	10	8
	B-mode	10	8
	DSA	11	7
	MR angiography	11	7
		59	19

Note.—FOV indicates field of view; DSA, digital subtraction angiography.

reviewed by a single observer who was not present at the examination and who was blinded to clinical information and results of other imaging studies. In each subject, three different conventional B-mode images showing the CCA, the bifurcation, and the ICA were printed for review. Three extended-FOV images with different original frames were also printed, and these two series of sonographic images of all subjects were reviewed randomly. Intimal thickening, plaque, and luminal stenosis were considered abnormal sonographic findings, and the extent of the lesion was reported. DSA and MR angiograms were reviewed by another observer who was unaware of the sonographic findings. Any stenosis detected on DSA or MR angiograms was reported as abnormal.

## Results

High-quality extended-FOV images were successfully acquired in 39 of 41 patients (78 carotid arteries). In two patients with acute carotid artery occlusion, extended-FOV imaging was not successful owing to patient motion, and these were eliminated from the study. Wavelike deformity of the arterial wall resulting from arterial pulsation was observed in 16 arteries (10 subjects). Because this did not cause total image distortion, these patients were enrolled in the study. The CCA, bifurcation, and proximal ICA were displayed on a single extended-FOV image in 39 subjects. In eight subjects, the proximal external carotid artery was also displayed in the same FOV (Fig 1). Total examination time was 18 to 43 minutes (mean, 25 minutes) when conventional B-mode, extended-FOV, and color Doppler imaging were performed on both sides in one subject.

In all healthy volunteers, a normal double-line pattern of the carotid artery was seen on the extended-FOV images. Among the 68 carotid arteries of the 34 patients, 19 arteries in 14 patients showed abnormal findings. Of these, two arteries had irregular intimal thickening without luminal stenosis and eight had atheromatous plaques without luminal stenosis. Seven arteries had atheromatous plaques with less than 40% luminal stenosis (Fig 2). Two had more than 40% luminal stenosis.

Conventional B-mode scanning was successful in all 39 cases. Although extended-FOV imaging did not fail to depict the abnormal findings that were seen on conventional B-mode images (Table), the extent of the lesion was documented differently in six arteries (three with intimal thickening and three with plaque with luminal stenosis). The lesion appeared to involve a shorter segment on conventional B-mode images than on the extended-FOV images.

Fifty arteries were imaged with both DSA and extended-FOV sonography. The sensitivity of extended-FOV sonography was 100% and the specificity was 90.5% when catheter angiography was considered as the reference. Twenty arteries were imaged with both extended-FOV sonography and MR angiography. The sensitivity of extended-FOV sonography was 100% and the specificity was 92.3% when MR angiography was considered as the reference.

## Discussion

In conventional real-time sonography, because of the limited FOV, the examiner usually moves the hand-held probe back and forth to observe the total anatomy and to understand the anatomic relationships between the imaged structures. After the examination, it can be quite difficult for a person who was not present during the examination to piece together the individual frames and to derive an accurate representation of the total picture. Previously reported techniques for extended-FOV imaging have required bulky mechanical arms or position sensors for position registration, and these devices made scanning less flexible and even hazardous (8, 9). Furthermore, image reconstruction was not in real time, which made the technique impractical (10).

The extended-FOV imaging technique with the use of SieScape software has accomplished two goals of clinical imaging: free-hand scanning and

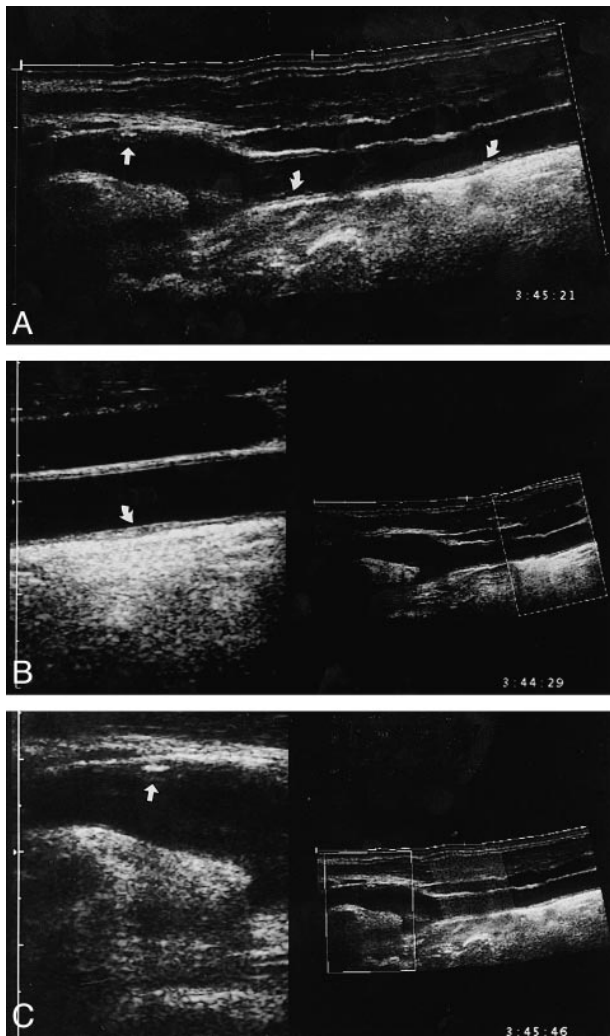


FIG 1. A, Composite extended-FOV image in a patient with cervical spondylosis shows a partially hyperechoic plaque at the ICA (straight arrow). Note mild hyperplasia of the intima at the CCA and bifurcation (curved arrows).

B, Extended-FOV image with a selected original frame provides a more precise picture of the CCA. Intimal hyperplasia was detected (left, arrow). The dotted square on the extended-FOV image (right) represents the position of the original frame displayed on the left.

C, Selected original frame of the ICA shows a hyperechoic plaque (left, arrow).

real-time reconstruction. By free-hand scanning with a standard probe, the examiner can trace the long course of the cervical carotid artery easily and accurately, which results in a larger FOV without image distortion. Real-time reconstruction saves examination time and makes the technique practical for clinical use. With this technology, the CCA, the bifurcation, and the cervical ICA are displayed in a single, panoramic FOV. Since geometric measurement accuracy on SieScape images has been confirmed theoretically and experimentally (6), pathologic changes of the carotid artery, especially when it extends beyond the limited FOV of conventional B-mode images, can be correctly measured on the extended-FOV images. In this series, six arteries showed different findings on conven-

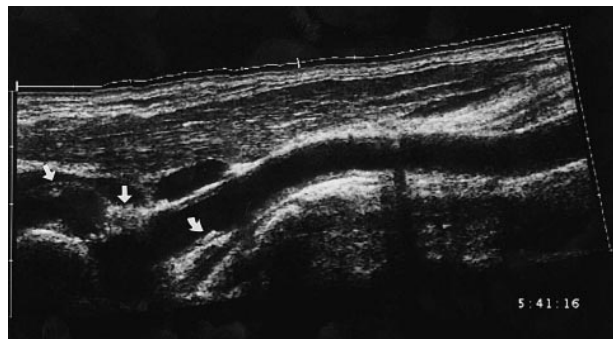


FIG 2. Extended-FOV sonogram shows atherosclerotic plaque at the carotid bifurcation that extended to the proximal ICA (straight arrows). The lumen was narrowed but the stenosis was less than 40%. Another small plaque was detected in the CCA (curved arrow). The normal double-line pattern was obscured at these sites of disease, and there was diffuse intimal hyperplasia at the CCA.

tional B-mode and extended-FOV images. We figured that because these lesions extended beyond the limited FOV of conventional B-mode images, and because the positional relationships between each frame were unknown to the observer, estimations of the size of the lesion became inaccurate on conventional B-mode images.

On the basis of our initial experience, we identified two problems with this technique. One is distortion of the reconstructed images due to motion. Patient motion, including respiratory movement and arterial pulsation, can cause misregistration of the acquired frames. Large-scale motion, such as head movement or respiratory movement, causes gross distortion on the extended-FOV images and discontinuity in images of the carotid artery (Fig 3A). Small-scale movement caused by arterial pulsation usually does not cause total image misregistration but results in wavelike deformity (Fig 3B). Since the arterial wall fluctuates synchronously with the arterial pulse, the diameter of the vessel changes during extended-FOV scanning. However, because these diameter changes show a regular pattern and are not associated with intimal thickening, one can readily differentiate them from real stenosis. For further clarification, one can review the original frames stored in the sonographic scanner's memory. To minimize motion artifacts, proper positioning of the patient's neck, and steady and smooth probe operation are essential. Because image reconstruction is performed in real time, one can detect distorted images instantly and repeat the image acquisition, thus reducing examination time.

Another important issue is that image registration and reconstruction are limited to a single plane produced by moving the probe along the longitudinal direction. Transverse, off-plane movement of the probe cannot be registered for image reconstruction and results in image distortion and measurement inaccuracy. Since the course of the carotid artery normally is not confined to a single plane, it is difficult and sometimes impossible to trace the full course of the artery with one-plane



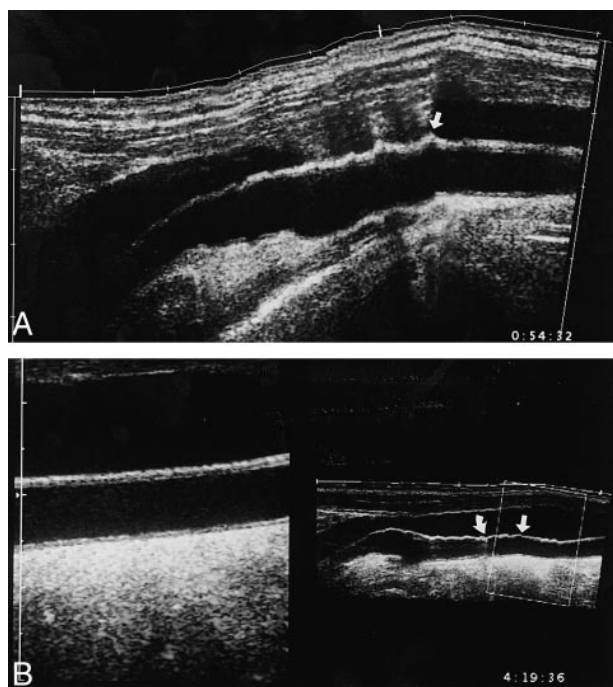


FIG 3. A, Extended-FOV image with unacceptable image distortion due to large-scale patient motion. Irregular deformity and discontinuity of the arterial wall make precise evaluation of the wall structure difficult (arrow). The FOV is not satisfactorily extended.

B, Extended-FOV image with mild distortion due to arterial pulsation (right). A regular waveform deformity is present on the wall of the CCA (right, straight arrow). There is also a discontinuity of the artery due to improper probe operation (right, curved arrow). The original frame is free from the motion artifact and shows the normal double-line pattern of the artery (left).

probe movement (11). If both the transverse and longitudinal probe motions were registered and 3D extended-FOV were possible, this technique would be even more useful clinically and the images even more interpretable.

Although no special training is required for experienced sonographers to obtain interpretable extended-FOV images, it is only after several examinations that the sonographer becomes used to this technique. Recently, color flow data and B-mode have become simultaneously available in extended-FOV imaging (Color SieScape; Siemens Medical

Systems), which makes tracing of the artery easier and enables evaluation of the vessel wall and blood flow on the same image.

The extended-FOV imaging technique can also be used with other standard transducers. Intraoperative extended-FOV imaging may provide precise information about the site, size, and degree of removal of lesions that are larger than the limited FOV of conventional B-mode images.

## Conclusion

The extended-FOV technique was able to provide more interpretable images of the carotid artery as compared with conventional B-mode images in real time without position sensors, and proved to be clinically useful.

## References

1. Arbeille P, Desombre C, Aesh B, Philippot M, Lapierre F. **Quantification and assessment of carotid artery lesions: degree of stenosis and plaque volume.** *J Clin Ultrasound* 1995;23:113-124
2. Fabris F, Poli L, Zanocchi M, Bo M, Fiandra U, Fonte G. **A four year clinical and echo graphic follow-up of asymptomatic carotid plaque.** *Angiology* 1992;43:590-598
3. Kallmes DE, Omary RA, Dix DE, Evans AJ, Hillman BJ. **Specificity of MR angiography as a confirmatory test of carotid artery stenosis.** *AJNR Am J Neuroradiol* 1996;17:1501-1506
4. Liberopoulos K, Kaponis A, Kokkinis K, et al. **Comparative study of magnetic resonance angiography, digital subtraction angiography, duplex ultrasound examination with surgical and histological findings of atherosclerotic carotid bifurcation disease.** *Int Angiol* 1996;15:131-137
5. Stensland-Bugge E, Bonna KH, Joakimsen O. **Reproducibility of ultrasonographically determined intima-media thickness is dependent on arterial wall thickness: the Tromso study.** *Stroke* 1997;28:1972-1980
6. Weng L, Tirumalai AP, Lowery CM, et al. **US extended-field-of-view imaging technology.** *Radiology* 1997;203:877-880
7. Massonneau M, Caillard P, de Chasse L, Mouren X, Thebault B, Cloarec M. **Short-term evaluation of plaque area measurement reproducibility from computer-assisted sonography.** *Angiology* 1995;46:375-381
8. Pretorius DH, Nelson TR, Jaffe JS. **3-dimensional sonographic analysis based on color flow Doppler and gray scale image data: a preliminary report.** *J Ultrasound Med* 1992;11:225-232
9. Holm HH, Kristensen JK, Rasmussen SN, et al. **Abdominal Ultrasound Static and Dynamic Scanning.** 2nd ed. Baltimore: University Park Press; 1980
10. Weng L, Tirumalai AP. **Method and Apparatus for Generating Large Compound Ultrasound Image.** U.S. patent 5 1996: 575, 286
11. Baba K, Okai T, Kozuma S, Taketani Y, Mochizuki T, Akahane M. **Real-time processable three dimensional US in obstetrics.** *Radiology* 1997;203:571-574

Please see the editorial on page 187 of this issue.