



Discover Generics

Cost-Effective CT & MRI Contrast Agents



FRESENIUS
KABI

WATCH VIDEO

AJNR

Dilated Venous Plexus of the Hypoglossal Canal Mimicking Disease

Stephen L. Stuckey

AJNR Am J Neuroradiol 1999, 20 (1) 157-158

<http://www.ajnr.org/content/20/1/157>

This information is current as
of June 5, 2025.

Dilated Venous Plexus of the Hypoglossal Canal Mimicking Disease

Stephen L. Stuckey

Summary: This article describes a case of prominent emissary veins of the hypoglossal canal protruding into the cerebellomedullary cistern mimicking disease, such as a nerve sheath tumor. The diagnosis and differentiation in this instance were confirmed by MR angiography and a review of alternative imaging planes. A diagnosis of hypoglossal canal lesions should be made with caution, as these lesions are quite rare, and vascular anomalies, such as those described, may mimic disease in this region.

The hypoglossal (or anterior condyloid) canal is infrequently the site of disease. It contains the rootlets of the hypoglossal nerve, emissary veins, and occasionally a branch of the ascending pharyngeal artery (1). The venous plexus of the hypoglossal canal, which may occasionally be a single vein, joins the sigmoidal sinus to the internal jugular vein with contributions from the basilar venous plexus and, also, according to our images, the upper cervical spine epidural plexus (2). Normal MR imaging appearances have been well described, and include enhancement, postulated to represent venous structures, and occasionally linear nonenhancing structures, thought to represent portions of the hypoglossal nerve (1). This article describes a case of marked asymmetrical protrusion of a vascular structure into the cerebellomedullary cistern immediately adjacent to the hypoglossal canal, illustrating a pitfall in the diagnosis of disease in this region.

Case Report

A 54-year-old man with a history of possible temporal lobe epilepsy underwent MR imaging, which showed a masslike region related to the intracranial aspect of the right hypoglossal canal, measuring approximately 1 cm in diameter isointense with cerebral cortex on T2-weighted images (Fig 1A). The patient was asked to return for a dedicated posterior fossa contrast-enhanced study, which showed the lesion protruding from the right hypoglossal canal into the right cerebellomedullary cistern (Fig 1B). A smaller, similar finding was noted in relation to the left hypoglossal canal (Fig 1C). The findings were thought to be a normal variant related to the emissary venous structures of the hypoglossal canal. Contrast-enhanced coronal images

also suggested these regions were contiguous with vascular structures, extending toward or away from the cervical epidural venous plexus (Fig 1D). One week later, the patient was examined with a modified MR angiographic technique to confirm the above diagnosis. A 2D time-of-flight MR angiogram without saturation bands obtained in the region of the skull base (Fig 1E) showed increased signal intensity within the region of interest, suggestive of flow within the lesion. Three-dimensional phase-contrast MR angiography was also performed with velocity encoding of 15 cm/s; however, this study did not show flow within either of the regions immediately medial to the hypoglossal canals, presumably reflecting extremely slow venous flow.

Discussion

The benefits of increased contrast resolution and multiplanar imaging capabilities of MR imaging in improving diagnostic capability have also led to numerous potential pitfalls in diagnosis (ie, normal appearances or normal variants mistakenly interpreted as disease). To consider contrast enhancement alone as proof of disease is fraught with danger, particularly in the region of the skull base, where there are many vascular structures. The case presented here clearly illustrates the need for caution despite the appearance of an enhancing mass protruding from a skull base foramen.

The normal MR imaging appearance of the hypoglossal canal has been well described (1). Included in this description was extension of enhancement extracranially beyond the bony canal. This case shows that the associated venous enhancement may protrude into the cerebellomedullary cistern, mimicking disease. One should, however, confirm that such findings do not relate to the patient's symptoms, as at least one case report has suggested that dilated venous structures within the hypoglossal canal may be symptomatic (3). The principal differential diagnostic possibilities include the presence of a nearby arteriovenous fistula with enlarged draining veins and a prominent venous plexus related to impaired jugular venous return. These possibilities may provide other imaging findings to suggest their presence, such as more widespread venous dilatation or direct evidence of a pathogenesis, such as internal jugular vein thrombosis. The nature of such a lesion is easily clarified by the addition of alternative imaging planes alone or in combination with flow-sensitive sequences.

Received February 9, 1998; accepted after revision May 12.

From the MRI Unit, The Alfred Hospital, Commercial Rd, Prahran 3181, Australia.

Address reprint requests to Dr. Stephen L. Stuckey.

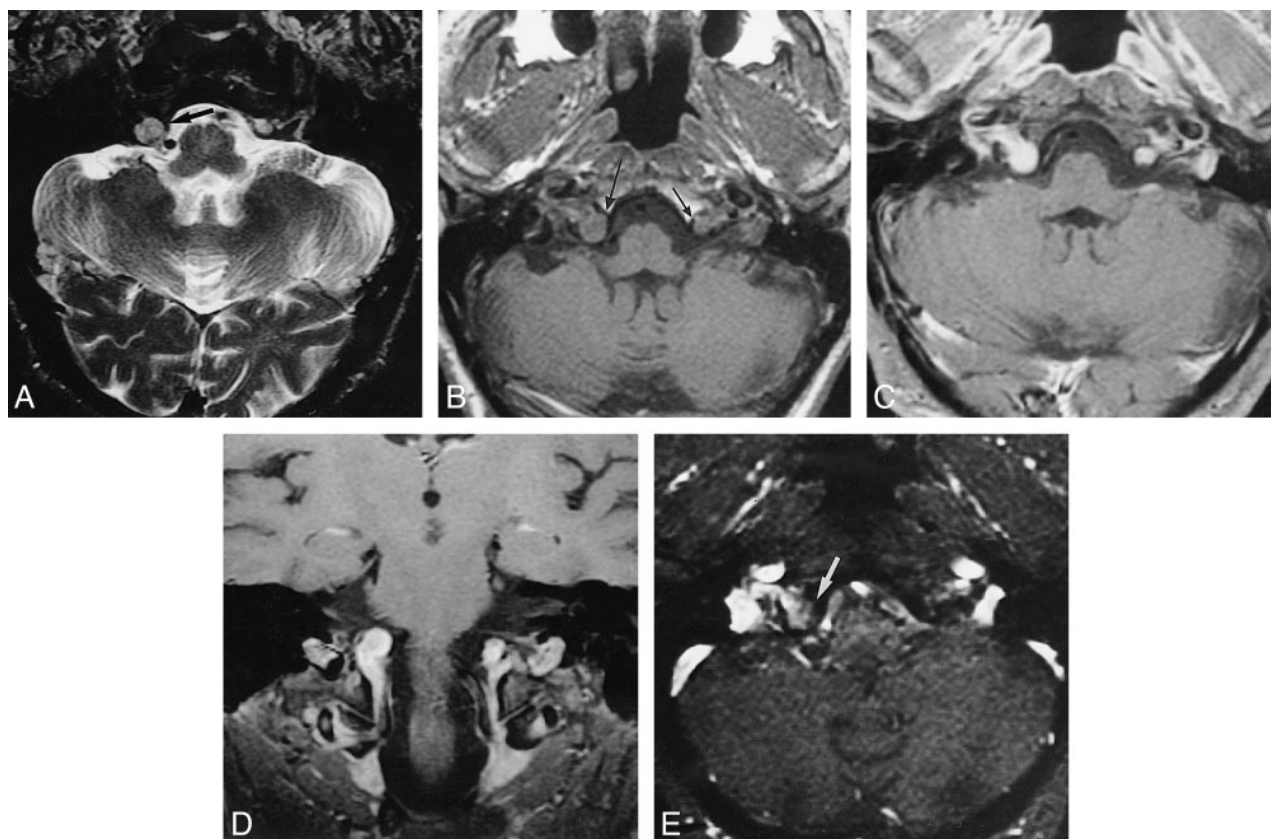


FIG 1. MR imaging findings in a 54-year-old man with a history of possible temporal lobe epilepsy.

A, Fast T2-weighted axial (parallel to the plane of the hippocampal formations) spin-echo image (4700/112/2) shows a 1-cm isointense mass in the right cerebellomedullary cistern (*arrow*).

B, Noncontrast T1-weighted axial spin-echo image (640/11/2) shows a round masslike structure (*long arrow*) extending from the right hypoglossal canal approximately 1 cm in diameter with a similar, less-impressive left-sided finding (*short arrow*).

C, Contrast-enhanced T1-weighted axial spin-echo image (760/11/3) shows marked enhancement of both regions.

D, Contrast-enhanced T1-weighted coronal spin-echo image (760/11/3) shows continuity of enhancement from the cervical epidural venous plexus to the hypoglossal canals, including the masses protruding into the cerebellomedullary cisterns.

E, Two-dimensional time-of-flight MR angiographic partition image shows patchy hyperintensity (*arrow*) within the larger right cerebellomedullary cistern, which in the absence of high signal on a T1-weighted image indicates blood flow (46/8.7/2; flip angle, 45°).

References

1. Voyvodic F, Whyte A, Slavotinek J. **The hypoglossal canal: normal MR enhancement pattern.** *AJNR Am J Neuroradiol* 1995;16:1707-1710
2. Williams PL, Warwick R. *Gray's Anatomy*. 36th ed. Edinburgh: Churchill Livingstone; 1980; 308,750
3. Shiozawa Z, Koike G, Seguchi K, et al. **Unilateral tongue atrophy due to an enlarged emissary vein in the hypoglossal canal.** *Surg Neurol* 1996;45:477-479