

Generic Contrast Agents

Our portfolio is growing to serve you better. Now you have a *choice*.



FRESENIUS
KABI

[VIEW CATALOG](#)

AJNR

Sources of Error in Doppler Diagnosis of Carotid Occlusive Disease

William J. Zwiebel and Andrew B. Crummy

AJNR Am J Neuroradiol 1981, 2 (3) 231-242

<http://www.ajnr.org/content/2/3/231>

This information is current as
of May 31, 2025.

Sources of Error in Doppler Diagnosis of Carotid Occlusive Disease

William J. Zwiebel¹
Andrew B. Crummy¹

Fifty errors with Doppler examination of 356 carotid bifurcations were examined to determine their cause and to establish methods of prevention. Only those errors related to hemodynamically significant stenosis or complete occlusion were considered. The relative frequency of errors in diagnosis of occlusion (30 false-positive or negative versus 31 true-positive) was considerably greater than the rate of inaccuracy for diagnosis of hemodynamically significant stenosis (20 false-positive or-negative versus 89 true-positive). The high error rate in diagnosis of occlusion was attributed to reliance on negative information. The source of error could be established in 48 of the 50 cases. In all but three cases, potential for preventing error existed through use of additional noninvasive techniques such as examination of common carotid resistivity or use of oculoplethysmography. Twenty-two errors of localization of stenosis or occlusion were encountered in addition to the 50 false-positive and -negative errors. In three of these, the errors might have led to patient mismanagement.

Doppler sonography has become one of the most useful of the newer, noninvasive techniques for detecting carotid occlusive disease. Using bifurcation imaging, this method provides a broad range of physiologic and anatomic information. Although a number of articles [1-7] have attested to the accuracy of Doppler carotid examination, they have only alluded to the causes of diagnostic error. To our knowledge, there has been no comprehensive study regarding errors in Doppler diagnosis.

The purpose of this paper is threefold: (1) to categorize and illustrate the errors we have encountered in the diagnosis of hemodynamically significant carotid occlusive disease; (2) to document a higher rate of Doppler error relative to complete occlusion than stenosis; and (3) to present techniques we now use to eliminate error associated with the diagnosis of both stenosis and complete occlusion.

We realize that major technical differences exist among the commercially available carotid Doppler scanners that may affect the incidence and types of errors encountered. Nevertheless, we believe that most diagnostic errors we have seen are basic to Doppler carotid examination per se and may occur regardless of the type of equipment used.

Materials and Methods

There were 356 bifurcations in 178 patients examined by Doppler sonography and arteriography. A 5 MHz continuous-wave, directional Doppler flow meter with bifurcation imaging capabilities was used in this study (prototype of DOPSCAN TM Instrument, Carolina Medical Electronics, Inc., King, N.C.). The technique of Doppler examination included the following procedures: (1) The direction of ophthalmic artery flow was established in all patients through detection of posterior orbital flow signals. Reversal of posterior orbital flow was considered diagnostic of external carotid collateral circulation. Absence of posterior orbital flow signals, biphasic signals, or marked diminution of the amplitude of

Received December 22, 1980; accepted February 18, 1981.

¹Department of Radiology, Section of Ultrasound, University of Wisconsin Clinical Science Center, 600 Highland Ave., Madison, WI 53792. Address reprint requests to W. J. Zwiebel.

This article appears in May/June 1981 *AJNR* and July 1981 *AJR*.

AJNR 2:231-242, May/June 1981
0195-6108/81/0203-0231 \$00.00
© American Roentgen Ray Society

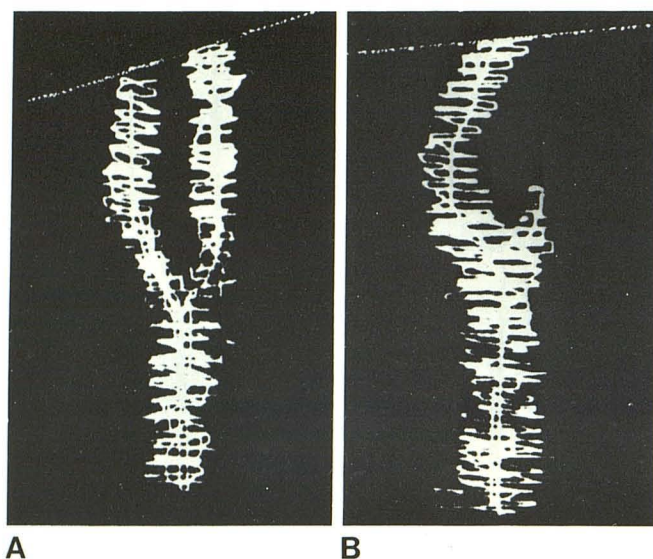


Fig. 1.—Doppler carotid bifurcation images. A, Normal. B, Complete occlusion of internal carotid.

posterior orbital signals was considered presumptive evidence of external carotid collateral flow. (2) A two-dimensional blood flow image of the carotid bifurcation (clavicle to mandible) was next obtained (fig. 1A). (3) The audible Doppler flow signals were tape recorded along the course of this image. (4) Arterial stenosis was detected through an increase in pitch of the audible Doppler flow signals, poststenotic turbulence, and extension of high velocity flow into the diastolic part of the cardiac cycle (fig. 2). The hemodynamic significance of a stenotic lesion was judged according to the severity of these flow disturbances. Ipsilateral posterior orbital flow abnormality, when present, contributed to the judgment of hemodynamic significance. Frequency spectrum analysis was not used in estimating the severity of stenosis [5]. Occlusion was diagnosed when flow signals in a part of the carotid bifurcation could not be identified (fig. 1B). Ipsilateral posterior orbital flow abnormality, when present, contributed to the latter diagnosis.

In order to obtain data on the incidence of specific errors, Doppler and angiographic findings were compared. Most arteriograms used for correlation with the Doppler results included selectively injected anteroposterior and lateral views of the carotid bifurcation. The grading of the arteriograms was carried out by two independent observers. A stenosis was considered to be hemodynamically significant if the *lumen area* was reduced by 90% or greater [8, 9].

Only errors related to false-positive or -negative diagnosis of hemodynamically significant occlusive disease were considered in this study. Each lesion (stenosis or complete occlusion) was treated independently even though more than one lesion might have been present at a single bifurcation. The accurate evaluation of minor stenotic lesions and nonobstructing wall irregularities was considered to be beyond the diagnostic potential of the instrument [3].

Results

Previously published studies from our department [3, 7] have dealt with the overall accuracy of continuous-wave Doppler carotid examination. Selected results are presented here for comparing the incidence of individual Doppler errors.

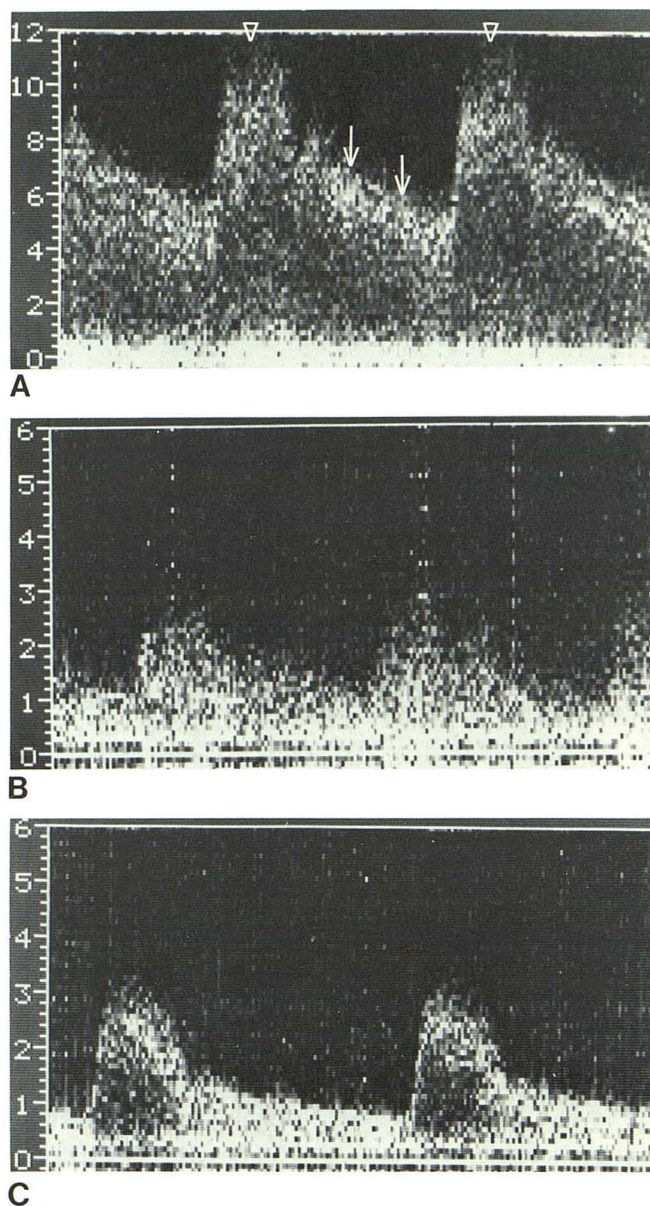


Fig. 2.—Sonographic representation of audible Doppler signals with hemodynamically significant stenosis. A, Stenotic zone. Markedly elevated peak systolic frequencies (arrowheads) and extension of high velocity flow into diastolic part of cardiac cycle (arrows). B, Poststenotic zone. Severe turbulent flow indicated by "filling in" of frequency spectrum. Localized reversal of flow signals (not shown) is also present. C, Normal internal carotid sonogram. (Note differences in scale among these and sonograms in following figures. Numbers at left represent kHz frequency.)

Occlusion

Forty-seven cervical carotid occlusions were diagnosed arteriographically. Of these, 31 were interpreted correctly by Doppler examination (true-positive) and 16 were not detected (false-negative). In addition, 14 false-positive diagnoses of occlusion were made (table 1). The rate of misdiagnosis of occlusion remained fairly stable during the initial 3 year period (fig. 3), indicating that increased experience did not change the incidence of error.

TABLE 1: Doppler Diagnosis of Carotid Stenosis and Occlusion

Result	Diagnosis	
	Stenosis (n = 97)	Occlusion (n = 47)
True-positive	89	31
False-positive	12	14
False-negative	8	16

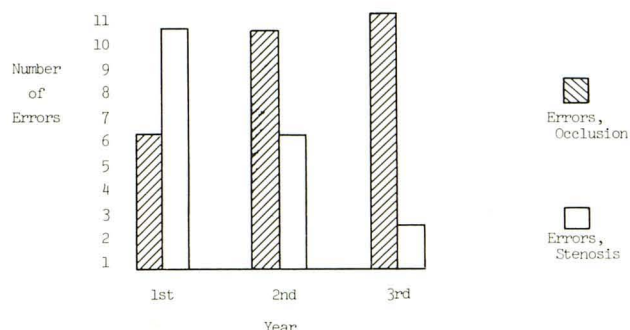


Fig. 3.—Analysis of Doppler error rate during first 3 years experience.

Stenosis

Angiography identified 97 individual stenoses of 90% or greater decrease in luminal area. Doppler examination correctly diagnosed 89 (true-positive) while eight lesions were either underestimated in severity or not detected (false-negative). In 12 other cases, Doppler examination either overestimated the severity of stenosis or diagnosed nonexistent stenoses (false-positive) (table 1). The error rate for diagnosis of stenosis declined noticeably during the same 3 year period mentioned above (fig. 3), indicating an inverse relation between incorrectly diagnosed stenosis and level of experience.

Sources of Error

Of the 50 false-positive and -negative Doppler errors in this series, the source of inaccuracy could be established with reasonable certainty in 48. Twelve separate categories of error were established (table 2). Detailed consideration of the source or error in each category is considered in the Discussion.

Errors in localizing true-positive stenoses and occlusions occurred in 22 (18%) of 120 bifurcations (tables 2 and 3). Fourteen of these errors involved either the bifurcation and internal carotid or the bifurcation and external carotid. In eight patients, internal carotid lesions were mistakenly placed in the external carotid or vice versa. Three of the 22 localization errors might have led to incorrect patient management.

Posterior Orbital Flow

Posterior orbital flow data were available for 332 of the 356 bifurcation studies. From this data, it is noteworthy that

TABLE 2: Accuracy of Doppler Localization of Cervical Carotid Occlusion and Stenosis

True-Positive Diagnosis	Total	Correctly Localized	Incorrectly Localized
Occlusions	31	29	2
Stenoses	89	69	20

Note.—Three entries under Incorrectly Localized were of potential significance for patient management.

TABLE 3: Classification of Errors

Cause	No. Patients
Incorrect recognition of carotid bifurcation	15
Superimposition of external and internal carotid arteries in coronal plane	8
Severe stenosis mistaken for occlusion	3
Weak signals misinterpreted as occlusion	2
Normal or weak signals in severe stenosis	2
Point of maximum frequency shift not identified	2
Interpreter error in estimation	9
Jugular vein compression mistaken for stenosis	2
Internal carotid tortuosity	2
Inaccessible stenosis	1
Stenosis obscured by plaque or overlying vessel	2
Cause of error undetermined	2
Error in localization	22*

* Three of potential significance for patient management.

posterior orbital examination is a highly specific indicator of the presence of a hemodynamically significant lesion (3.7% false-positive rate), but lacks sensitivity (65% false-negative rate).

Discussion

Comparison of Error Rates for Occlusion and Stenosis

The analyses of Doppler and angiographic data confirmed our suspicion that the error rate for Doppler diagnosis of occlusion was considerably greater than that associated with stenosis. The results also verified our suspicion that the more experienced the technician and physician-interpreter, the lower the diagnostic error rate for stenosis. However, experience had no effect on the error rate associated with occlusion. These observations were regarded as a function of the basic nature of the available diagnostic information; that is, stenosis was diagnosed on the basis of positive information whereas occlusion was diagnosed on the basis of negative information.

Categories of Error

In the following discussion, the major sources of Doppler error listed in table 2 are discussed and methods for avoiding these inaccuracies are suggested. The utility of the latter techniques is under ongoing evaluation.

Incorrect recognition of carotid bifurcation. The most significant source of error was mistaking patent external carotid branches or other vessels for the carotid bifurcation (fig. 4). Errors of this type accounted for all our false-negative diagnoses of occlusion. In 10 cases, external carotid branches were mistaken for the carotid bifurcation. In four

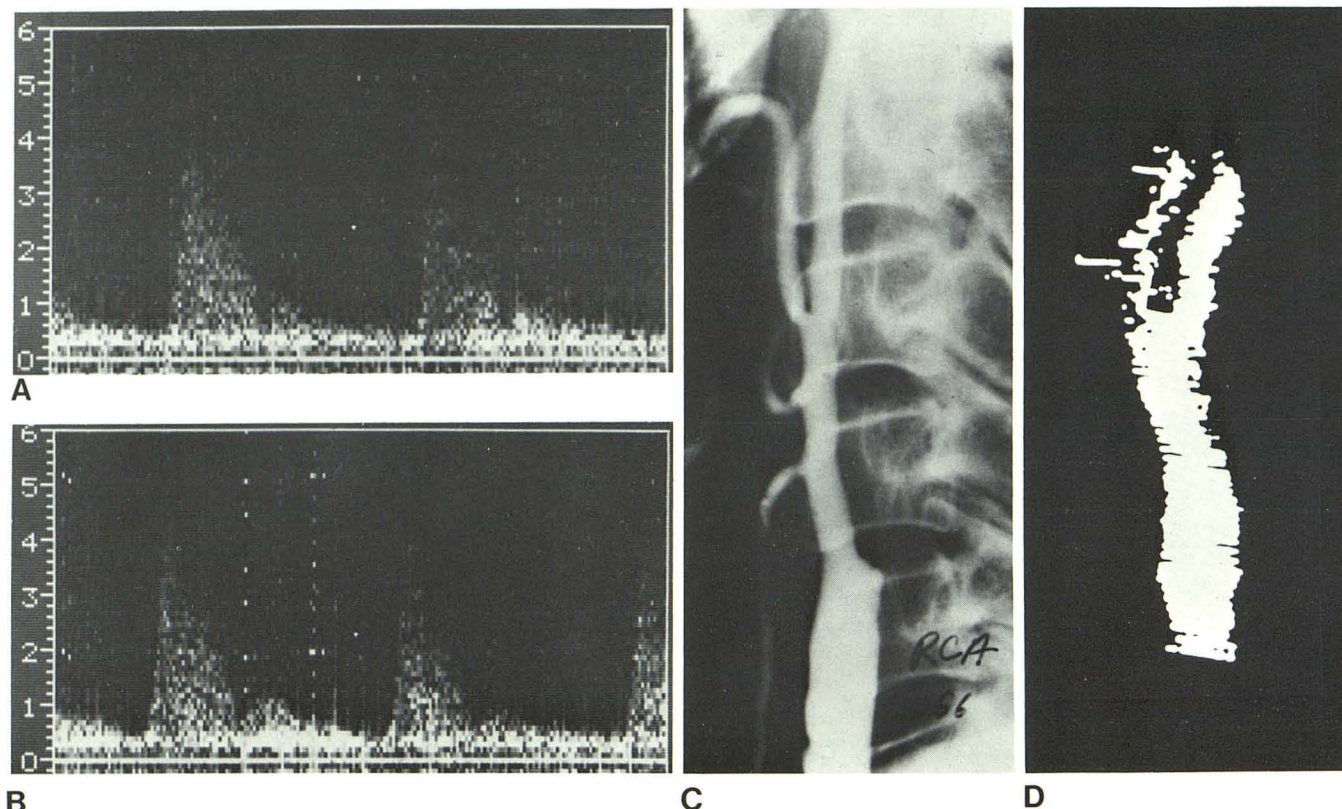


Fig. 4.—*Incorrect recognition of carotid bifurcation.* Doppler carotid examination was reported normal on right even though signals obtained in bifurcation branch vessels had similar "high resistance" sonographic quali-

ties (A and B) and right posterior orbital flow (not shown) was biphasic. C, Arteriogram. Occlusion of right internal carotid. D, Doppler image. External carotid branches clearly mistaken for carotid bifurcation.

cases, prominent ascending cervical collaterals were imaged in addition to one or more external carotid branches, and these combinations were mistaken for the carotid bifurcation (fig. 5). In another case, occlusion of the main trunk of the external carotid above the facial artery was overlooked due to patency of the remaining external carotid branches. Errors in recognizing the carotid bifurcation may potentially be avoided through attention to specific Doppler findings and through application of noninvasive techniques that were not used in these patients.

First, marked lack of symmetry of the bifurcation images, and especially disparity of the position of the bifurcation relative to the mandible, should alert both the technologist and interpreter to the possibility that external carotid branches are being imaged. However, it is important to recognize that disparity in the appearance of the bifurcation images may also occur in normal subjects.

A second and more important step for avoiding such errors is routine scrutiny of the pulsatile quality of the audible signals obtained in the branch vessels at each bifurcation. Normally, blood flow is noticeably more continuous throughout the cardiac cycle in the internal carotid than in the external carotid due to lower peripheral resistance in the brain as compared with the external carotid circulation. Audible Doppler signals in the external carotid normally have a more prominent systolic component and a less pronounced diastolic component than is heard in the

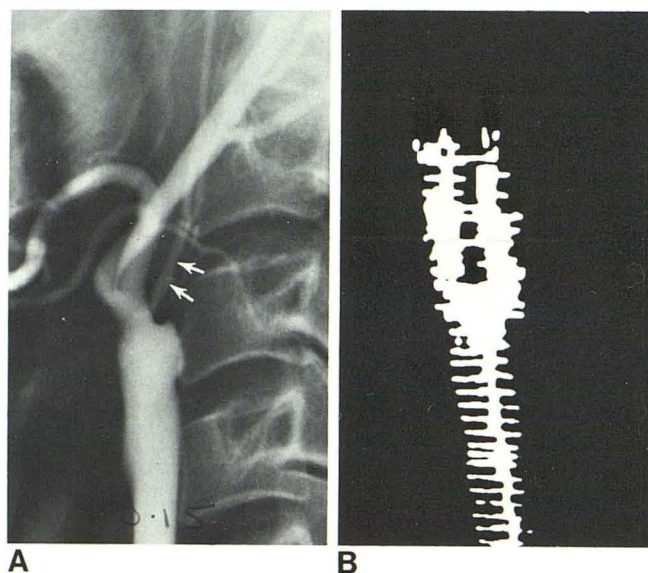


Fig. 5.—*Incorrect recognition of carotid bifurcation.* A, Ascending cervical collateral (arrows) was mistaken for internal carotid, resulting in false-negative diagnosis of occlusion. Weak (low amplitude) signals in vessel were attributed to short "thick" neck of patient, which was difficult to examine. B, Doppler image.

internal carotid (fig. 6). When this difference cannot be detected and the audible signals from both branches have

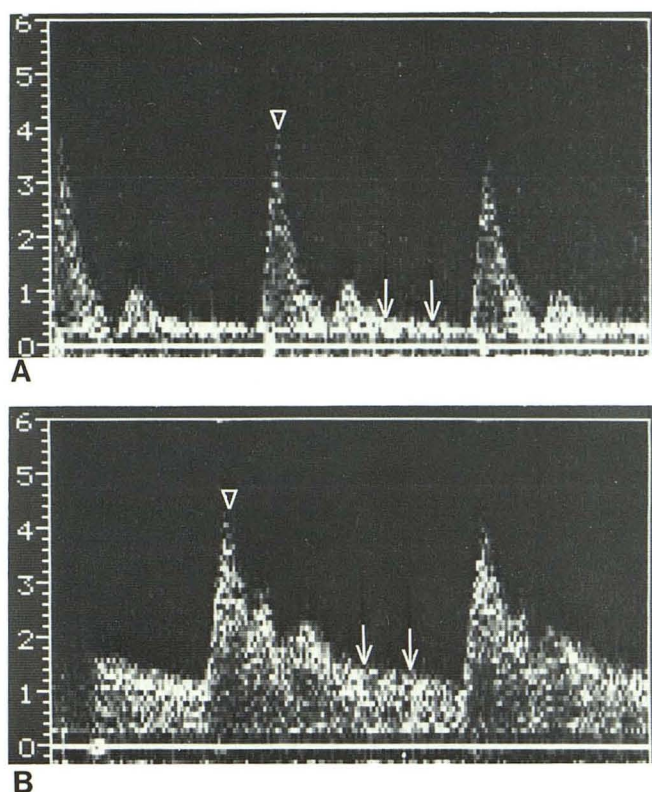


Fig. 6.—Comparison of sonograms in normal external (A) and internal (B) carotid. Prominent systolic component (arrowheads) and relative lack of diastolic flow (arrows) in external compared with internal carotid. These differences are readily appreciated in audible Doppler signals.

a prominent systolic component, the possibility exists that external carotid branches have been imaged and the internal carotid is occluded. Suspicion that external carotid branches have been imaged is further heightened if a clear difference exists in the pulsatile quality of signals heard at one bifurcation but not at the other. The comparison of external and internal carotid signals is facilitated by recording a short segment of Doppler signals in the internal carotid followed immediately by sounds heard in the external carotid. In our laboratory, we now routinely obtain such recordings in at least two locations within each branch vessel. Good quality pulse velocity tracings or on-line frequency spectrum analysis may be of additional benefit in comparing internal and external carotid signals. If posterior orbital or periorbital examination findings are abnormal and branch vessel signals are audibly similar, internal carotid occlusion is very likely. Normal posterior orbital or periorbital examination, on the other hand, is not helpful in excluding occlusion since intracranial collateral circulation may frequently preclude the development of external carotid collateral flow.

An unfortunate finding is that external and internal carotid Doppler signals may be of similar quality in some normal individuals. This has been particularly common in patients with hypertension or tachycardia, and no doubt can be observed in many individuals with reduced arterial compliance or with distal internal carotid stenosis. The similarity of

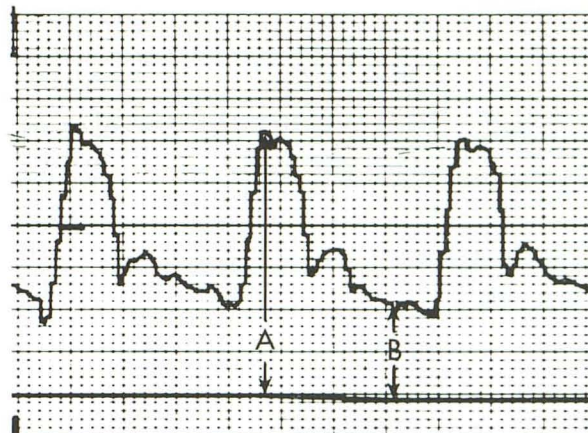


Fig. 7.—Common carotid resistivity index (RI) measured from velocity waveform by formula $RI = A - B/A$. Normal resistivity is 0.55–0.75 [10]. Courbier et al. [11] found that hemodynamically significant internal carotid lesions were invariably associated with a common carotid RI of greater than 0.75. Satisfactory measurements of RI requires good quality common carotid signals free from interference due to venous flow or excessive arterial turbulence.

Doppler signals in the external and internal carotid branches in these patients might result in the false-positive diagnosis of occlusion.

Other kinds of noninvasive examination are frequently necessary to avoid false-positive diagnoses of occlusion in patients who exhibit Doppler signals of similar quality in bifurcation branch vessels. The most immediately available of these is measurement of common carotid resistivity as described by Planilo et al. [10] (fig. 7). This method is based on changes observed in common carotid pulsatility in the presence of a hemodynamically significant internal carotid lesion. Normally, the common carotid pulse waveform demonstrates characteristics of a low resistance, high volume circulation. If internal carotid flow is severely reduced in volume, findings typical of a high resistance circulation are instead seen in the common carotid. The evidence of abnormal resistance may be obvious on visual examination of the common carotid waveform or may be measured through the "resistivity index" of Planilo et al. We strongly recommend close examination of the common carotid waveform as a routine part of all carotid Doppler examinations. The use of oculoplethysmography is also suggested for either confirming or refuting internal carotid occlusion in difficult cases. Neither common carotid resistivity nor oculoplethysmography is without diagnostic error [11–13], but correlation of Doppler imaging results with those of the latter examinations should resolve most diagnostic dilemmas.

It is commonly believed that several noninvasive examinations should be performed routinely as part of all cerebrovascular studies since correlation of the data from more than one test has been found to improve overall accuracy [13, 14]. Indeed, it appears that many of the 15 errors of mistaken carotid bifurcation identification, as well as most other errors we report, could probably have been prevented through the use of ancillary noninvasive examinations to either confirm or refute the Doppler imaging results.

Superimposition of external and internal carotid arteries. The most common error for false-positive diagnosis of occlusion was superimposition of the external and internal carotid in the coronal plane (fig. 8). In seven cases, the internal carotid was mistakenly considered to be obstructed. In another case, a false-positive diagnosis of external carotid occlusion was made.

Many errors due to superimposition of carotid branches can be prevented simply by turning the patient's head to either the right or left and rescanning the carotid bifurcation (fig. 9). This maneuver will frequently separate branch vessels to a sufficient degree to allow recognition of Doppler signals from both the internal and external carotid. However, a potentially more reliable method of avoiding such errors is through routine scrutiny of common carotid resistivity and ancillary use of oculoplethysmography. It is important to recognize that absence of external carotid collateral flow is not helpful in excluding complete internal carotid occlusion since many patients with occlusion fail to develop external carotid collateral flow.

Severe stenosis mistaken for occlusion. False-positive diagnoses of occlusion occurred in three cases with severe internal carotid stenosis, which permitted only a "trickle" of blood flow (fig. 10). The minimal flow in these stenoses either did not produce a detectable Doppler shift or resulted in very weak signals interpreted as arising from small cervical collateral vessels. In all three patients, posterior orbital flow was normal in direction due to intracranial collateral circulation.

Errors of this type may have considerable clinical significance. Complete occlusion of the internal carotid is usually irreparable, but the potential exists for restoration of normal circulation if even a small amount of flow is present in a stenotic carotid vessel.

We are not sure of any method for preventing this type of error. External carotid collateral flow may occur in either severe stenosis or in occlusion and is therefore not useful in distinguishing the two. The resistivity index and oculoplethysmography will also be abnormal in both conditions. Precisely localized Doppler sampling potentially available through duplex scanning may be of assistance, but it is likely that the trickle of flow present in these patients will remain difficult to detect regardless of the instrument used.

Weak signals misinterpreted as occlusion. In two other patients, weak (low amplitude) internal carotid artery signals were falsely interpreted as carotid occlusion. Dense carotid calcification resulted in false-positive diagnosis of occlusion in one of these patients. Weak (low amplitude) signals were detected in the internal carotid, leading to the erroneous conclusion that the internal carotid was occluded and that the Doppler signals arose either from the external carotid or collateral vessels.

Although densely calcified plaque is commonly present at the carotid bifurcation in older individuals, in only this and one other case did calcification interfere with sound transmission to such an extent that error resulted. In another patient, the cause of the weak signals appeared to be a very "thick" configuration of the neck. It is theorized that the

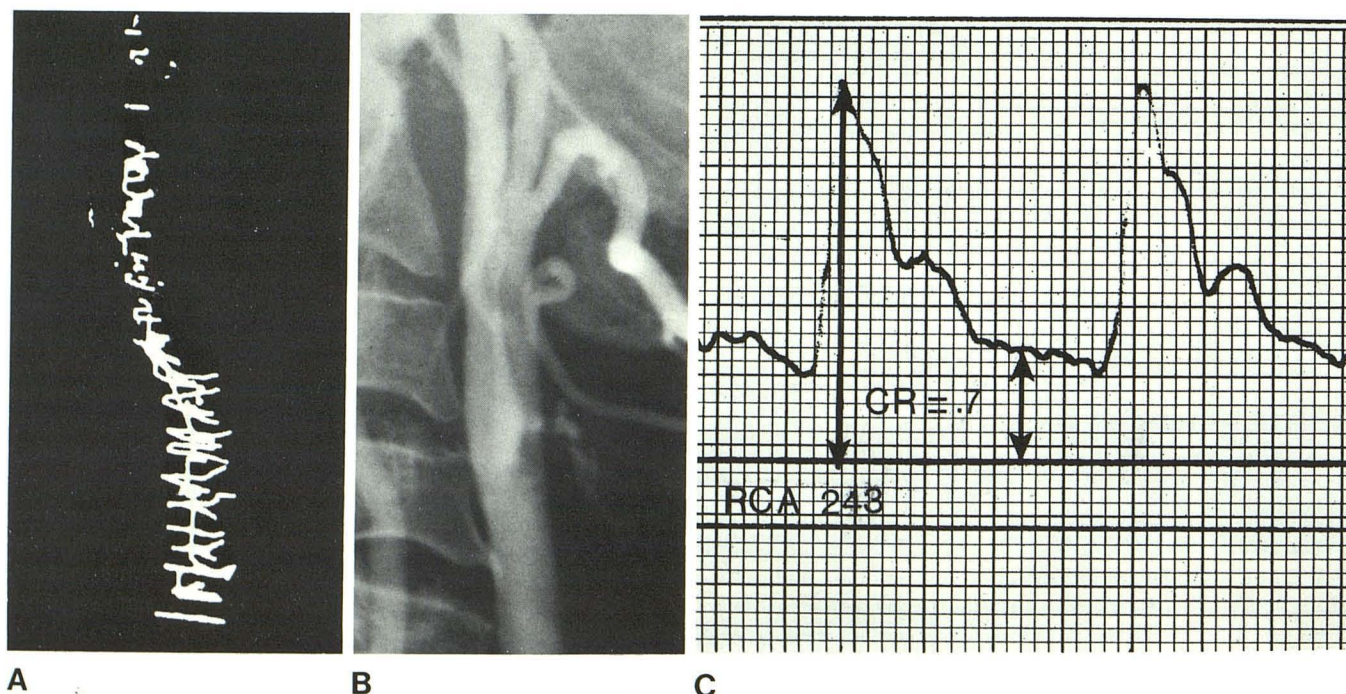


Fig. 8.—Superimposition of carotid bifurcation. **A**, Only one vessel was detected through Doppler examination of right bifurcation, resulting in false-positive diagnosis of internal carotid occlusion. Ipsilateral posterior orbital flow signals (not shown) were of normal direction but of lower amplitude than

those detected on left. **B**, Arteriogram. Normal right carotid bifurcation with internal and external carotid superimposed in coronal plane. Orientation of carotid branches clearly accounted for Doppler error. **C**, Common carotid resistivity of 0.7 suggests patency of right internal carotid.

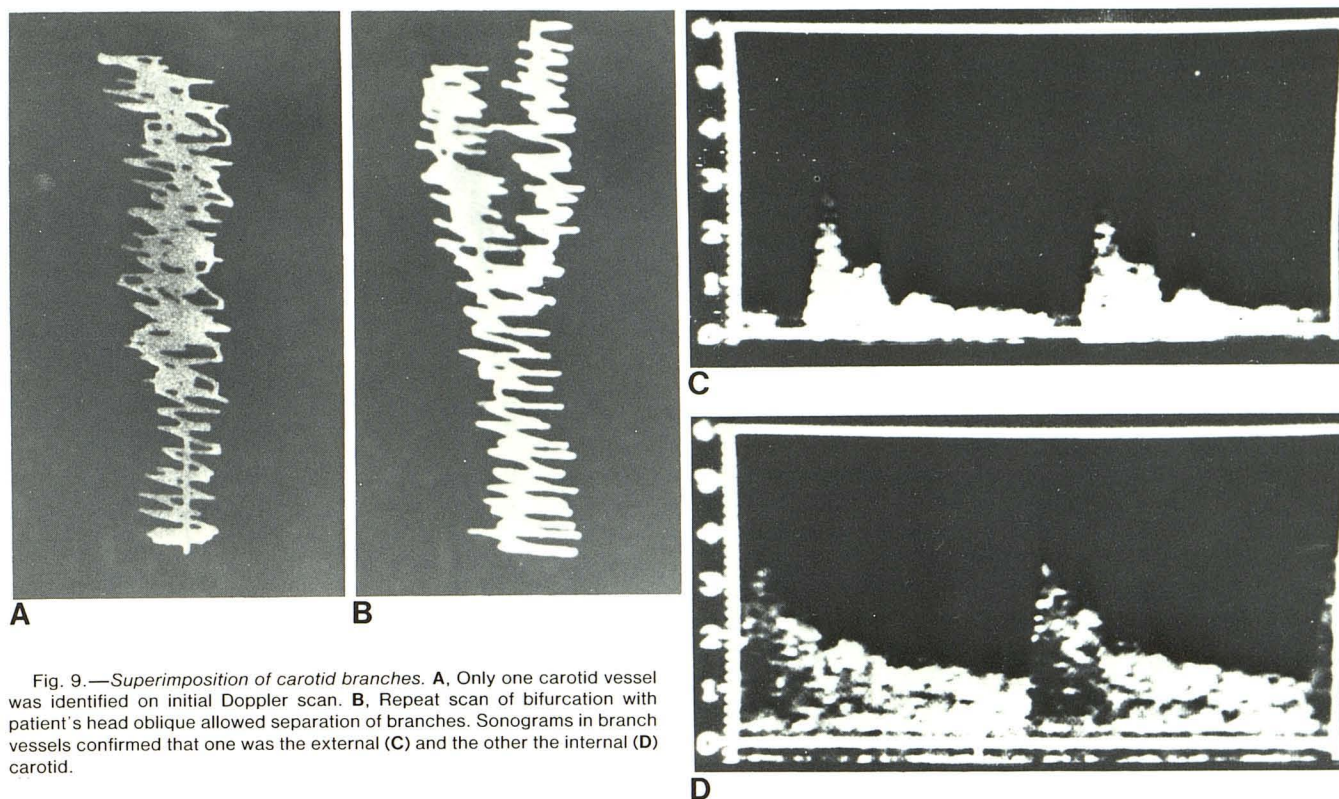


Fig. 9.—Superimposition of carotid branches. **A**, Only one carotid vessel was identified on initial Doppler scan. **B**, Repeat scan of bifurcation with patient's head oblique allowed separation of branches. Sonograms in branch vessels confirmed that one was the external (**C**) and the other the internal (**D**) carotid.

weak signals in this case resulted from excessive attenuation of the sound beam and also from location of the artery deep to the focal zone of the transducer.

Normal or weak signals in severe stenosis. Relatively weak but otherwise normal Doppler signals were observed in two patients in whom internal carotid stenosis was not recognized (fig. 11). Progressive decrease in lumen area in a stenotic vessel is accompanied by a proportional increase in peak Doppler-shifted frequency until the resistance in the stenotic zone becomes so severe that blood flow begins to fall off [8] (fig. 12). As the lumen narrows beyond this point, flow velocity and peak Doppler-shifted frequency decrease rapidly and may return to normal levels. In addition, post-stenotic turbulence subsides as velocity flow decreases. Doppler examination in such instances may severely underestimate or completely fail to detect stenotic lesions.

Potential exists for avoiding such errors. In some patients, turbulence may warn of major carotid stenosis even though high frequency signals are absent or only moderate elevation of peak frequency is observed. Although turbulence may result from nonobstructive plaquing, severe, coarse turbulence extending through a long segment of a vessel should always arouse suspicion of occult stenosis. Abnormality of posterior orbital and periorbital flow may assist in avoiding this category of error. Equally important may be close scrutiny of the common carotid waveform for evidence of high resistivity. This type of error occurs only in hemodynamically significant stenosis; therefore, abnormality of carotid resistivity should invariably be present. It is possible

that the two errors of this type could have been avoided through examination of the common carotid waveform. No doubt, ancillary use of oculoplethysmography would also have been beneficial.

Point of maximum frequency shift not identified. Failure to identify the point of maximum Doppler frequency shift (fig. 13) can result in gross underestimation of severity of stenoses as occurred in two patients. Maximally shifted Doppler signals related to a stenotic lesion may be confined to a relatively small area. There are two reasons for this: (1) the lumen of the vessel may be extremely small in the stenotic zone and (2) the stenosis may only extend over a short segment of the vessel. As a result, peak Doppler-shifted signals and other flow disturbances in the stenotic zone may be overlooked if care is not taken to search for the most pronounced abnormalities. The sonographers in our laboratory are thus instructed to closely scrutinize all areas in which even faint high frequency signals are detected to ensure that a small zone of significant frequency shift is not overlooked. A diligent search of this type is especially important when unexplained, coarse turbulence (poststenotic) and ipsilateral evidence of external carotid collateral flow are present. Likewise, abnormal common carotid resistivity should prompt close scrutiny of any areas suspicious for stenotic lesions. Once again, we believe that examination of common carotid resistivity and ancillary use of oculoplethysmography could have prevented both these errors. Even if the stenoses were not actually identified by these means, the existence of a hemodynamically significant

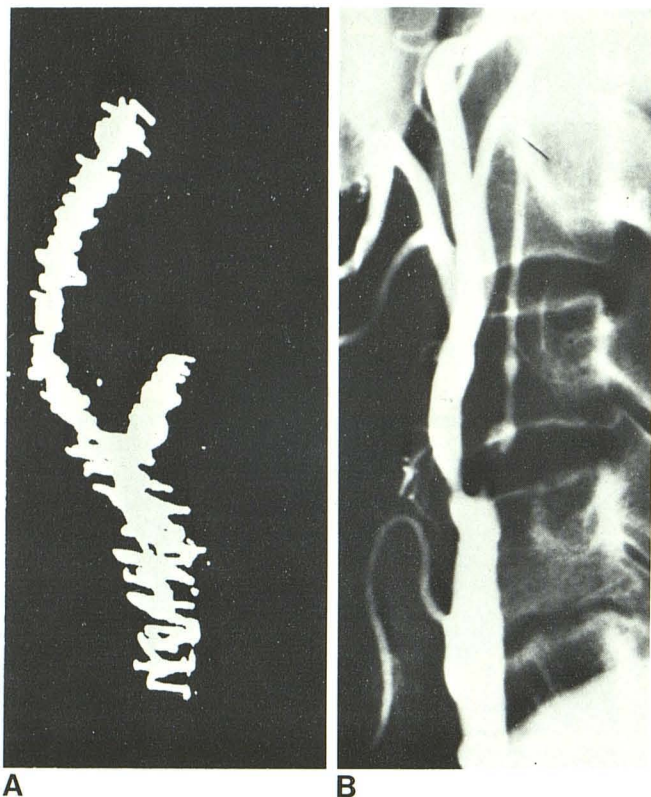


Fig. 10.—Severe stenosis mistaken for occlusion. False-positive diagnosis of occlusion in 66-year-old woman after 6 months of recurrent syncopal episodes. **A**, Doppler examination. No flow signals in area of left internal carotid. Left posterior orbital flow signals (not shown) were of low amplitude but normal direction. **B**, Arteriography 1 day later. Sluggish flow in small caliber internal carotid lumen. Flow velocity not sufficient to produce detectable Doppler shift. Nonhemodynamically significant stenosis (65% decrease in area) in external carotid was correctly diagnosed by Doppler examination.

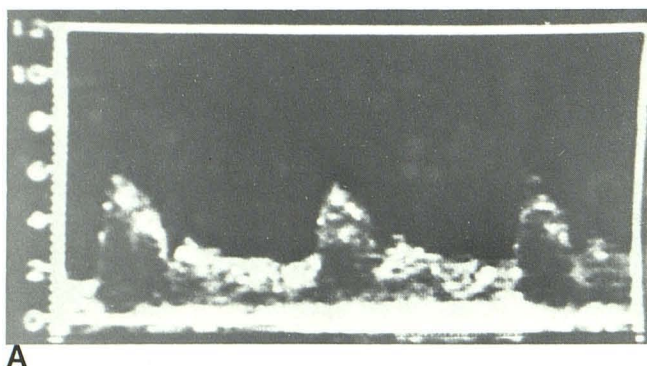


Fig. 11.—Severe stenosis with relatively normal signals. False-negative diagnosis of stenosis in 76-year-old man with numbness in left arm and leg and mild right facial paresis. No bruits were audible. **A**, Doppler examination. Slight frequency elevation in right internal carotid extended over fairly long segment and was attributed to minor stenosis. Minimal turbulent flow was heard in distal part of vessel. Right posterior orbital flow was normal in direction. **B**, Arteriogram. Severe, lengthy stenosis of internal carotid with diminished blood flow. Relative absence of poststenotic turbulence was attributed to reduced flow velocity. (Arteriogram courtesy of A. Yale Gerol, Kenosha, WI.)

lesion somewhere in the carotid system would at least have been noted.

Interpreter error in estimating severity. Interpreter underestimation of stenosis (fig. 14) has not been as severe a problem as overestimation (fig. 15). The latter error resulted in eight of the 12 false-positive diagnoses in this series. Most, if not all, of these errors could have been prevented through more careful assessment of Doppler signal abnormalities.

Stenoses of hemodynamic significance (90% or greater decrease in lumen area) are characterized by the following Doppler abnormalities: (1) significant elevation of peak Doppler shifted frequency (10 kHz or greater), (2) poststenotic turbulence, and (3) extension of high velocity flow into the diastolic part of the cardiac cycle (fig. 2). If one or more of these components is absent, the interpreter should hesitate to regard a lesion as hemodynamically significant. In equivocal cases, close attention should be devoted to posterior orbital and periorbital flow signals, common carotid resistivity, and the results of other noninvasive studies. Frequency spectrum analysis or some other objective gauge of peak Doppler frequency appears to be helpful in preventing some errors of overestimation, but on the basis of our data, we believe that peak frequency is not a reliable indicator of the degree of stenosis when considered independently of other Doppler findings.

In most of the patients in whom overestimation of severity occurred, a relatively minor stenosis was present. However, in at least one case, the normal increase in pitch observed in the internal carotid near the mandible was mistakenly interpreted as a significant stenosis. The latter increase in Doppler shift is produced by curvature of the internal carotid medially away from the transducer (fig. 16).

Jugular vein compression mistaken for stenosis. False-

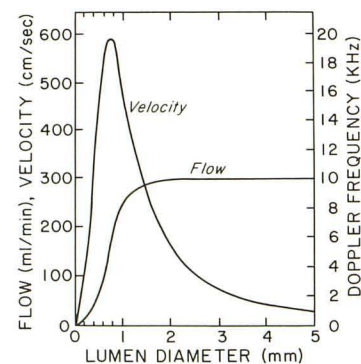
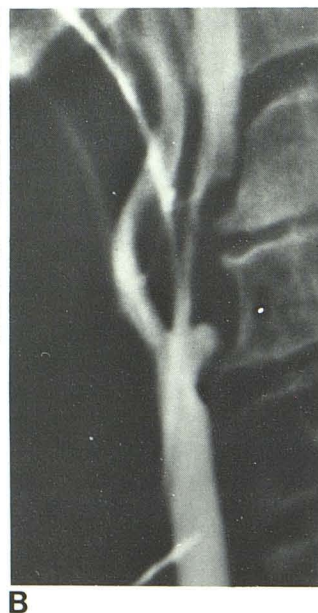

Fig. 12.—Relation of velocity flow, volume flow, and peak Doppler frequency in internal carotid stenosis. Velocity and peak Doppler-shifted frequency rise until arterial lumen is reduced by about 95% area. Beyond this, velocity and peak Doppler-shifted frequency rapidly decline. This is attended by abrupt decrease in volume flow. Theoretical curves based on a 5 mm diameter internal carotid and a 5 MHz Doppler. (Reprinted from [8].)

Fig. 13.—*Maximum frequency shift not recognized.* False-negative diagnosis of stenosis in 57-year-old man with bilateral carotid bruits and loss of balance. **A**, Initial Doppler examination of right bifurcation was unremarkable except for minor increase in frequency in proximal internal carotid and moderately prominent turbulent signals (not shown) in distal internal carotid. **B**, Arteriogram. Major internal carotid stenosis not detected on Doppler study. **C**, Subsequent careful search of proximal right internal carotid. Localized area of weak, very high frequency signals was bypassed on initial examination.

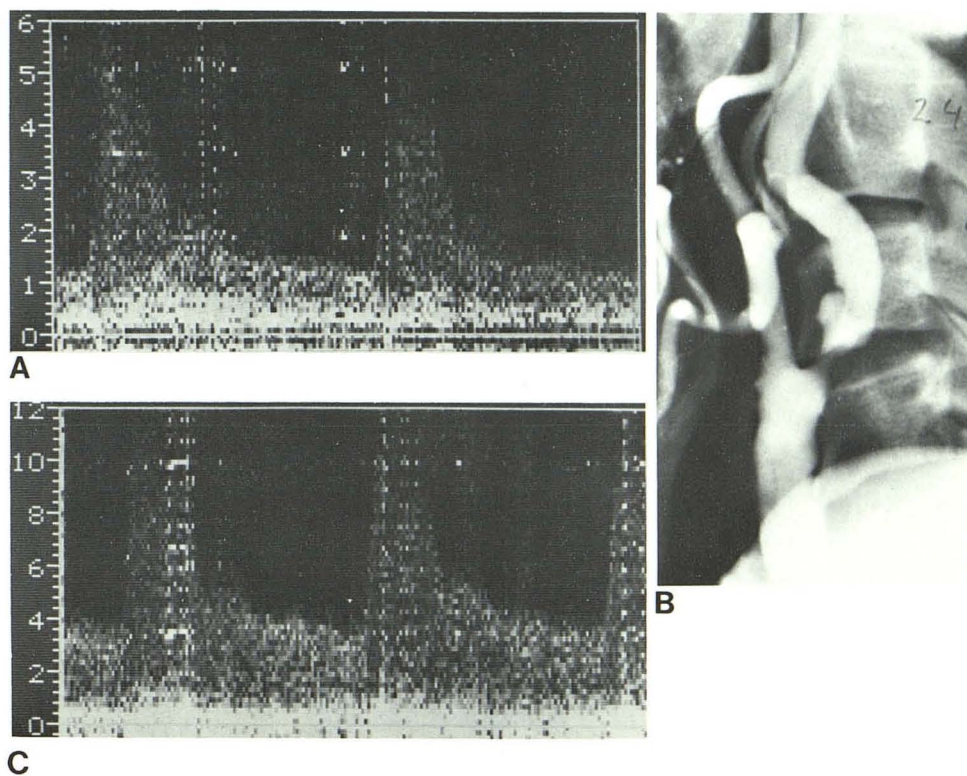
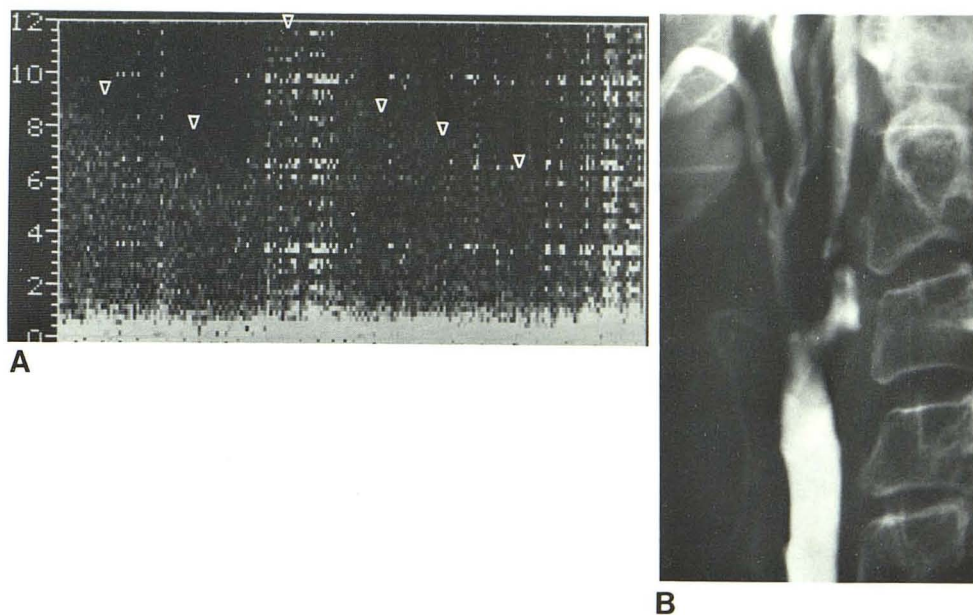
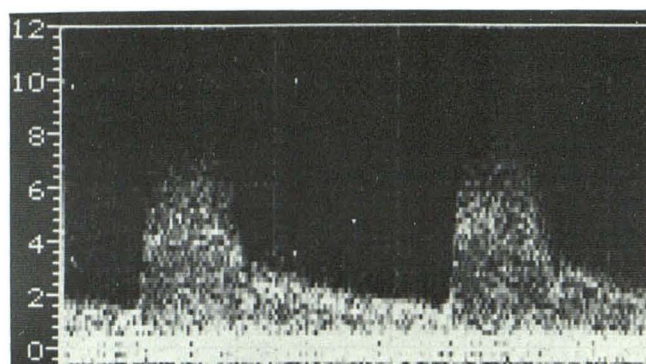


Fig. 14.—*Underestimation of stenosis* in 59-year-old man with transient ischemic episodes. Carotid Doppler study was interpreted as nonhemodynamically significant stenosis of right internal carotid. **A**, Review of Doppler findings demonstrated considerable elevation of peak systolic frequency in stenotic zone and extension of high velocity flow into diastole (arrowheads). Poststenotic turbulence (not shown) was also evident. **B**, Arteriogram. Major stenosis was underestimated on original Doppler interpretation.



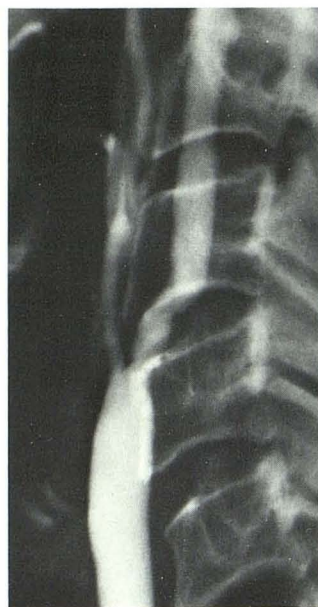positive diagnosis of stenosis due to jugular vein compression occurred in two cases. Both of these errors were made by inexperienced personnel. Spurious high frequency signals due to venous compression are a common occurrence in the course of carotid Doppler examination. Such signals occur when the pressure of the transducer causes apposition of the vein walls. The resulting decrease in lumen area is accompanied by increased flow velocity and a concomi-

tant rise in the pitch of the Doppler signals. In both of the misdiagnosed cases, turbulent flow was absent distal to the high frequency signals, and the frequency shift was inconsistently heard. Posterior orbital flow was normally directed in both cases. Once again, ancillary noninvasive data might have prevented these errors since correlative evidence of a hemodynamically significant lesion would not have been found.



A

Fig. 15.—Overestimation of stenosis in 69-year-old woman with bilateral cervical bruits, dizziness, and unstable gait. Doppler examination diagnosed hemodynamically significant stenosis in right internal carotid. **A**, Sonogram in internal carotid stenotic zone. Peak frequency is about 6 kHz with little or no extension of high velocity flow into diastole. Post-stenotic turbulence was not seen. **B**, Arteriogram. Relatively minor internal carotid stenosis was overestimated on Doppler study due to interpreter error. External carotid stenosis was correctly diagnosed.



B

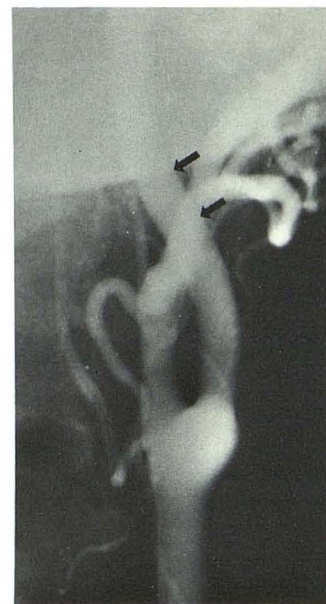
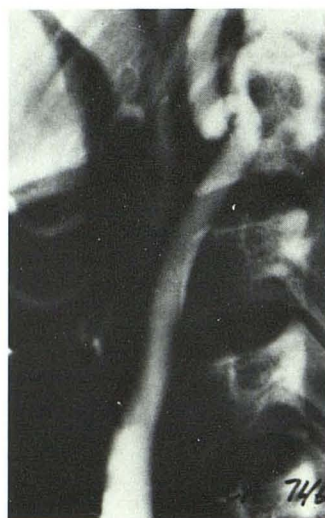
Fig. 16.—Anteroposterior arteriogram. Normal medial curvature of internal carotid near mandible (arrows). Vessel position alters angle of incidence of sound beam and results in increased pitch of Doppler signals. Change in pitch should not be mistaken for internal carotid stenosis.



RIC 746

A



B

Fig. 17.—Tortuous internal carotid artery in 42-year-old diabetic woman with slurred speech, loss of motor control, and bilateral cervical bruits. Doppler study diagnosed hemodynamically significant stenosis in right internal carotid near mandible. **A**, Sonogram in area of abnormality. Peak systolic frequencies of 10–12 kHz, but relatively little diastolic flow abnormality. **B**, Arteriogram. Severe "kink" in internal carotid with minimal resulting stenosis. Overestimation of severity of stenosis apparently resulted from pronounced alteration in angle of incidence of sound beam in tortuous part of vessel combined with relatively minor lumen compromise related to "kink."

Tortuous internal carotid artery. False-positive diagnosis of stenosis due to internal carotid tortuosity (fig. 17) was encountered twice. Marked internal carotid tortuosity in the vicinity of the mandible is a fairly common angiographic finding and apparently accounted for the increased pitch in the Doppler signals observed in these patients. Symptomatic "kinking" of the internal carotid has been reported [16,

17], but in our patients, the reduction in lumen diameter noted at angiography was not believed to be significant. The accentuated frequency shifts observed in these cases were believed to result from two factors: (1) relatively minor compromise in lumen area induced by the "kink" and (2) pronounced alteration in the angle of incidence of the sound beam compared with normally directed vessels.

As noted previously, a slight increase in the pitch of the audible Doppler signals is normally encountered near the mandible, but in both of our cases, marked increases in frequency (10 and 11 kHz) were heard. The presence or absence of turbulent flow distal to the lesion could not be assessed since the mandible limited the extent of examination. Extension of high velocity flow into the diastolic part of the cardiac cycle was not observed, and possibly this finding should have indicated that these stenoses were not hemodynamically significant. In any event, corroborative findings obtained through measurement of common carotid resistivity or use of oculoplethysmography might once again have prevented these errors.

Inaccessible stenosis. In one instance, a serious common carotid stenosis located below the clavicle was overlooked because it was inaccessible to the Doppler sound beam. Severe turbulence in the common carotid might have alerted the interpreter to the existence of the lesion, although definitive Doppler results were not possible.

A major shortcoming of the Doppler technique is the relatively limited field accessible to examination. Occlusive lesions are common at the origin of the common carotid and in the carotid siphon, and are inaccessible to Doppler study. It may be argued that since most of these lesions are surgically inaccessible, their detection is insignificant. Nonetheless, knowledge of the existence of such lesions may be very important in explaining symptoms and evaluating a patient's prognosis. The capability of procedures such as common carotid resistivity and oculoplethysmography for detecting lesions outside of the range of Doppler examination is a strong argument for routine use of such studies in conjunction with Doppler evaluation.

Obscured signals. A densely calcified plaque obscured a major stenosis (fig. 18) in one patient. Severe turbulence distal to the "nonsounding" calcified zone was ignored by

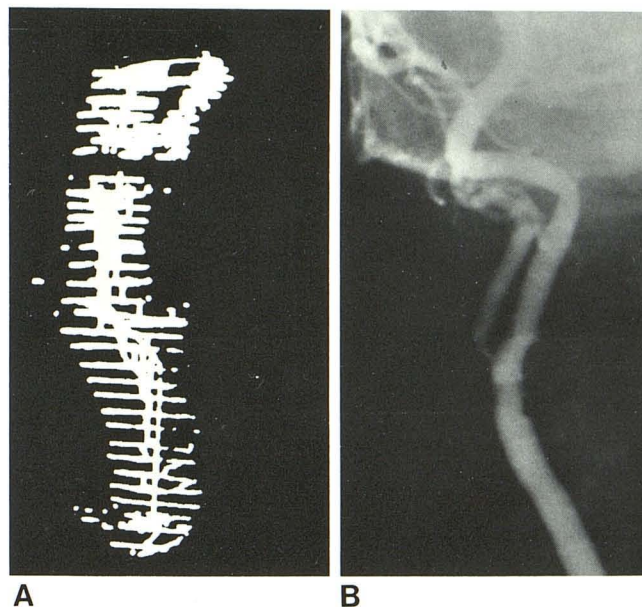


Fig. 19.—Error in localization in 79-year-old woman with previous left hemisphere stroke and bilateral bruits. Doppler examination on right was thought to indicate hemodynamically significant stenosis of internal carotid. **A**, Sonogram. Branch vessels were nearly superimposed, making imaging difficult. **B**, Anteroposterior arteriogram. Severe external carotid stenosis and relatively normal internal carotid, which was superimposed on external carotid in coronal plane. Error of localization might have led to patient mismanagement.

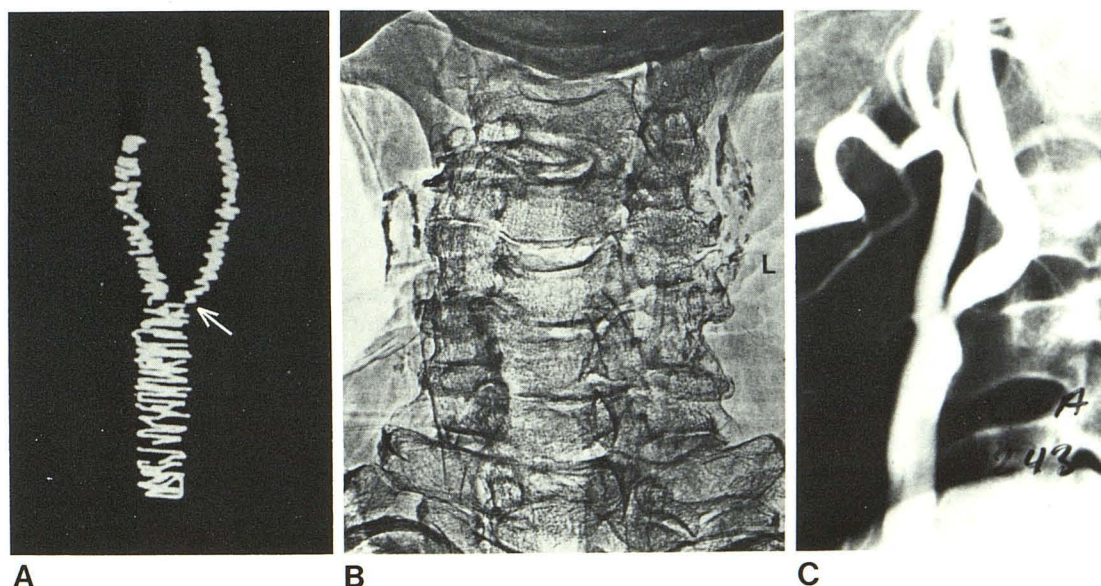


Fig. 18.—Obscured signals. False-negative diagnosis of stenosis due to calcified plaque in 65-year-old man with peripheral vascular disease and bilateral cervical bruits. **A**, Doppler examination on left demonstrated nonsounding area (arrow) in proximal internal carotid. Severe turbulent flow was evident distal to this and posterior orbital flow was reversed on left. **B**, Neck xerogram. Extensive calcification at left carotid bifurcation was believed to account for absence of Doppler signals and failure to detect an abnormal Doppler frequency shift. **C**, Arteriogram. Major stenosis in zone of dense calcification.

the interpreter and might have warned of the presence of the stenotic lesion.

In another patient, a major external carotid stenosis was obscured by very strong internal carotid signals. Although this error was not of clinical importance, it is a useful reminder that with continuous-wave Doppler instruments, signals arising in one part of the carotid bifurcation may obscure weak, high frequency signals related to a stenosis in a nearby or superimposed area.

Unexplained errors. In two patients, errors regarding carotid occlusive disease were made, for which no cause could be assigned.

Errors in localization. Errors in localization of hemodynamically significant stenosis and occlusion (fig. 19) were frequent. It appears that such inaccuracies result from the relatively large sample volume used in continuous-wave Doppler equipment and from the anatomic variability of the carotid bifurcation. Errors of localization could have led to inappropriate patient management in three of our cases if arteriograms had not been subsequently obtained. In one of the patients, an external carotid stenosis was mistakenly diagnosed as being in the internal carotid. The second instance involved localization of an external carotid stenosis at the carotid bifurcation. In a third case, internal carotid occlusion was mistakenly interpreted as obstruction of the external carotid. Most of the other localization errors involved the bifurcation and internal carotid, and since lesions at either location may affect the cerebral circulation, these inaccuracies did not result in management errors.

Management errors related to mistaken localization of carotid lesions may be prevented through use of data from posterior orbital and periorbital examination as well as from carotid resistivity or oculoplethysmography. If external carotid collateral flow is documented, significant lesions of the common carotid, carotid bulb, and main trunk of the external carotid can be excluded. Common carotid resistivity and oculoplethysmography should be normal if a lesion is confined to the external carotid, and abnormal if the lesion is in the common carotid, the bulb, or the internal carotid. Precise Doppler signal localization, which may become available in conjunction with duplex instrumentation, should be of additional value in avoiding errors of localization.

To conclude, the errors associated with complete occlusion were relatively more common than those with stenosis. The error rate for occlusion did not improve with increased sonographer and sonologist experience. This is believed to be related to the use of negative information for diagnosis of occlusion. Analysis of errors indicated that most false-positive and -negative results as well as errors of localization could have potentially been prevented by measurement of common carotid resistivity or through use of other ancillary noninvasive technique to augment the information obtained by Doppler sonography.

REFERENCES

1. Spencer MP, Reid JM, Davis DL, Paulson PS. Cervical carotid imaging with a continuous-wave Doppler flowmeter. *Stroke* **1974**;5:145-154
2. Barnes RW, Bone GE, Reinertson J, Slaymaker EE, Hokanson DE, Strandness DE. Noninvasive ultrasonic carotid angiography: prospective validation by contrast arteriography. *Surgery* **1976**;80:328-335
3. Crummy AB, Zwiebel WJ, Barriga P, et al. Doppler evaluation of extracranial cerebrovascular disease. *AJR* **1979**;132:91-93
4. Silva MB, O'Donnell JA, Hobson RW. Capabilities and limitations of pulsed Doppler sonography in carotid imaging. *JCU* **1980**;8:405-412
5. Thomas GI, Spencer MP, Jones TW, Edmark KW, Stavney LS. Noninvasive carotid bifurcation mapping. *Am J Surg* **1974**;128:168-174
6. Spencer MP, Brockenbrough EC, Davis DL, Reid JM. Cerebrovascular examination using Doppler C-W ultrasound. In: White D, Brown RE, eds. *Ultrasound in medicine*, vol 3B. New York: Plenum, **1977**:1291-1310
7. Zwiebel WJ, Crummy AB, Barriga P, et al. Extracranial cerebrovascular Doppler examination. Results and sources of error. *Neuroradiology* **1978**;16:145-146
8. Spencer MP. Hemodynamics of carotid artery stenosis. In: Spencer MP, Reid JM. *Cerebrovascular evaluation with Doppler ultrasound*. The Hague, Netherlands: Martinus-Nijhoff, **1980**:113-131
9. DeWeese JA, May AG, Lipchik EO, et al. Anatomic and hemodynamic correlations in carotid artery stenosis. *Stroke* **1970**;1:149-157
10. Planilo T, Pourcelot L, Pottier JM, et al. Etude de la Circulation Carotidienne par les Methodes Ultrasoniques et la Thermographie. *Rev Neurol (Paris)* **1972**;126:127-141
11. Courbier R, Reggi M, Jausseran JM. Exploration of carotid arteries and vessels of the neck by Doppler techniques. In: Diethrich EB, ed. *Noninvasive cardiovascular diagnosis: current concepts*. Baltimore, MD: University Park, **1978**:61-73
12. Kartchner MM, McRae LP. Noninvasive evaluation and management of the "asymptomatic" carotid bruit. *Surgery* **1977**;82:840-847
13. Gee W, Oller DW, Amundsen DG, Goodreau JJ. The asymptomatic carotid bruit and the ocular pneumoplethysmography. *Arch Surg* **1977**;112:1381-1388
14. Machleder HI, Barker WF. Noninvasive methods for evaluation of extracranial cerebrovascular disease. *Arch Surg* **1977**;112:944-946
15. Davis RC, Gingery RO. A noninvasive carotid artery system as accurate as carotid arteriography. Presented at the annual meeting of the American Institute of Ultrasound in Medicine, San Diego, August **1978**
16. Vannix RS, Joergenson EJ, Carter R. Kinking of the internal carotid artery, clinical significance and surgical management. *Am J Surg* **1977**;134:82
17. Lochridge SK, Rossi NP. Symptomatic kinked internal carotid artery. *J Cardiovasc Surg (Torino)* **1980**;21:108-111