



Discover Generics

Cost-Effective CT & MRI Contrast Agents



FRESENIUS
KABI

WATCH VIDEO

AJNR

Brain density and cerebrospinal fluid space size: CT of normal volunteers.

L A Cala, G W Thickbroom, J L Black, D W Collins and F L Mastaglia

AJNR Am J Neuroradiol 1981, 2 (1) 41-47

<http://www.ajnr.org/content/2/1/41>

This information is current as
of June 20, 2025.

Brain Density and Cerebrospinal Fluid Space Size: CT of Normal Volunteers

Lesley A. Cala¹
 Gary W. Thickbroom²
 John L. Black²
 David W. K. Collins²
 Frank L. Mastaglia³

This study attempted to establish normal values for cerebral white and deep gray matter density and total brain density, and to discover how much dilatation of the cerebrospinal fluid-containing spaces occurs with advancing age up to 40 years. The 53 female and 62 male healthy volunteers, 15–40 years old, had been screened to exclude individuals with neurologic disease, previous head trauma, congenital or acquired heart disease, chronic pulmonary disease and other systemic illness, and those who consumed more than small amounts of alcoholic beverages. The computed tomography scan data for the 115 subjects were scored subjectively for the severity of atrophy. It was found that in both genders there was an increasing frequency with advancing age of sulcal widening of the frontal lobes and cerebellar vermis starting in the teens. A ventriculo–internal cranial ratio was calculated for 93 subjects who had been examined on the EMI CT 1010, the mean value being 0.31 ± 0.08 for females and 0.33 ± 0.06 for males. The ratio did not change significantly with age up to 40 years. On the same 93 subjects, mean values and standard deviations were obtained for normal white matter (30.1 ± 3.5 Hounsfield units (H) for females and 29.8 ± 3.3 H for males) and for normal deep gray matter (33.0 ± 3.3 H for females; 33.2 ± 2.6 H for males) and for total brain density (33.9 ± 2.7 H for females; 33.6 ± 2.6 H for males).

Normal data for brain density and for the dimensions of the ventricular system and subarachnoid spaces are required for interpretation of the computed tomography (CT) scan in patients under investigation for neurologic diseases. A number of previous studies of these parameters have been based on the analysis of selected normal CT scans performed for diagnostic purposes [1–6]. There have been few studies of normal volunteers [1, 7–9] and few systematic studies of changes associated with aging [1, 2, 7]. Moreover, previous studies of brain density were performed with the older water-bag scanning models and there are no normal volunteer data from the newer EMI CT 1010 scanners. We report the results of a 4 year study of the normal CT scan which began to provide control data for a study of patients with demyelinating disease [10]. Data are presented on brain density in 93 normal volunteers and lateral ventricular size and sulcal widening in a group of 115 normal volunteers 15–40 years old.

Subjects and Methods

Volunteers were from various backgrounds, but there was a preponderance of medical and nonmedical professional people, some of whom were still students at secondary or tertiary schools. The subjects knew they were participating in a research study; they were not paid and they signed an informed consent form approved by the Human Rights Committee of the University of Western Australia. Radiation exposure conformed to the regulations of the National Health and Medical Research Council of Australia. Parents gave written permission for minors.

The study group comprised 53 females and 62 males. Their ages are shown in table 1.

Received March 20, 1980; accepted after revision August 13, 1980.

This work was supported in part by a grant from the National Health and Medical Research Council of Australia and by the Special Purposes Fund, Radiology, Sir Charles Gairdner Hospital.

¹Department of Diagnostic Radiology, Sir Charles Gairdner Hospital, Queen Elizabeth II Medical Centre, Nedlands, Western Australia 6009. Address reprint requests to L. A. Cala.

²Department of Biophysics, Sir Charles Gairdner Hospital, Queen Elizabeth II Medical Centre, Nedlands, Western Australia 6009.

³Department of Medicine, University of Western Australia, and Queen Elizabeth II Medical Centre, Nedlands, Western Australia 6009.

AJNR 2:41–47, January/February 1981

0195–6108/81/0021–0041 \$00.00

© American Roentgen Ray Society

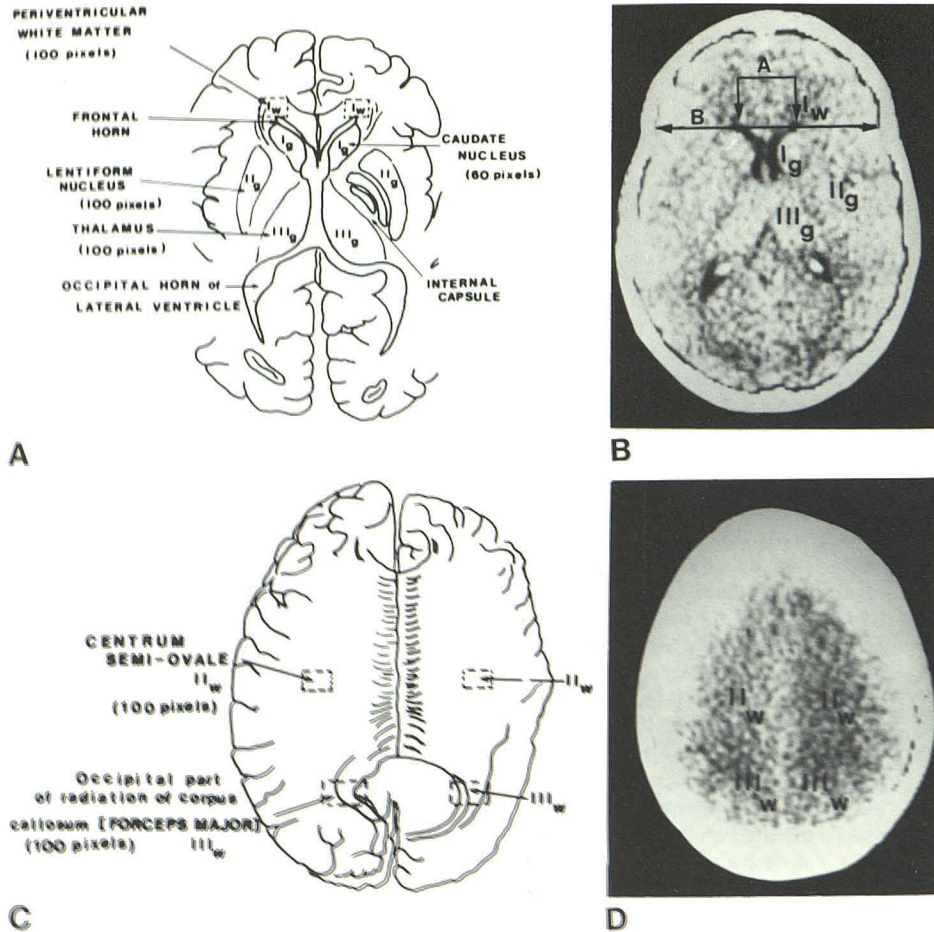


Fig. 1.—A and B, 3A level. Gray matter sites, I_g (caudate nucleus), II_g (lentiform nucleus), and III_g (thalamus), frontal periventricular white matter (I_w). Evans ratio = bifrontal ventricular span (A):internal cranial diameter at level of frontal horns (B). C and D, 4A level. White matter sites II_w (centrum ovale) and III_w (forceps major).

TABLE 1: Age and Gender Distribution

Age (yrs)	Gender (no.)	
	Female	Male
15-19	6	7
20-24	11	20
25-29	15	15
30-34	13	13
35-39	8	5
40-44	0	2

Note.—Mean age was 27.4 years (SD 6.1) for females and 26.2 (SD 6.2) for males.

All except eight subjects (four females, four males) were right-handed. Individuals with a history of head trauma, alcohol intake in excess of six glasses of beer or equivalent per week, or frequent migrainous headaches were excluded.

The results from 24 subjects (10 females and 14 males) examined on the Mark I EMI water-box head scanner and 91 subjects (43 females and 48 males) examined on the EMI CT 1010 head scanner were combined for assessment of cerebrospinal fluid spaces. All studies were performed parallel to the canthomeatal line.

Those subjects examined on the older unit had three tomographic cuts, yielding six contiguous 13 mm slices. Those studies on the newer unit were found to need four tomographic cuts (eight contiguous slices), allegedly 13 mm thick. In fact, repeated calibrations have shown that the slice thickness is only about 9 mm. The

"normal" mode provided on the machine with a scanning time of 60 sec and an image on a 160×160 matrix was used, with 120 kVp and 33 mA.

With both the old and new installations, the cathode ray tube visual display was permanently recorded on Polaroid film and a 160×160 matrix printout was obtained of all sections. Volunteers were informed that a duplicate set of pictures was taken and stored in the hospital medical records department and that these would be used for comparison if a subsequent diagnostic scan was necessary.

In view of the significant margin of error involved in the measurement of the width of the cortical sulci and other small cerebrospinal fluid-containing structures [10], a semiquantitative five grade scoring system (0 to 4+) similar to that of Huckman et al. [11] was used to record the width of the subarachnoid spaces over each lobe of the cerebrum and over the cerebellar hemispheres and vermis. Measurements of ventricular span and internal cranial diameter were made on the computer printout at the level of the frontal horns and the ratio of these two measurements (developed by Evans [12]) was calculated in each case. (Although Evans originally described the ratio as that of frontal horns: greatest biparietal diameter of the skull, we used the above-described modification.)

For assessment of brain density, 43 women (mean age 27.6 ± 6.2 years) and 50 men (mean age 26.0 ± 5.8 years), 15-40 years old, were selected who had been examined on the EMI CT 1010 scanner. Three areas deep gray matter, head of caudate nucleus, lentiform nucleus, and thalamus (fig. 1B), and three areas of deep hemisphere white matter, frontal periventricular (fig. 1B) and corona

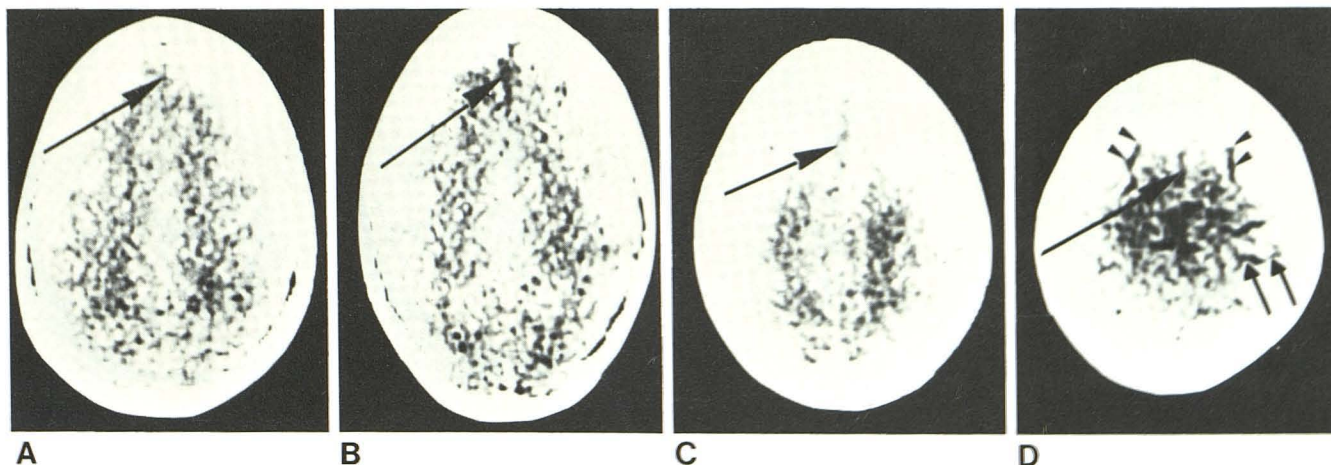


Fig. 2.—A, Grade 0 atrophy of frontal lobes. Barely discernible interhemispheric fissure (arrow). B, Grade 1. Anterior end of interhemispheric fissure easily seen (arrow). C, Grade 2. Anterior end and middle third of interhemispheric fissure identifiable (arrow). D, Grade 3. Widened inter-

hemispheric fissure (long arrow) and lateral frontal sulci (arrowheads). This slice, a few millimeters superior to A–C, shows appearance of remaining cortical convexity when affected by grade 3 atrophy (short arrows).

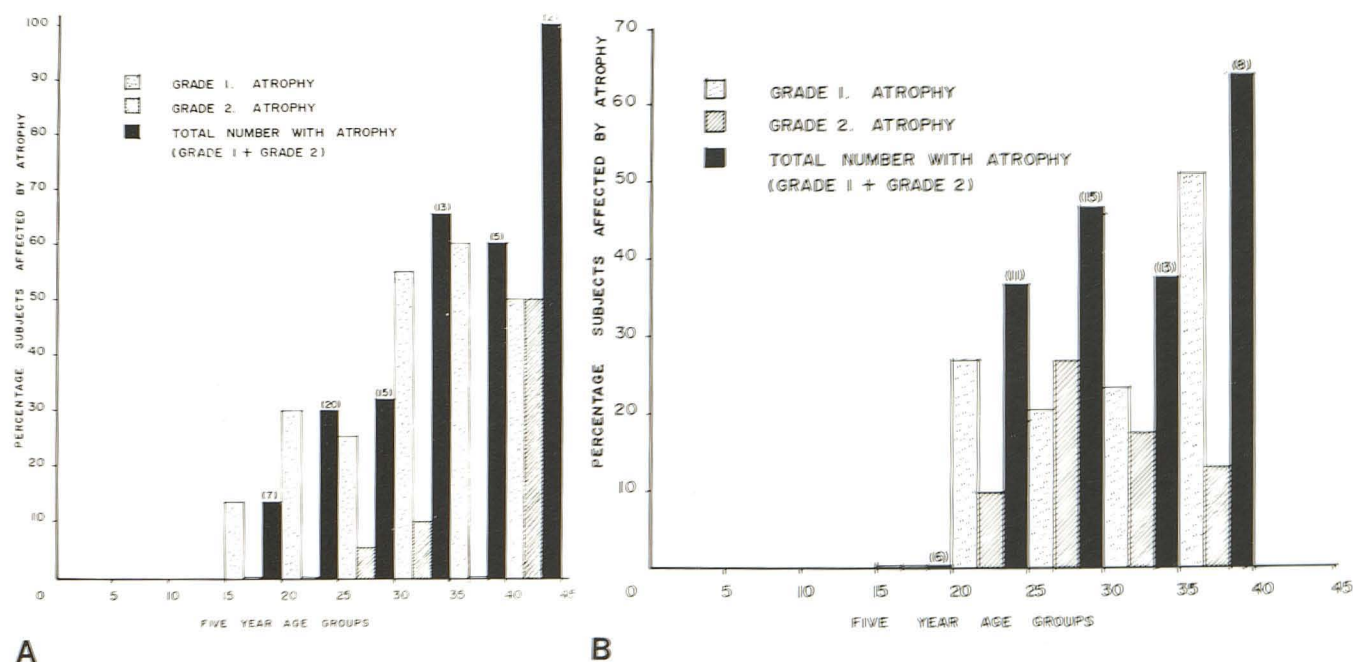


Fig. 3.—Frequency of frontal lobe atrophy in normal males (A) and females (B). Numbers in parentheses are numbers of subjects.

radiata and centrum semiovale (fig. 1D), were chosen from the printouts of two of the slices, as described by Arimitsu et al. [3].

Calculations were made on 60–100 pixels from the center of each area marked in figure 1 and a mean attenuation coefficient and standard deviation was obtained for each area. The nomenclature of levels 3A and 4A in figure 1 has been used in all other figures and tables for convenience and brevity. Total brain density was obtained by pooling the deep gray and white matter attenuation coefficients between 15 and 60 using the EMI histogram presentation of Hounsfield units and estimating an average value. Calculations from printouts and histograms were then done, partly by hand and partly with a PDP 11/40 computer. A cursor was not

used for the area of interest in any of the estimations because it is either a circle or a square, which often did not coincide with the shape of the particular area.

Results

Cerebrospinal Fluid Spaces

It was found that for both males and females, there was an increasing frequency of atrophy in the frontal region with age until, by age 40 years, nearly all subjects showed this

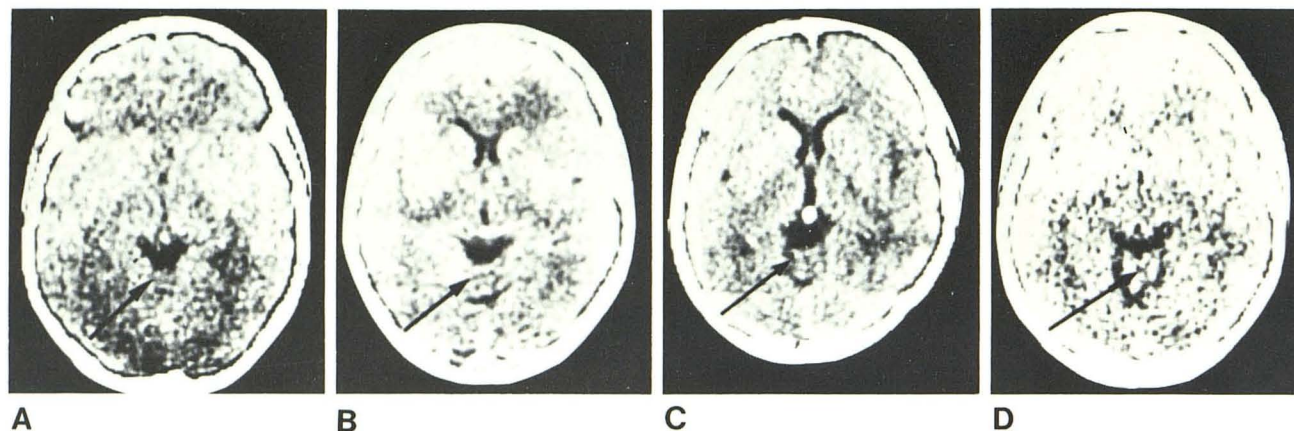


Fig. 4.—A, Grade 0 atrophy of cerebellar vermis. Faint groove at posterior end of quadrigeminal cistern. Intact vermis (arrow). B, Grade 1. Anterior and posterior limits of vermis and one sulcus (arrow) more clearly visible. C,

Grade 2. Several vermiform sulci (arrow). D, Grade 3 atrophy (arrow). Well defined lateral superior cerebellar cisterns with pool of cerebrospinal fluid anteriorly and posteriorly leaves vermis isolated as island of tissue.

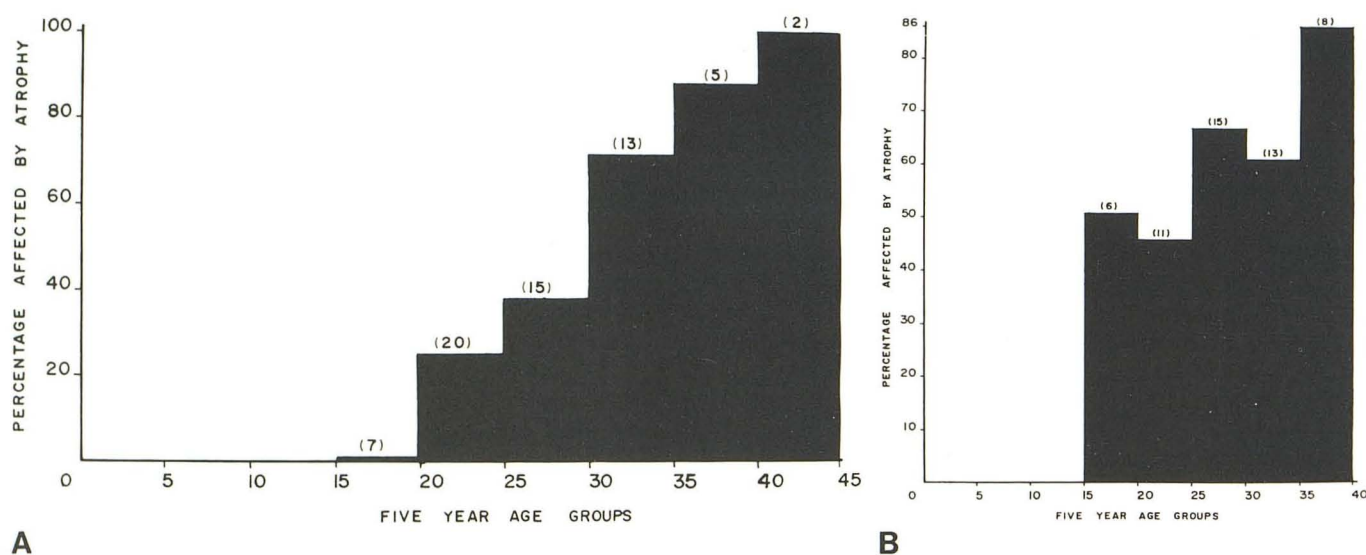


Fig. 5.—Frequency of vermis atrophy, grades 1 and 2, in normal males (A) and females (B). Numbers in parentheses indicate numbers of subjects.

TABLE 2: Summary of Brain Density Results with Evans ratio [12]

Area	Mean Density (H) (SD)	
	Females (n = 43)	Males (n = 48)
Gray matter	32.95 (3.30)	33.23 (3.21)
White matter	30.09 (3.51)	29.75 (3.30)
Gray/white difference	2.86 (1.97)	3.48 (2.04)
Total brain density	33.93 (2.68)	33.55 (2.57)
Ventricular span/internal cranial diameter ratio	0.31 (0.08)	0.33 (0.06)

finding (figs. 2 and 3), but none exceeded grade 2. None of the other lobes in the supratentorial compartment showed any atrophy. Similarly, an increasing frequency of atrophy of the cerebellar vermis was found with advancing age (figs.

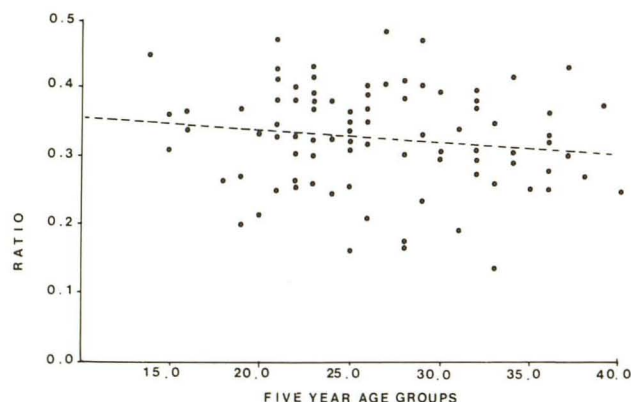
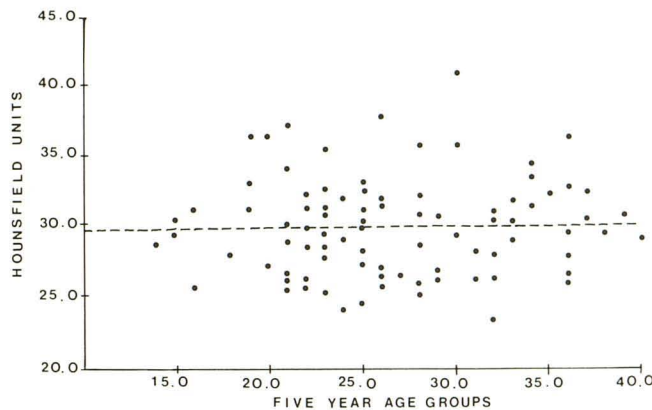
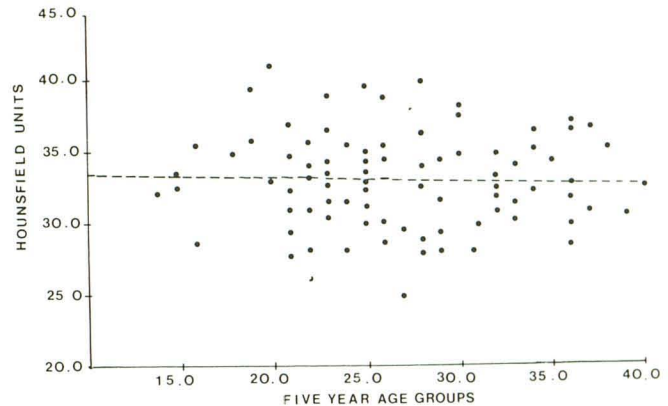


Fig. 6.—Distribution of modified Evans ratio for both genders. Downward slope not significant. Y intercept = 0.37, 95% confidence interval = 0.30–0.43; slope = -0.002 , 95% confidence interval = -0.004 – 0.0008 ; correlation coefficient = -0.13 .



A

Fig. 7.—Distribution of white (A) and gray (B) matter density with age for both genders. Y intercept = 29.35 (A) and 33.76 (B), 95% confidence interval = 26.2–32.5 (A) and 30.8–36.8 (B); slope = 0.021 (A) and –0.025



B

(B), 95% confidence interval = –0.09–0.14 (A) and –0.13–0.09 (B); correlation coefficient = 0.04 (A) and –0.05 (B).

4 and 5), but again the severity only reached grade 2. By contrast, only nine of the 115 subjects showed any atrophy of the cerebellar hemispheres.

It was found that fewer women showed frontal lobe atrophy but those who did exhibit this finding tended to have grade 2 atrophy more often than men (fig. 3). In our carefully selected population, no men or women had grade 3 or 4 frontal lobe atrophy until age 40 years. Figure 2D shows grade 3 frontal lobe atrophy.

The modified ratio of Evans [12] was found to be 0.31 ± 0.08 in females and 0.33 ± 0.06 in males (table 2), the differences between genders not being statistically significant. The ratios for the male and female subjects were combined and plotted against age (fig. 6), the slope of the line not being significantly different from zero at the 95% confidence limit. That is, there is no statistically significant change with advancing age up to 40 years. The interrupted line is the result of a linear least squares fit to all data points.

Brain Density

The results are summarized in table 2. Both males and females showed a mean value of about 33 H for deep gray matter and 30 H for white matter. Our installation is checked once a week and the mean value for a water phantom is –3––4 H with a standard deviation of 3–4 H. This indicates that the standard deviation of the installation and the deep gray/white matter difference are of the same order. Therefore, it is important to perform adequate quality control and check drift on a regular basis to be able to continue to discriminate white from deep gray matter.

The values for males and females were then combined to assess any change in deep gray or white matter density with advancing age (fig. 7). No statistically significant change of density with age was demonstrated up to age 40 years. The spread of deep gray matter (25–41 H) and white matter (24–41 H) was calculated, and from this the deep gray/white matter difference for all subjects was found to be 3.2 ± 2.0 H. Weinstein et al. [13] found a gray/white difference

of 6 H but his age group were not stated; Arimitsu et al. [3] found a difference of 7 H but their subjects were of an older average age than in our study. The deep gray/white matter difference was plotted against age but again no statistically significant change was demonstrated (fig. 8).

A histogram was then prepared of all the EMI values on slices 3A and 4A by the EMI CT 1010 computer. From our initial calculation for white and deep gray matter densities, obtained manually from the printouts, values below 15 H and above 60 H were excluded as not representative of brain but the range chosen still would have included some pixels representing extracranial soft tissues. The mode, median, and average brain density values were calculated manually from the EMI numbers retained on the histogram that had been produced by the computer. For 3A the modes were 23–41 H; average, 30.8 ± 3.4 H. The medians were 25–40 H; average, 31 ± 3.0 H. The average total brain densities were 28–41 H; average, 32 ± 3.0 H. On the 4A slice the modes were 24–42 H; average, 32.0 ± 4.0 H. The medians were 27–43 H; average, 34.0 ± 3.0 H. The average total brain densities were 30–43 H; average, 36.0 ± 3.0 H. The averages for levels 3A and 4A were summated to obtain total brain density: range, 29–40 H; average, 34.0 ± 3.0 H. Again the values for total brain density were plotted for each of the subjects against age (fig. 9). No statistically significant change with age until 40 years was found.

Our findings were compared with those of Reese et al. [2]. They found a slight but not significant downward slope for total brain density with advancing age between 21 and 90 years (fig. 10). By combining the 93 subjects in our series with the 100 subjects of Reese et al., it can be stated that between ages 15 and 90 years no change in total brain density is discernible by CT, whether using the EMI CT 1010 (as in our series) or the old water-box unit of Reese et al.

Discussion

In the supratentorial compartment, it appears that only the frontal lobe shows demonstrable shrinkage under age

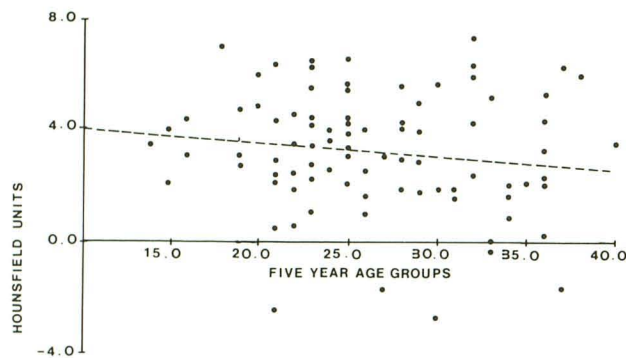


Fig. 8.—Distribution of deep gray/white matter difference with age for both genders. Y intercept = 4.41, 95% confidence interval = 2.55–6.28; slope = -0.046 , 95% confidence interval = -0.11 – 0.02 ; correlation coefficient = -0.14 .

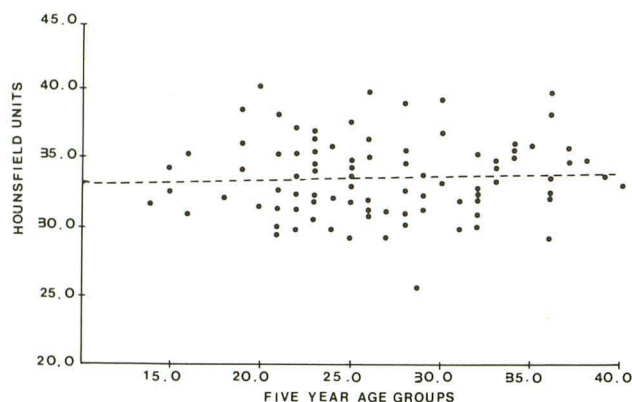


Fig. 9.—Distribution of average total brain density with age for all subjects. Y intercept = 32.89, 95% confidence interval = 30.46–35.31; slope = 0.032 , 95% confidence interval = -0.06 – 0.12 ; correlation coefficient = 0.07 .

40 years. Therefore, the finding of sulcal widening in other regions of the cerebral hemispheres may be regarded as pathologic. Some atrophy of the cerebellar vermis can occur, but it is very infrequent in the cerebellar hemispheres, so that the finding of widened hemispheric sulci should again suggest a pathologic disturbance. While evidence of shrinkage of brain substance was obvious from the progressing prominence of the subarachnoid spaces, the ratio taken as Evans ratio at the level of the frontal horns remained unchanged. If the ratio does change with age it must do so after age 40 years.

Zatz [14] described how the original conclusions favoring the ratio, rather than the bifrontal span alone, were based on an error in the calculations. However, we are satisfied with the ratio of bifrontal span: internal skull diameter at the level of the frontal horns and find that it is a constant with advancing age in normal subjects. In 180 patients and 20 volunteers, ages 10–81 years, Hahn and Rim [15] found that the bifrontal span was 28% of the internal cranial diameter at 15 years of age and 31% at 70 years, so there was a very slight change with advancing years. Their final conclusions were that a maximum bifrontal diameter greater than 40% of the internal cranial diameter and less than 18% is highly suspicious of abnormal ventricles.

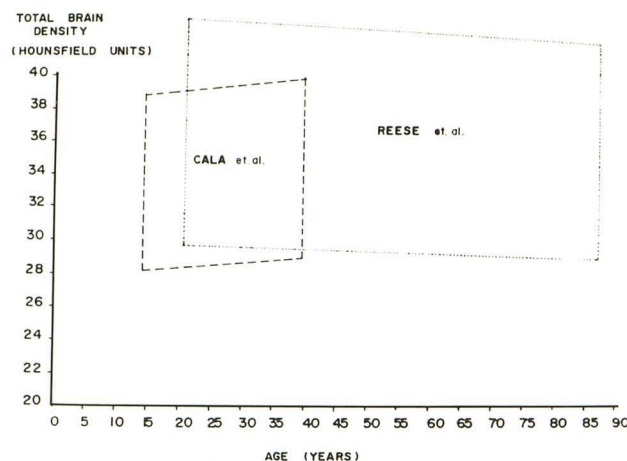


Fig. 10.—Comparison of our values for total brain density in the 15–40 year age group with those of Reese et al. [1] in the 21–90 year group. Each parallelogram contains 96% of the individual data points, the upper and lower edge being 2 SD from the mean of the data.

Meese et al. [16], who used the external skull diameter at the level of the frontal horns: bifrontal ventricular span (frontal horn index) in 170 individuals, 6 months to 71 years old, found a ratio of skull: ventricles of 4 or an inverse ratio of 0.25 until age 40 years. Thus our population had slightly larger ventricles at 0.3 but this may be accounted for by the use of the internal skull diameter.

Our results for brain density are comparable to those found in previous studies [1–3]. Our deep gray/white matter difference of 3.2 ± 2.0 H is lower than that reported by Arimitsu et al. [3], but their subjects were of an average older age. Since there is such a small difference between white and deep gray matter density values in normal subjects, any unusual change (outside the standard deviation for the machine) may suggest pathology and may be valuable in the diagnosis of diseases of white or deep gray matter [3].

REFERENCES

1. Reese DF, Beeler GW, O'Brien PC, Gerding PR, Romme CR. A statistical analysis and comparison of two sets of 100 normal CT brain scans. Presented at the annual meeting of the American Society of Neuroradiology, Bermuda, March 1977
2. Reese DF, O'Brien PC, Beeler GW, Gerding PR, Clifford CR. A statistical description of the normal computerized brain scan. *AJR* 1977;129:457–462
3. Arimitsu T, di Chiro G, Brooks RA, Smith PB. White-gray matter differentiation in computed tomography. *J Comput Assist Tomogr* 1977;1:437–442
4. Brassow F, Baumann K. Volume of brain ventricles in man determined by computer tomography. *Neuroradiology* 1978;16:187–189
5. Gyldensted C, Kosteljanetz M. Measurements of the normal hemispheric sulci with computer tomography: a preliminary study on 44 adults. *Neuroradiology* 1975;10:147–149
6. Gyldensted C, Kosteljanetz M. Measurements of the normal ventricular system with computer tomography of the brain. A preliminary study on 44 adults. *Neuroradiology* 1976;10:205–213

7. Barron SA, Jacobs L, Kinkel WR. Changes in size of normal lateral ventricles during aging determined by computerized tomography. *Neurology* **1976**;26:1011-1013
8. Haug G. Age and sex dependence of the size of normal ventricles on computed tomography. *Neuroradiology* **1977**;14:201-204
9. Gonzalez CF, Lantieri RL, Nathan RJ. The CT scan appearance of the brain in the normal elderly population: a correlative study. *Neuroradiology* **1978**;16:120-122
10. Cala LA, Mastaglia FL. Computerized axial tomography of the cranium and orbits in multiple sclerosis. *J Neurol Sci* **1978**;36:411-426
11. Huckman MS, Fox JH, Topel J. The validity of criteria for the evaluation of cerebral atrophy by computed tomography. *Radiology* **1975**;116:85-92
12. Evans WA Jr. An encephalographic ratio for estimating ventricular enlargement and cerebral atrophy. *Arch Neurol Psychiatr* **1942**;47:931-937
13. Weinstein MA, Duchesneau PM, MacIntyre WJ. White and gray matter of the brain differentiated by computed tomography. *Radiology*, **1977**;122:699-702
14. Zatz LM. The Evans' ratio for ventricular size: a calculation error. *Neuroradiology* **1979**;18:81-82
15. Hahn FJY, Rim K. Frontal ventricular dimensions on normal computed tomography. *AJR* **1976**;126:593-596
16. Meese W, Kluge W, Grumme T, Hopfenmüller W. CT evaluation of the CSF spaces of healthy persons. *Neuroradiology* **1980**;19:131-136