



Discover Generics

Cost-Effective CT & MRI Contrast Agents



WATCH VIDEO

AJNR

The value of metrizamide CT cisternography in the management of cerebral arachnoid cysts.

S M Wolpert and R M Scott

AJNR Am J Neuroradiol 1981, 2 (1) 29-35

<http://www.ajnr.org/content/2/1/29>

This information is current as
of June 19, 2025.

The Value of Metrizamide CT Cisternography in the Management of Cerebral Arachnoid Cysts

Samuel M. Wolpert¹
R. Michael Scott²

Arachnoid cysts may or may not communicate with the cerebrospinal fluid pathways. Patterns of communication were studied in six patients, using metrizamide computed tomography (CT) cisternography, ventriculography, and cystography. Two types of cysts were found: one with free communication with the cerebrospinal fluid pathways and one with restricted communication. This information can be useful in the surgical management of the cysts. When the cysts freely communicate with the ventricles, ventricular shunting is the appropriate therapy, whereas when the cysts are noncommunicating, direct shunting of the cyst is indicated.

Intracranial arachnoid cysts can easily be diagnosed by computed tomography (CT), and further invasive studies are rarely necessary to demonstrate their topography. However, pneumoencephalography is useful to demonstrate communication of the cyst with the ventricles or with the subarachnoid spaces [1]. This communication can also be studied by obtaining CT scans after injecting the water-soluble contrast agent, metrizamide, into the ventricles, the lumbar subarachnoid space, or directly into the cerebral cyst. In our study, the metrizamide flow into and out of intracranial cysts was evaluated in a series of six patients. The results suggest that there are two types of cysts: one with free and another with restricted communication with the cerebrospinal fluid pathways. This information can be of importance for the surgical management of these patients.

Materials and Methods

Six patients with intracranial fluid-containing cysts were studied by CT after metrizamide was injected into the cysts, the ventricles, or the cerebrospinal fluid pathways [2]. Five of the cysts were in the posterior fossa (including two extending through the incisura), and one cyst was in the middle cranial fossa. Of the five posterior fossa cysts, two were retrocerebellar in location, one was in the cerebellopontine angle cistern, one involved the quadrigeminal plate cistern and extended superiorly into the ambient cistern, and one cyst appeared to involve the fourth ventricle. (It may be appropriate to consider the retrocerebellar lesions not as cysts but as enlarged cisternae magnae [3]. However, in this paper, the term *cysts* will be used.) After injection of 3–4 ml (170–220 mg I/ml) metrizamide solution, CT scans were obtained immediately and at varying time intervals (up to a maximum of 72 hr in one patient). In one patient, only immediate scans were obtained.

The kinetics of metrizamide flow were evaluated by obtaining serial CT images of the cysts, as well as by measuring their mean x-ray attenuation coefficients at different times after injection of metrizamide. The attenuation coefficients were obtained with a region-of-interest cursor [4] and were tabulated in graphic form. Since the magnitude of the changes in x-ray attenuation coefficients was large, there was no need to compensate for drift of the coefficients with time, which can be a factor when small changes in attenuation coefficients are determined [5]. The clinical data, CT findings, and method of treatment are summarized in table 1.

Received April 23, 1980; accepted after revision August 13, 1980.

¹ Department of Radiology, Section of Neuro-radiology, Tufts-New England Medical Center, 171 Harrison Ave., Boston, MA 02111. Address reprint requests to S. M. Wolpert.

² Department of Neurosurgery, Tufts-New England Medical Center, Boston, MA 02111.

AJNR 2:29–35, January/February 1981
0195–6108/81/0021–0029 \$00.00
© American Roentgen Ray Society

TABLE 1: Clinical and Radiologic Findings in Intracranial Arachnoid Cysts

| Case No. | Clinical | CT | CT MTZ | Surgery |
|----------|---|--|---|--|
| 1. | 11 months old: bulging fontanelle (Pierre Robin, cleft palate, choanal atresia) | Mild hydrocephalus; posterior fossa cyst | Ventriculogram: OP = 260 mm H ₂ O; cyst communication with ventricles | VP shunt |
| 2. | Newborn: large head | Hydrocephalus; posterior fossa cyst; agenesis corpus callosum | LP: MTZ into cyst only; ventriculogram: OP = 130 mm H ₂ O; cyst communication with ventricles | VP shunt (two subsequent revisions at ages 3 and 12 months) |
| 3. | 16 years old: headaches after football injury | Left temporal fossa cyst; ventricles shifted | LP (after cyst biopsy and shunt); late filling of cyst by diffusion | Cyst: peritoneal shunt |
| 4. | (1) Newborn: premature; large head; (2) 8 months old: head size increased; possible shunt malfunction, mild right hemiparesis | (1) Hydrocephalus; posterior fossa cyst; (2) Collapsed right ventricle | (1) Not performed; (2) MTZ into right shunt: no contrast in left lateral ventricle; shift left to right; ?block 3rd ventricle; MTZ into left shunt: shunt tip in huge left supra- and infratentorial cyst; late filling of ventricles | (1) Right VP shunt; (2) Left cyst: peritoneal shunt |
| 5. | 10 months old: large head; mild left hemiparesis | Ventriculomegaly; posterior fossa cyst | Ventriculogram: OP = 250 mm H ₂ O; blocked aqueduct; at 48 hr, MTZ diffusion into cyst | Posterior fossa craniectomy: quadrigeminal cistern cyst. Cyst: peritoneal shunt; 3 weeks later: VP shunt |
| 6. | 4 months old: seizures and mental retardation | Right cerebellopontine angle cyst (sequential scans showed enlargement); no hydrocephalus; agenesis of corpus callosum | LP: late filling of cyst | Posterior fossa craniectomy: CP angle cyst |

Note.—MTZ = metrizamide; OP = opening pressure; VP = ventriculoperitoneal; LP = lumbar puncture; CP = cerebellopontine.

Results

Our data suggested that there are two types of intracranial cysts. In the first type (cases 1 and 2), there was immediate opacification of the cysts from cerebrospinal fluid pathways. In case 1, a retrocerebellar cyst filled immediately after injection of metrizamide into the enlarged ventricles (Fig. 1). The contrast agent also immediately entered the basal cisterns. Delayed scans and kinetic studies demonstrated clearance of metrizamide from the cyst, ventricles, and basal cisterns by 48 hr (figs. 1 and 2). The patient was treated by ventricular shunting with a good result.

In case 2, a retrocerebellar cyst and the fourth ventricle filled immediately after injection of metrizamide into the lumbar subarachnoid space, but filling of the lateral ventricles did not occur spontaneously (fig. 3). To exclude an aqueductal stenosis as a cause for the hydrocephalus (an incidental agenesis of the corpus callosum was also present), metrizamide was injected into the lateral ventricles and demonstrated their free communication with the fourth ventricle and the retrocerebellar cyst (figs. 3E and 3F). Kinetic studies were not obtained since no further diagnostic information was considered necessary for patient management. (A similar pattern of apparent ball-valve obstruction between the ventricles and the subarachnoid space was demonstrated by air studies in patients with retrocerebellar cysts [6].) A ventriculoperitoneal shunt was successful in decompressing the ventricles, and follow-up scans over an 18

month period showed no enlargement of the posterior fossa cyst.

In the second type of cyst (cases 3–6), the cysts did not freely communicate with the cerebrospinal fluid pathways. In case 3, a patient with a middle cranial fossa cyst, ventricular displacement was present but there was no hydrocephalus. At surgery, an arachnoid membrane lined the outer wall of the cyst, but the nature of the inner walls could not be determined. A biopsy of the membrane revealed elongated fibroblastic cells covered on both surfaces by flattened meningotheelial cells. A cyst-peritoneal shunt was initially carried out, followed by metrizamide CT cisternography. Even though the basal cisterns were well opacified, metrizamide failed to enter the cyst initially, but, on a scan obtained 3 hr later, metrizamide had leaked into the cyst (figs. 4 and 5).

In case 4, a patient with a large posterior fossa cyst extending through the incisura to the region of the left ambient cistern, an enlarged right lateral ventricle was initially shunted at birth. When progressive head enlargement continued, metrizamide injected through the right ventricular shunt revealed no communication with the left lateral ventricle or posterior fossa cyst. A shunt was then inserted on the left side into what was thought to represent an enlarged left lateral ventricle. Metrizamide injected through this shunt entered the cyst directly and revealed its communication with the infratentorial component of the cyst (fig. 6). Free communication with the surrounding subarachnoid space

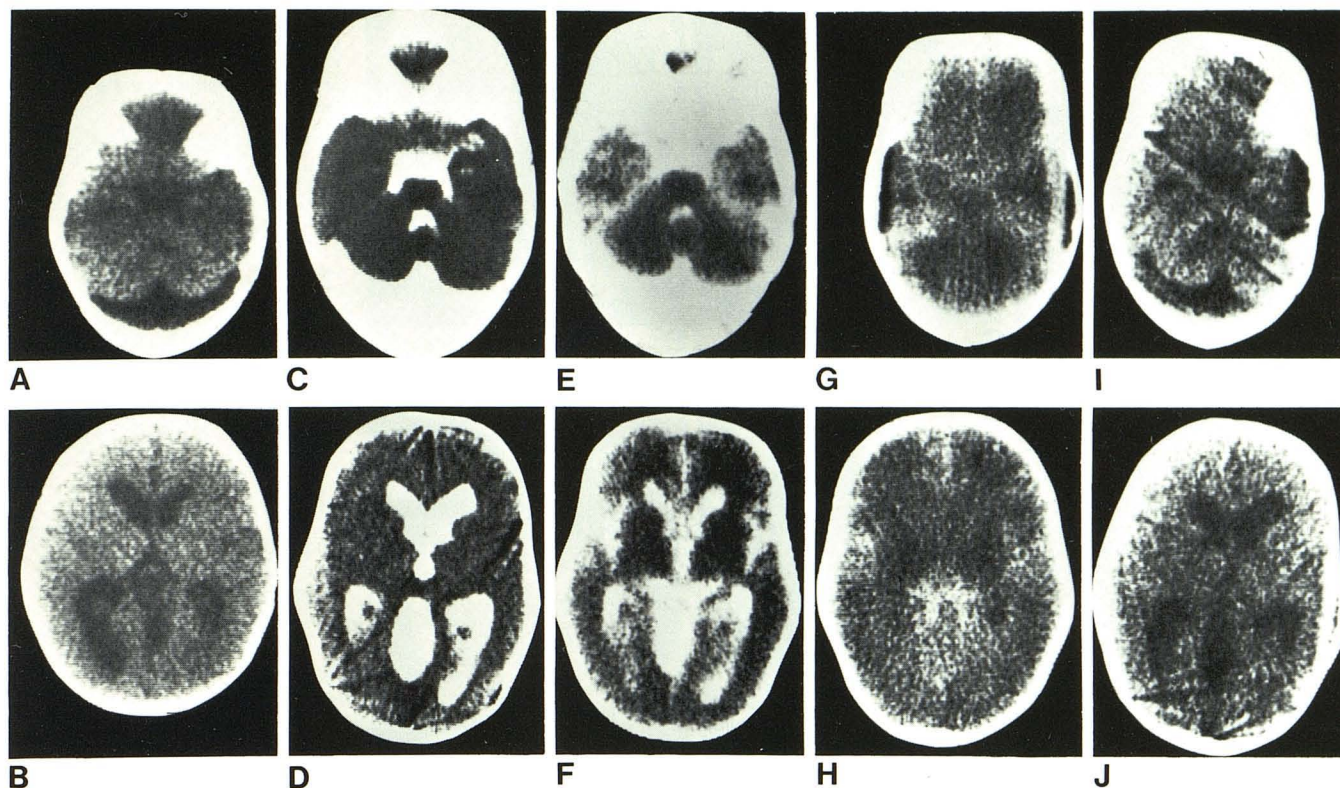


Fig. 1.—Case 1. **A** and **B**, Scans at 4 months of age. Retrocerebellar cyst and mild hydrocephalus of lateral ventricles. **C** and **D**, After metrizamide ventriculography at age 11 months. Immediate opacification of cyst and basal

cisterns. Scans at 12 (**E** and **F**), 24 (**G** and **H**), and 48 (**I** and **J**) hr later. Simultaneous clearance of metrizamide from ventricles, cyst, and basal cisterns.

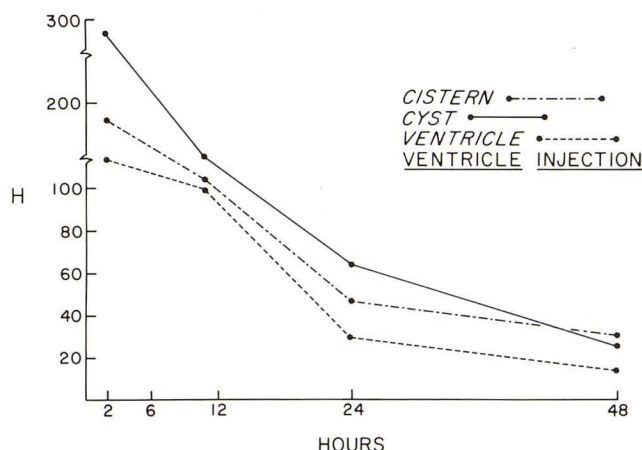


Fig. 2.—Case 1. Attenuation coefficients as Hounsfield units (H) plotted against time up to 48 hr.

did not occur, although diffusion of the contrast agent into both lateral ventricles and the basal cisterns was seen on delayed scans. The diffusion was confirmed by the kinetic study (fig. 7). Subsequent follow-up revealed normal head growth and satisfactory neurologic progress.

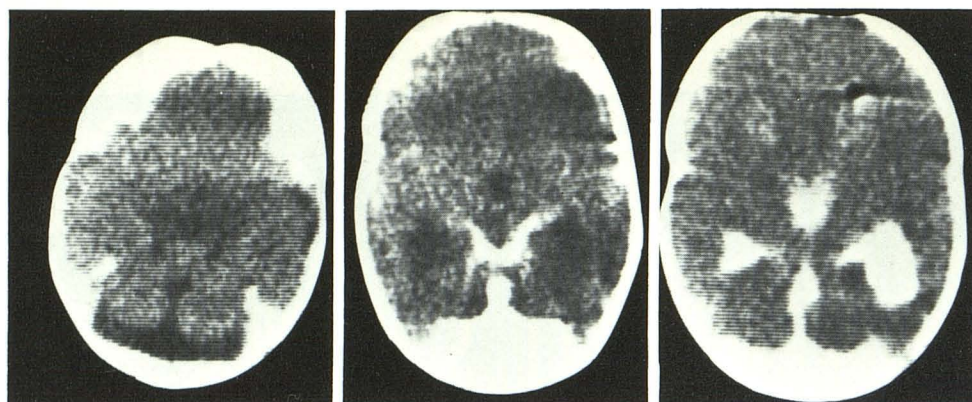
In case 5, a large quadrigeminal cistern cyst extending through the incisura into the posterior fossa caused anterior displacement of the third ventricle and hydrocephalus. A metrizamide CT ventriculogram was obtained. The metrizamide slowly diffused into the cyst over a period of 48 hr (figs. 8 and 9). A cyst of the quadrigeminal cistern was

surgically confirmed, and a biopsy of the cyst wall revealed a membrane covered with flattened epithelioid cells consistent with an arachnoid cyst. Hydrocephalus continued despite fenestration of the cyst and cyst-peritoneal shunting. A ventriculoperitoneal shunt was finally necessary to relieve the hydrocephalus.

In case 6, sequential CT scans revealed an enlarging cerebellopontine angle cyst, but hydrocephalus was not present (fig. 10). A metrizamide CT cisternogram showed no initial filling of the cyst but did show a slow diffusion of the contrast agent into the cyst at 6 hr (fig. 11). At surgery, a loculated arachnoid cyst displacing the pons and cerebellum medially was found. Histology of the wall of the cyst obtained adjacent to the foramen of Luschka revealed arachnoid cells on one surface and ependymal cells on the other.

Discussion

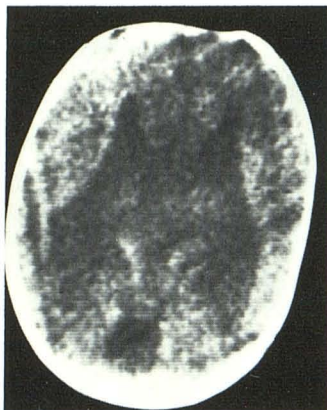
Intracranial fluid-containing cysts may be seen in either childhood or adult life, and may cause symptoms by direct compression of the brain or by producing obstructive hydrocephalus [1]. Their high incidence in childhood suggests a developmental origin; other etiologic factors include infection, trauma, and increased intracranial pressure [7–9]. Histologically, the walls of the cysts may contain neuroepithelial or ependymal cells, particularly if the cysts are confined to the hemispheres; arachnoid cells may also be found in the cyst walls [10, 11]. Of prime importance in the



A

C

E



B

D

F

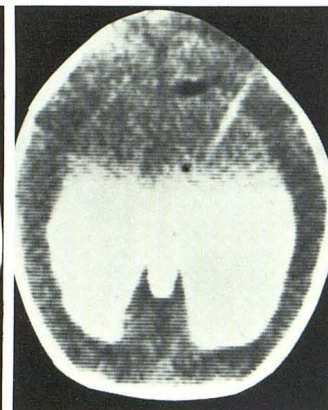
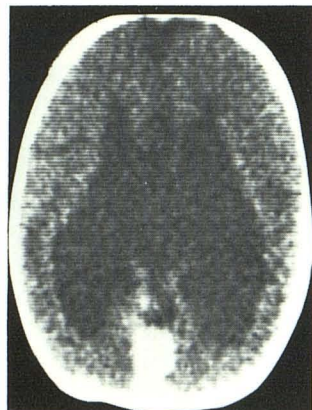
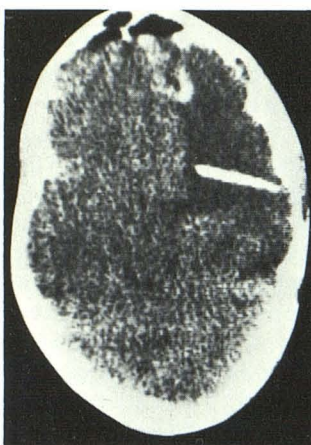
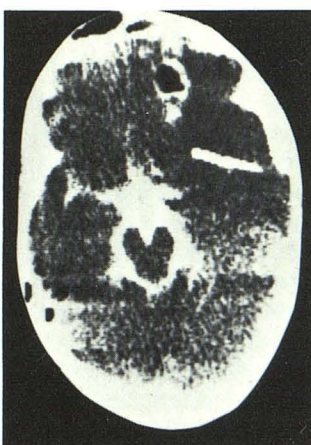

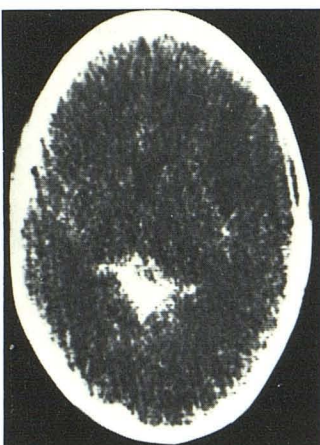
Fig. 3.—Case 2. A and B, Scans of newborn infant. Retrocerebellar cyst and agenesis of corpus callosum. C and D, After metrizamide cisternography. Contrast agent within cyst and fourth ventricle but not within third or lateral ventricles. E and F, After metrizamide ventriculography. Contrast agent enters fourth ventricle and cyst.



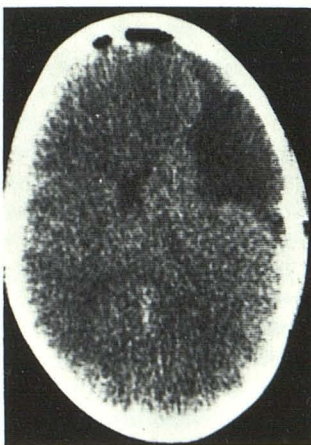
A



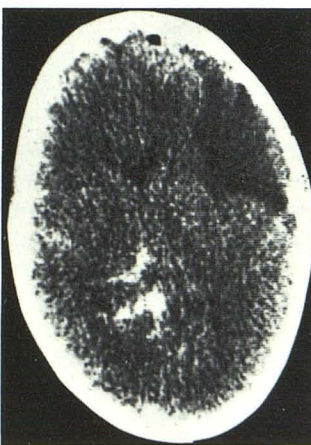
C



E



B



D

Fig. 4.—Case 3, 16-year-old boy with left middle cranial fossa cyst. A and B, Shunt in cyst. Lateral ventricles slightly displaced to right. C and D, At 1 hr after metrizamide cisternography. Even though basal cisterns are well filled with metrizamide, no metrizamide is seen within cyst. E, At 3 hr. Some metrizamide has leaked into cyst (indicated on kinetic studies).

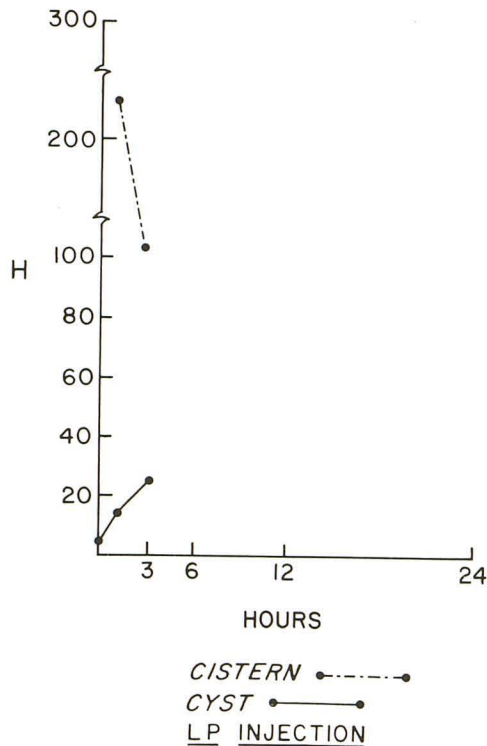


Fig. 5.—Case 3. Time-density graph. Whereas metrizamide is not initially present within cyst, there is a slow leakage into cyst at 3 hr.

management of the cyst is the identification of cyst communication with the cerebrospinal fluid pathways to determine whether shunting of the cyst or of the ventricle is the preferred therapy in cases of hydrocephalus.

In cases 1 and 2, our studies demonstrated that free communication existed between the cerebrospinal fluid pathways and the cysts. In these cases, regardless of the nature of the cysts, direct shunting of the enlarged ventricles is the preferred therapy. Because of the free communication, it is probably inappropriate to consider these as true

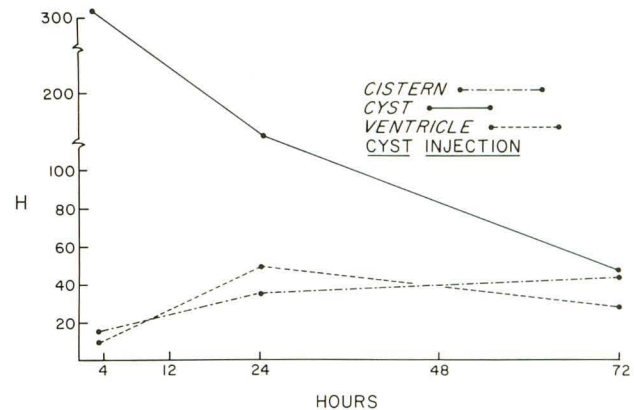


Fig. 7.—Case 4. Time-density graph. Slow diffusion of metrizamide from cyst into left lateral ventricle and basal cisterns.

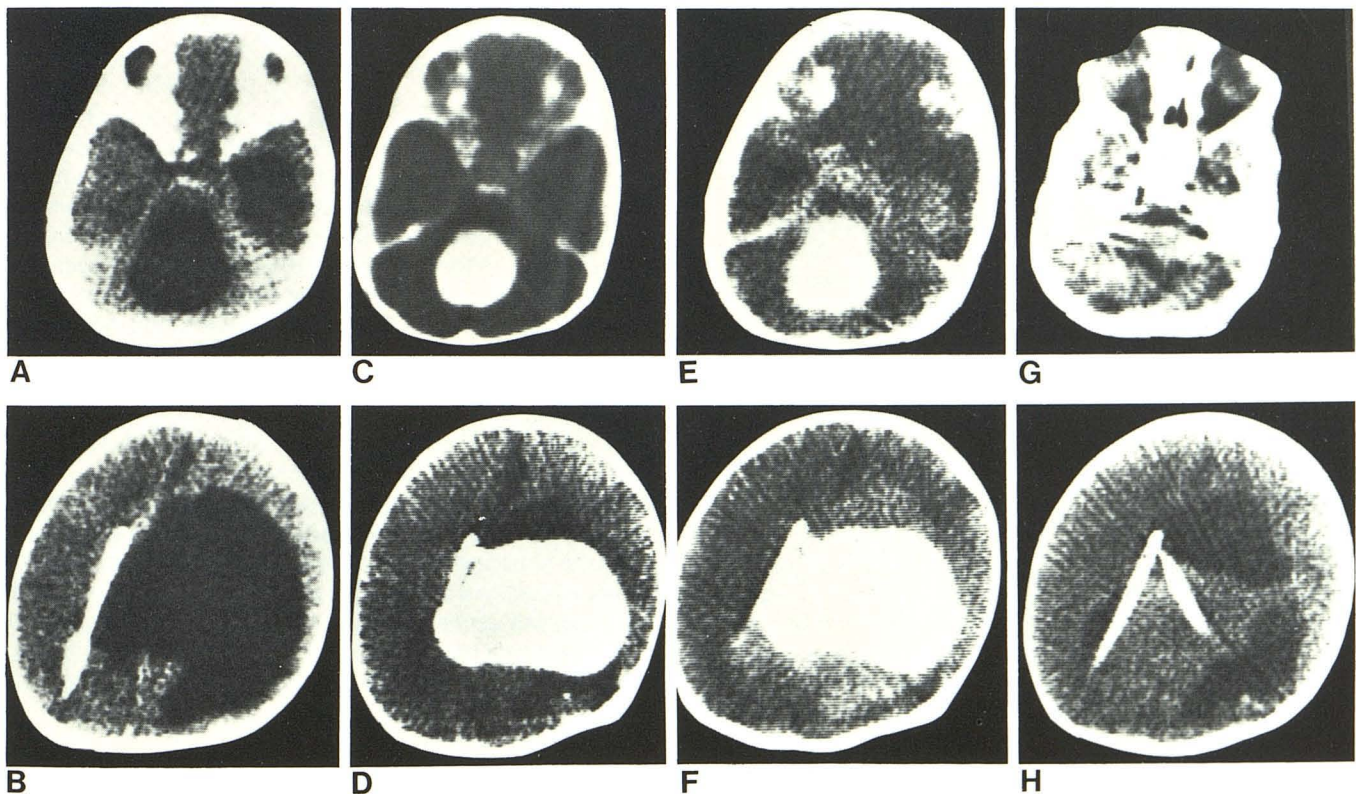


Fig. 6.—Case 4, 8-month-old infant with transsaccular cyst. A and B, Posterior fossa cyst with large supratentorial low density indistinguishable from left lateral ventricle. Enlarged temporal horn. Shunt in right lateral ventricle. C and D, Metrizamide injected directly into cyst through left-sided shunt. Cyst is separate from surrounding enlarged left lateral ventricle.

Metrizamide also freely enters posterior fossa component of cyst. At 24 (E and F) and 72 (G and H) hr later. Slow diffusion of metrizamide into basal cisterns and lateral ventricles. At 72 hr, cyst is isodense with surrounding brain.

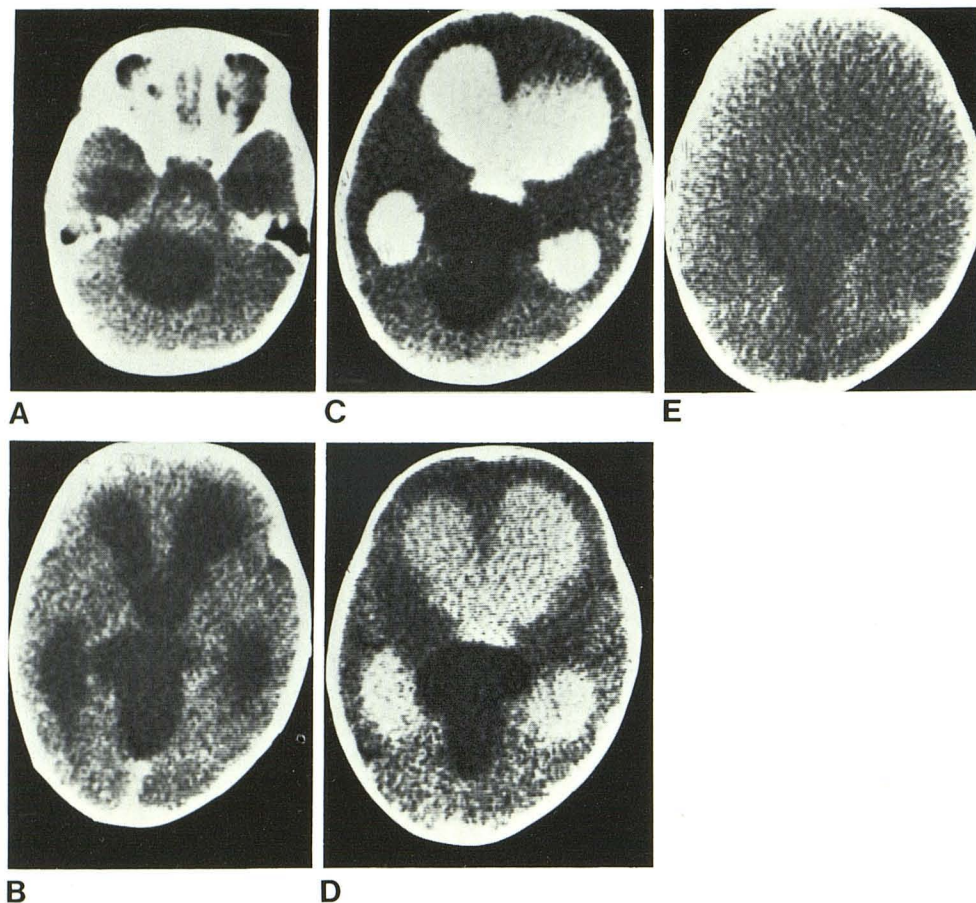


Fig. 8.—Case 5, 10-month-old child with quadrigeminal cistern cyst. **A** and **B**, Cyst extends from posterior fossa through incisura. Ventricular dilatation indicative of internal obstructive hydrocephalus. **C–E**, Metrizamide CT ventriculogram. No metrizamide within cyst at 2 hr (**C**), but at 24 (**D**) and 48 (**E**) hr, there is a slow diffusion of metrizamide into cyst.

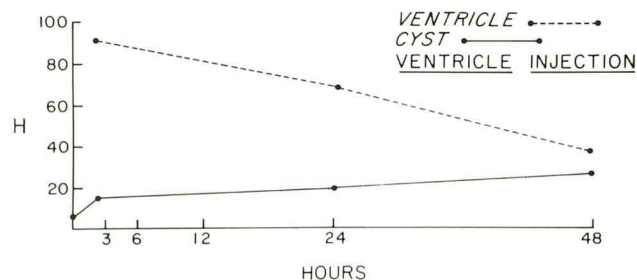


Fig. 9.—Case 5. Time-density graph. Slow diffusion of metrizamide into cyst over 48 hr.

cysts—possibly they represent no more than distention of a normal cisterna magna (usually large in infancy) in patients with communicating hydrocephalus. The slow clearance of metrizamide from the basal cisterns is suggestive of communicating hydrocephalus. In cases 3–6, the cysts did not freely communicate with the cerebrospinal fluid pathways, thus the preferred therapy is cyst shunting [12]. Possibly, these cysts initially freely communicated with the cerebrospinal fluid pathways and then, because of a superimposed hemorrhage or infection, became isolated. Another explanation is that these noncommunicating cysts are intraarachnoid in nature. Starkman et al. [8] introduced the concept that some arachnoid cysts are formed by splitting and duplication of the arachnoid membrane. Unfortunately, his-

tologic examination of the cysts in cases 3, 5, and 6 could not confirm that the cysts were intraarachnoid in location.

Handa et al. [13] also used metrizamide CT cisternography to demonstrate the anatomy and physiologic cerebrospinal fluid kinetics in intracranial cysts in four patients. In two patients, a free communication between the cysts and the cerebrospinal fluid pathways was demonstrated. In one patient a delayed communication was seen, and in the fourth patient no communication was demonstrated on scans obtained up to 24 hr after the commencement of cisternography. Leo et al. [14] used Conray ventriculography and CT in one case to demonstrate noncommunication between the ventricles and a suprasellar arachnoid cyst.

Our data suggest that there are two types of cysts: one is actually an arachnoid diverticulum that freely communicates with the subarachnoid spaces (cases 1 and 2) and one is a true cyst, with no or poor communication with the subarachnoid spaces (cases 3–6). In all four of our latter cases, delayed opacification was demonstrated, which may represent diffusion of metrizamide through the thin arachnoid membrane or an intermittent communication between the cyst and the subarachnoid space [13, 15].

It is difficult to draw firm conclusions regarding the correct surgical management of intracranial cysts from our small series. However, if symptomatic hydrocephalus is associated with an intracranial cyst that freely communicates with the ventricular system, ventricular shunting seems to be the

Fig. 10.—Case 6, 4-month-old infant with cerebellopontine angle cyst. **A**, Cyst in right cerebellopontine angle. Fourth ventricle displaced to left. **B** and **C**, After metrizamide CT cisternogram. At 1½ hr (**B**), cyst does not fill even though the basal cisterns are well filled. At 6 hr (**C**), metrizamide leaks into cyst.

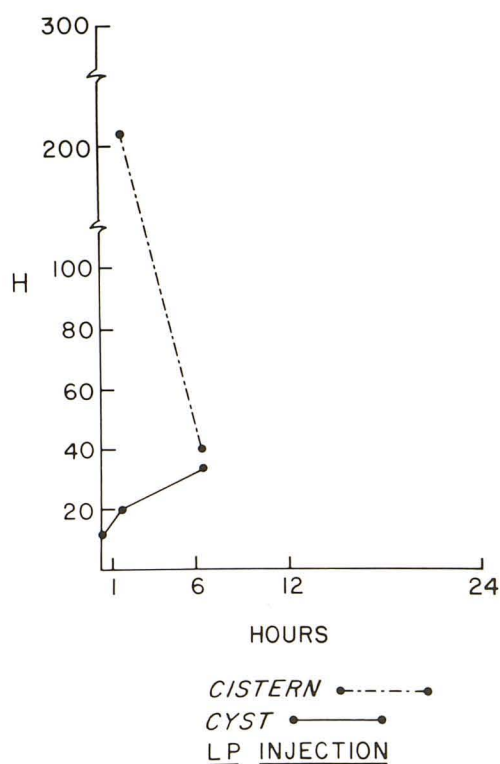
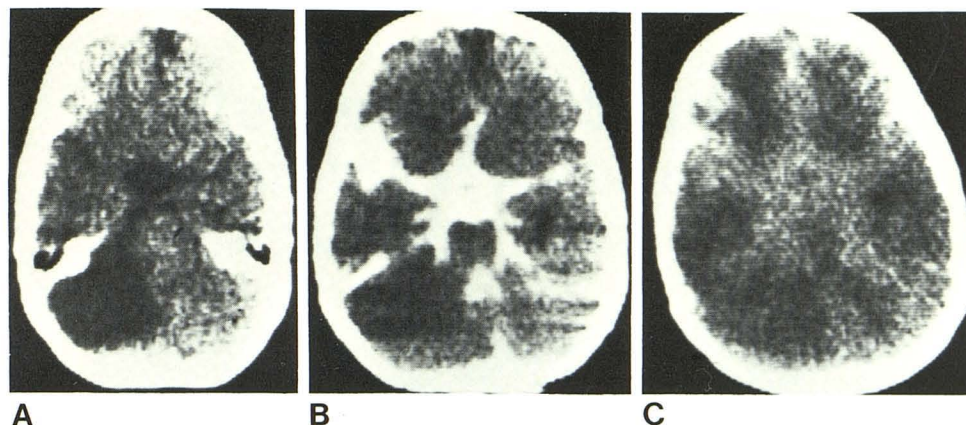


Fig. 11.—Time-density graph. Slow diffusion of metrizamide into cyst at 6 hr.

most appropriate treatment. "True" noncommunicating cysts need to be directly shunted, since cyst fenestration alone has not been effective in the management of these patients. The surgeon should be aware that secondary ventricular shunting may be necessary if the normal cerebrospinal fluid absorption pathways have been compromised by preexisting hydrocephalus.

REFERENCES

1. Lee BCP. Intracranial cysts. *Radiology* **1979**;130:664-674
2. Greitz T, Hindmarsh T. Computer assisted tomography of intracranial CSF circulation using a water-soluble contrast medium. *Acta Radiol [Diagn]* (Stockh) **1974**;15:497-507
3. Archer CR, Darwish H, Smith K. Enlarged cisternae magnae and posterior fossa cysts simulating Dandy-Walker syndrome on computed tomography. *Radiology* **1978**;127:681-686
4. Partain CL, Scatliff JH, Staab EV, Wu HP. Quantitative multiregional CSF kinetics using serial, metrizamide enhanced computed tomography. *J Comput Assist Tomogr* **1978**;2:467-470
5. Thaler HT, Rottenberg DA, Pentlow KS, Allen JC. A method of correcting for linear drift in computed tomography brain scans. *J Comput Assist Tomogr* **1979**;3:251-255
6. Wolpert SM, Haller JS, Rabe EF. The value of angiography in the Dandy-Walker syndrome and posterior fossa extra-axial cysts. *AJR* **1970**;109:261-271
7. Robinson RG. Congenital cysts of the brain: arachnoid malformations. *Prog Neurol Surg* **1971**;4:133-174
8. Starkman SP, Brown TC, Linell EA. Cerebral arachnoid cysts. *J Neuropathol Exp Neurol* **1958**;17:484-500
9. Little JR, Gomez MR, MacCarty CS. Infratentorial arachnoid cysts. *J Neurosurg* **1973**;39:380-386
10. Koto A, Houroupan DS, Shulman K. Choroidal epithelial cyst. Case report. *J Neurosurg* **1977**;47:955-960
11. Jakubiak P, Dunsmore RH, Beckett RS. Supratentorial brain cysts. *J Neurosurg* **1958**;28:129-136
12. Geissinger JD, Kohler WC, Robinson BW, Davis FM. Arachnoid cysts of the middle cranial fossa: surgical considerations. *Surg Neurol* **1978**;10:27-33
13. Handa J, Nakano Y, Aii H. CT cisternography with intracranial arachnoid cysts. *Surg Neurol* **1977**;8:451-454
14. Leo JS, Pinto RS, Hulvat GF, Epstein F, Kricheff II. Computed tomography of arachnoid cysts. *Radiology* **1979**;130:675-680
15. Drayer DP, Rosenbaum AE, Maroon JC, Bank WO, Woodford JE. Posterior fossa extraaxial cyst: diagnosis with metrizamide CT cisternography. *AJR* **1977**;128:431-436