



## Discover Generics

Cost-Effective CT & MRI Contrast Agents



WATCH VIDEO

# AJNR

### **Embolization of intracranial aneurysms with Guglielmi detachable coils augmented by microballoons.**

W P Sanders, T H Burke and B A Mehta

*AJNR Am J Neuroradiol* 1998, 19 (5) 917-920

<http://www.ajnr.org/content/19/5/917>

This information is current as  
of June 28, 2025.

# Embolization of Intracranial Aneurysms with Guglielmi Detachable Coils Augmented by Microballoons

William P. Sanders, Thomas H. Burke, and Bharat A. Mehta

**Summary:** We describe two cases in which balloons were used to aid in the occlusion of intracranial aneurysms with Guglielmi detachable coils. In both patients, initial attempts to place coils within the aneurysmal sac failed, as the loops of the coil repeatedly protruded through a wide aneurysmal neck into the parent vessel. Temporary balloons placed across the neck of these small, wide-necked aneurysms, the bridging balloon technique, effectively narrowed the necks, providing support for the formation of a proper coil basket, which was not possible without the balloon. Follow-up studies at 1 year showed good results in both patients.

Embolization of intracranial aneurysms with the Guglielmi detachable coil (GDC) system has now been well documented (1-4) (Vinuela F, "North American Experience in the Embolization of Intracranial Aneurysms with the GDC System," presented at the annual meeting of the American Society of Neuroradiology, St Louis, May-June 1992). However, wide-necked aneurysms are difficult to occlude completely owing to the propensity for loops of the coils to protrude into the lumen of the parent artery. This protrusion occurs when the neck of the aneurysm is the same or nearly the same size as the body of the sac. To aid in coil placement, we used temporary balloons to bridge the necks of two aneurysms, creating a narrow "pseudoneck," which enabled proper coil placement. Both aneurysms were successfully treated in this manner, verified at 12-month follow-up in both cases.

## Case Reports

### Case 1

A 63-year-old man with headaches had MR imaging and MR angiography, which showed a 6 × 4-mm aneurysm of the left internal carotid artery (ICA). Cerebral angiography showed this aneurysm (Fig 1A and B) as well as a tiny aneurysm of the left middle cerebral artery. Surgical clipping was suggested, but the patient refused craniotomy. Several attempts at coil placement within the aneurysmal sac failed owing to the

wide neck. An 8F Burke introduction catheter (Cordis Corp, Miami, Fla) was placed into the proximal left ICA, and a #9 latex balloon (Nycomed, Paris, France) was placed coaxially across the base of the aneurysm. Through the same introduction catheter, a two-tip Tracker catheter (Target Therapeutics, Fremont, Calif) was manipulated into the aneurysm beyond the uninflated balloon. A 5 mm × 15-cm T-10 GDC coil (Target Therapeutics) was advanced to the distal catheter tip, the balloon was partially inflated, and the coil was successfully positioned within the aneurysm. The coil remained in place after balloon deflation, and was then detached. Two additional 4 mm × 10-cm T-18 coils were delivered in the same manner without difficulty, forming a tight basket. The balloon was removed, and a left ICA control angiogram showed the coil basket to be within the aneurysmal sac, with no filling of the aneurysm, and the left ICA was widely patent (Fig 1C and D). The coil ball was noted to have a flattened appearance where it abutted the balloon during coil placement. One year later, the patient was asymptomatic, but refused follow-up angiography. Frontal and lateral radiographs 12 months after coil placement showed the coils to be unchanged from the initial embolization procedure (Fig 1E-H), with retention of the flattened surface at the junction of the aneurysm with the parent vessel.

### Case 2

One year prior to treatment, a 38-year-old woman presented to an outside hospital with subarachnoid hemorrhage from a 6- to 7-mm aneurysm of the left ICA opposite the ophthalmic artery (Fig 2A). Neurosurgeons at several academic institutions thought the aneurysm would be difficult to clip and advised against craniotomy; therefore, elective coil occlusion of the aneurysm was performed. A two-tip Tracker catheter was advanced into the aneurysm without difficulty; however, the introduced coils would not remain within the aneurysmal sac owing to a wide aneurysmal neck. The neck-to-dome ratio for this aneurysm was 1.0. A 0.85-mm NDSB silicone balloon catheter (Target Therapeutics) was delivered coaxially via the opposite femoral artery approach to the base of the aneurysm, and a 5 mm × 10-cm T-18 coil was then easily delivered into the aneurysm with the balloon inflated, forming a proper basket, and the coil was discharged without difficulty. A second coil could not be introduced because of the tight packing of the first coil. However, while we were manipulating the second coil with the balloon deflated, a small loop of the first coil exited the aneurysm and protruded into the parent vessel (Fig 2B and C). The second coil was withdrawn without difficulty. Attempts to

Received February 14, 1997; accepted after revision July 14.

From the Department of Radiology, Division of Interventional Neuroradiology, Henry Ford Hospital, 2799 W Grand Blvd, Detroit, MI 48202. Address reprint requests to Thomas H. Burke, RT.

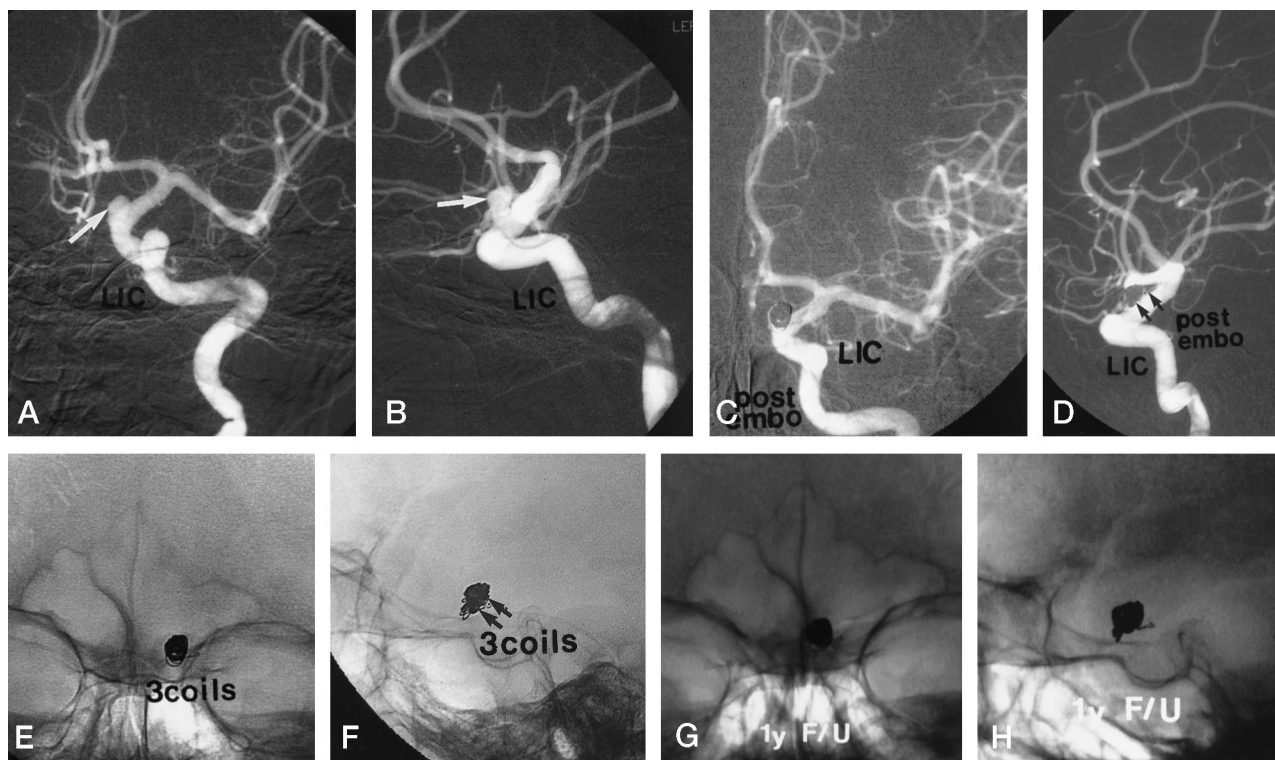


FIG 1. 63-year-old man with a 6 × 4-mm aneurysm in the left ICA.

Oblique anteroposterior (A) and lateral (B) views of pretreatment left ICA angiogram show the wide-necked paraophthalmic left ICA aneurysm (arrows).

Anteroposterior (C) and lateral (D) views of immediate control angiogram show nearly complete occlusion of the aneurysm and no abnormality of the parent artery. Note flattening of the coil nest at the site of the previously inflated balloon (arrows, D).

Anteroposterior (E) and lateral (F) skull radiographs immediately after coil embolization show the packing of coils with flattening of the coil nest inferiorly (arrows, F).

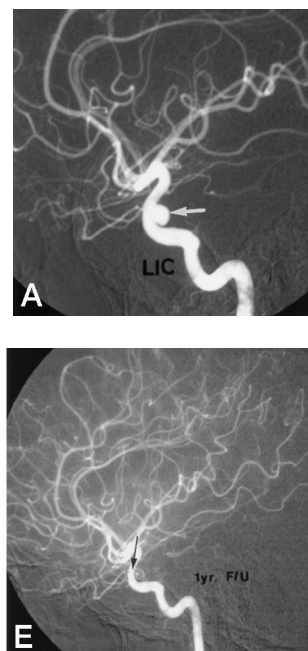
Follow-up skull films at 1 year (G and H) show no change in coil morphology.

FIG 2. 38-year-old woman with 6- to 7-mm aneurysm of the left ICA opposite the ophthalmic artery.

A, Lateral view of left ICA injection reveals wide-necked aneurysm proximal to the ophthalmic artery (arrow).

Anteroposterior (B) and lateral (C) views of left ICA injection after failed attempt at placement of a second coil. A barely visible single loop of the first coil projects into the ICA (arrow, C). There is nearly complete obliteration of the aneurysmal sac.

Anteroposterior (D) and lateral (E) views of 12-month follow-up angiography show no sign of coil compaction and no change in the coil loop within the parent artery (arrow, E).



push the loop back into the sac with the balloon failed. Temporary test occlusion of the left ICA was attempted in case of a need for permanent occlusion, but the occlusion test failed at approximately 12 minutes, when right upper and lower extremity weakness and numbness developed. The balloon was deflated, but the symptoms persisted. A repeat left ICA angiogram showed a single branch occlusion in the rolandic area. There were no other neurologic deficits. The patient was transferred to the neurosurgical intensive care unit for monitoring with continuation of systemic heparinization, which was begun at the initial catheterization of the aneurysm. Her symptoms disappeared over the next 24 to 36 hours. The 6-month follow-up study showed the aneurysm to be totally occluded with patency of the left ICA. There was no change in the packing of the aneurysm or in the loop within the parent carotid artery. A 12-month follow-up examination showed that the left ICA aneurysm was still occluded and the coil basket was unchanged from the initial embolization procedure (Fig 2D and E). The rolandic branch occlusion has recanalized and the patient's clinical status remains stable.

## Discussion

Selecting the proper coil size and shape for aneurysmal occlusion is an inexact science. The goal is to first place the coil with the largest possible diameter that will form a stable basket of coil loops, thus providing a framework to contain subsequent coils, which are often smaller in diameter. Aneurysms at both extremes of the size spectrum present particular difficulties for coil occlusion. It is also known that those aneurysms with a neck diameter similar to that of the dome pose their own difficulties. Many reported series (5–7) of GDC occlusion of aneurysms have shown that wide-necked aneurysms may not be amenable to coil occlusion owing to an inability to produce tight coil packing within the aneurysm. One group of investigators (5) found a neck measurement of 4 mm to be a threshold, stating that of aneurysms with necks 4 mm or larger, only 16% remained completely occluded, whereas 85% of aneurysms with neck diameters of less than 4 mm remained occluded. The initial coil placed within the aneurysmal sac will usually have a coil diameter nearly equal to the diameter of the sac. A neck diameter that is significantly smaller than the dome diameter prevents the coil loops from exiting the aneurysm, as the coil diameter is too wide to easily pass through the neck. Small aneurysms may have a neck that measures less than 4 mm, but the neck may be large relative to the dome. If the measured diameter of the sac is divided by the diameter of the dome of the aneurysm, a sac-to-neck ratio can be derived. It has been stated that a sac-to-neck ratio of 2.0 or more is optimal for GDC occlusion of an aneurysm (6, 7). Those aneurysms with a sac-to-neck ratio nearing 1.0 are more difficult or may be impossible to treat with the GDC system. The sac-to-neck ratio in case 1 was 1.3; in case 2, it was 1.0. These measurements suggested that successful GDC occlusion would be unlikely, and, in fact, the initial attempts were unsuccessful, as the coil loops repeatedly exited through the relatively wide aneurysmal neck. The bridging balloon technique was attempted as an alternative treatment.

Moret et al (7) first described this innovation, which they termed the remodeling technique. Other investigators have since used this procedure successfully, describing a high rate of success with minor morbidity (A. Takahashi and G. Debrun, personal communication).

The bridging balloon technique provides several practical advantages for these difficult cases. First, the inflated balloon most likely presses on the microcatheter within the aneurysm, lessening the chances that the catheter may be dislodged during coil delivery. Second, the balloon appears to mold the coil loops to fit the shape of the balloon, with little or no bulging of the coil ball into the lumen of the parent artery. This result appears to be long-lasting, as this shape persisted for at least 12 months in our two patients. This finding has also been described by others (A. Takahashi, J. Moret, and G. Debrun, personal communication). Third, and most important, the bridging balloon prevents the coil loops from exiting the aneurysmal neck during delivery of the coils. In addition, reinflating the balloon for subsequent coil placement may aid in the tight packing of the aneurysm. A theoretical risk follows in that the packing may be so tight as to rupture the aneurysm. However, this is unlikely if the technique is carried out carefully and gently.

While effective, placement of a temporary balloon in the intracranial circulation carries its own inherent risks, primarily those of vessel trauma, spasm, and emboli, and should not be tried unless more conventional techniques have proved ineffective. Levy and Ku (8) reported two patients in whom embolic complications developed. The second patient in our series had an embolic complication, although this was almost certainly a result of the temporary carotid test occlusion, not of the bridging balloon, as the symptoms occurred during the test occlusion despite systemic heparinization. Subsequent to our treatment of these two patients, “2-Dimensional” coils (Target Therapeutics) were developed in an attempt to solve the problem of treating these wide-necked aneurysms, and further product refinements are likely to aid treatment of difficult aneurysms in the future. For example, the use of stents with coils has been described in animals but has not been refined to a degree suitable for human use (9–11).

There is no statistical data regarding long-term follow-up in patients treated with the bridging balloon technique. The findings in our two patients suggest that follow-up angiography should be scheduled at intervals similar to those for patients treated without the aid of balloons.

## Conclusion

The temporary placement of a balloon across the base of a wide-necked aneurysm is an effective technique for treating these difficult aneurysms with detachable coils. Findings at 1-year follow-up in our two patients showed persistent occlusion of the aneurysms with no evidence of coil migration.



## References

1. Guglielmi G, Vinuela F, Sepetka I, Macellari V. **Electrothrombosis of saccular aneurysms via endovascular approach, 1: electrochemical basis, technique and experimental results.** *J Neurosurg* 1991;75:1-7
2. Guglielmi G, Vinuela F, Dion J, Duckwiler G. **Electrothrombosis of saccular aneurysms via endovascular approach, 2: preliminary clinical experience.** *J Neurosurg* 1991;75:8-14
3. Guglielmi G, Vinuela F, Duckwiler G, et al. **Endovascular treatment of posterior circulation aneurysms by electrothrombosis using electrically detachable coils.** *J Neurosurg* 1992;77:515-524
4. Nichols DA, Meyer FB, Piepgras DG, Smith PL. **Endovascular treatment of intracranial aneurysms: subject review.** *Mayo Clin Proc* 1994;69:272-285
5. Zubillaga A, Guglielmi G, Vinuela F, Duckwiler G. **Endovascular occlusion of intracranial aneurysms with electrically detachable coils: correlation of aneurysm neck size and treatment results.** *AJNR Am J Neuroradiol* 1994;15:815-820
6. Richling B, Bavinzski G, Gross C, Gruber A, Killer M. **Early clinical outcome of patients with ruptured cerebral aneurysms treated by endovascular (G.D.C.) or microsurgical techniques: a single center experience.** *Intervent Neuroradiol* 1995;1:19-27
7. Moret J, Pierot L, Boulin A, Castaings L. **"Remodeling" of the arterial wall of the parent vessel in the endovascular treatment of intracranial aneurysms.** *Neuroradiology* 1994;36 (Suppl 1):583
8. Levy D, Ku A. **Balloon assisted coil placement in wide necked aneurysms.** *J Neurosurg* 1997;86:724-727
9. Turjman F, Massoud T, Ji C, Guglielmi G, Vinuela F, Robert J. **Combined stent implantation and endosaccular coil placement for treatment of experimental wide-necked aneurysms: a feasibility study in swine.** *AJNR Am J Neuroradiol* 1994;15:1087-1090
10. Szikora I, Guterman L, Wells K, Hopkins LN. **Combined use of stents and coils to treat experimental wide-necked carotid aneurysms: preliminary results.** *AJNR Am J Neuroradiol* 1994;15:1091-1102
11. Geremia G, Maklin M, Brennecke L. **Embolization of experimentally created aneurysms with intravascular stent devices.** *AJNR Am J Neuroradiol* 1994;15:1223-1231