



Discover Generics

Cost-Effective CT & MRI Contrast Agents



WATCH VIDEO

AJNR

Malignant lymphoma of the gingiva: MR evaluation.

M Yasumoto, H Shibuya, H Fukuda, M Takeda, T Mukai and T Korenaga

AJNR Am J Neuroradiol 1998, 19 (4) 723-727

<http://www.ajnr.org/content/19/4/723>

This information is current as
of June 21, 2025.

Malignant Lymphoma of the Gingiva: MR Evaluation

Mayumi Yasumoto, Hitoshi Shibuya, Hozumi Fukuda, Masamune Takeda, Takayuki Mukai, and Tateo Korenaga

PURPOSE: Our purpose was to document the MR imaging findings of malignant lymphoma of the gingiva.

METHODS: Five patients with histologically proved malignant lymphoma of the gingiva were studied by MR imaging. The MR images were analyzed for tumor size, extent, and signal characteristics, bone involvement, and associated cervical lymph node enlargement.

RESULTS: Clinical examination tended to underestimate the size of lymphomatous lesions. The signal intensity of the lesions was isointense to hyperintense relative to muscle on noncontrast T1-weighted images and showed variable contrast enhancement patterns. On T2-weighted images, signal intensity was isointense to hypointense relative to the oral mucosa. In one case, the mass extended to the submandibular space; in the remaining cases, the masses were limited to the gingiva and the adjacent bone. MR imaging revealed that gingival lymphomatous masses were broad-based along the mandible or maxilla and eroded through the cortex into the marrow space, but the cortex was still recognizable. No nodal involvement was noted in any of the patients with malignant lymphoma.

CONCLUSION: The signal characteristics of gingival lymphoma overlap those of other tumors. The cortex separating marrow involvement from the broad-based gingival mass generally appears to be permeated with small erosions but is still recognizable.

Malignant lymphoma of the gingiva is rare as compared with the overall prevalence of gingival squamous cell carcinoma (1). Non-Hodgkin lymphoma commonly involves the oropharyngeal lymphoid tissue comprising Waldeyer's ring, but only occasionally involves other oral tissues. Once the final diagnosis of malignant lymphoma is made by findings at oral biopsy, radiation and chemotherapy are the primary means of treatment. For proper treatment planning, it is important to assess the extent of the tumor radiologically (2). Although cases of gingival malignant lymphoma have been reported, they have included no imaging findings other than those on panoramic radiographs (3–7). During the past 4 years, we encountered five patients with histologically proved malignant lymphoma of the gingiva who had MR studies as part of the clinical staging. Those MR findings are reported here.

Methods

The MR images of five patients with histologically verified malignant lymphoma of the gingiva were reviewed retrospectively by two radiologists working in concert. The patients were all men with a mean age of 64 years and had no known HIV infection (see Table). Clinical staging in each case was completed according to the Ann Arbor system of staging Hodgkin lymphoma. Three of the five patients had only gingival involvement (stage I_E), one patient had a relapse of lymph node involvement elsewhere (stage III) that had been diagnosed 5 years previously, and the final patient had synchronous involvement of the lung parenchyma (stage IV).

MR imaging was performed on a 1.5-T unit using a neck coil. T1-weighted images were obtained in the axial and coronal planes using parameters of 500–700/10–20 (TR/TE). Single-echo T2-weighted fast spin-echo images (4500–5200/90–103) were obtained in either the axial or the coronal plane. In all patients, gadopentetate dimeglumine was administered at a dose of 0.1 mmol/kg. T1-weighted images (with parameters identical to those described above) were obtained immediately after administration of the contrast material in the axial and coronal planes. All MR images had a 256 × 192 matrix and 4- or 5-mm-thick sections with a 0.4- or 0.5-mm intersection gap; both superior and inferior presaturation pulses were applied for the axial scanning.

MR images were evaluated for size, signal characteristics, and extent of tumor, bone involvement, and associated lymph node enlargement. Osseous involvement was evaluated for destruction of cortical bone contiguous with the gingival mass and adjacent bone marrow replacement.

Panoramic radiographs were also available in three patients and CT scans in two patients.

Received April 22, 1997; accepted after revision July 28.

From the Departments of Radiology (M.Y., H.S., H.F.) and Dental Radiology (M.T.), Tokyo Medical and Dental University; and the Department of Radiology, Tokyo Teishin Hospital (T.M., T.K.).

Address reprint requests to Mayumi Yasumoto, MD, Department of Radiology, Tokyo Medical and Dental University, 1-5-45 Yushima, Bunkyo-ku, Tokyo, Japan 113.

Clinical information and tumor size in five patients with malignant lymphoma of the gingiva

Patient	Age, y/Sex	Pathologic Findings	Tumor Appearance	Ulceration	Size at Clinical Examination, mm	Size on MR Images, mm	Primary or Secondary Tumor	Stage
1	52/M	Mandibular gingiva, NHL (diffuse large cell)	Nodular	—	15	30	S	III*
2	65/M	NHL (diffuse large cell)	Exophytic	—	40	50	P	I _E
3	65/M	NHL (diffuse large cell)	Nodular	+	30	50	P	IV
4	60/M	Hodgkin disease (mixed cellularity)	Nodular	—	30	50	P	I _E
5	76/M	Maxillary gingiva, Hodgkin disease (mixed cellularity)	Plaquelike	+	30	30	P	I _E

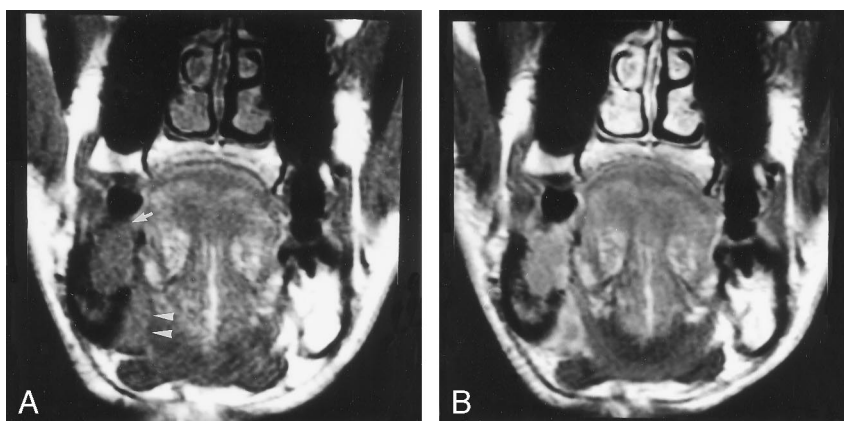
Note.—NHL = non-Hodgkin lymphoma; P = primary; S = secondary.

* The initial stage, with primary lesions of the lymph nodes, 5 years before relapse in the mandible.

FIG 1. Patient 1: 52-year-old man with a mandibular gingival mass (biopsy proved non-Hodgkin lymphoma).

A, Coronal T1-weighted MR image (600/15) shows a nodular mass (*arrow*) above the body of the right mandible that extends to the bone marrow and to the anterior submandibular space (*arrow-heads*), but the lingual cortex is only partly destroyed.

B, Contrast-enhanced coronal T1-weighted MR image shows general contrast enhancement of the gingival mass and the adjacent bone marrow. The involved submandibular area shows somewhat heterogeneous enhancement.



Results

Clinical information, MR imaging findings, and results of pathologic evaluation are summarized in the Table.

Size, Signal Characteristics, and Extent of Tumor

The clinical examination tended to underestimate the size of malignant lymphomatous lesions. On T1-weighted images, the lesions had homogeneous signal intensity that was isointense or slightly hyperintense relative to that of the buccinator muscles (Figs 1–4). On T2-weighted sequences, the tumors were always isointense or slightly hypointense relative to the oral mucosa (Fig 3). Therefore, the lesions were more conspicuous and better delineated on the T1-weighted images. Although tumor enhancement was always observed on the contrast-enhanced T1-weighted images, the degree of contrast enhancement was variable. In one of the five cases, the tumor extended to the anterior submandibular space without involving the submandibular gland (Fig 1). In the remaining four cases, the tumor was localized in the gingiva and the contiguous bone (Figs 2–4).

Osseous Involvement

The tumors generally eroded through the adjacent cortex into the marrow space, but the cortex remained visible with relatively small areas of complete

erosion and larger areas in which the cortex was thinned or permeated but still recognizable. In all five patients, only one of the two cortical surfaces (buccal or lingual) was involved. The involvement of the marrow space tended to match the size of the soft-tissue lesion, and the normal high signal of bone marrow was replaced by a low signal (Figs 1–4). No cortical destruction or lytic area was detected on the panoramic radiographs in two of the three patients in whom these films were obtained. The third patient had thinning of the alveolar bone with a small lytic area (Fig 3). Bone window of CT scans showed focal cortical breakdown. The margins of adjacent gingival tumors were indistinct (Figs 2 and 3).

Regional Lymph Node Enlargement

The short axis of the regional nodes was always less than 10 mm; no biopsy was performed.

Discussion

Unlike malignant lymphoma of Waldeyer's ring, malignant lymphoma of the oral cavity is rare and almost exclusively non-Hodgkin lymphoma. The rate of occurrence has been estimated to be approximately 9.5% of all extranodal non-Hodgkin lymphomas of the head and neck (8, 9). One review reported 128 cases of extranodal non-Hodgkin lymphoma of the head and neck; 83 cases involved Waldeyer's ring, 11 cases the gingiva (9). The rel-

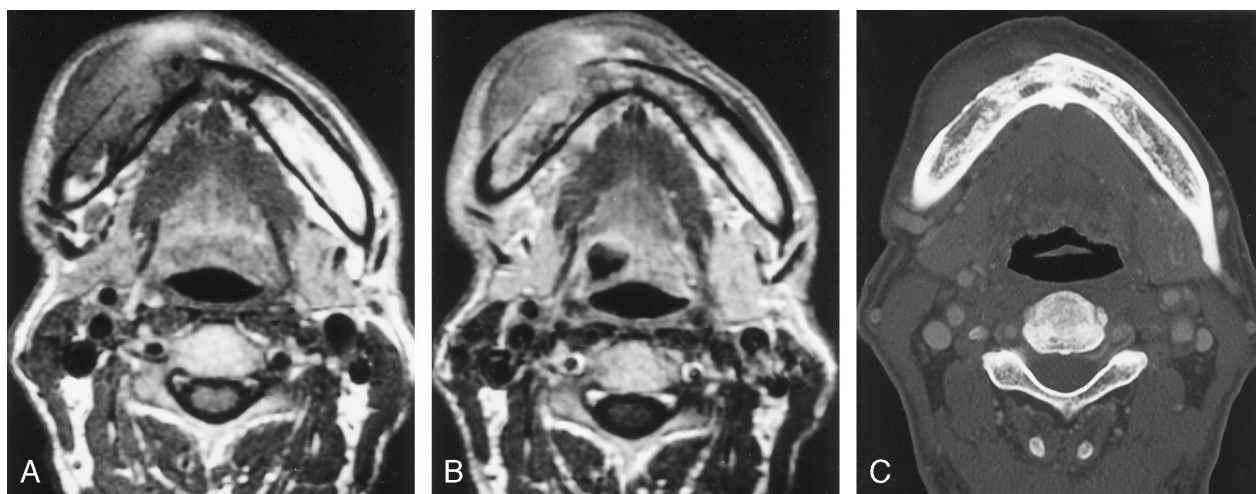


FIG 2. Patient 2: 65-year-old man with a mandibular gingival mass. The overlying mucosa was smooth (biopsy proved non-Hodgkin lymphoma).

A, Axial T1-weighted MR image (660/15) through the mandibular body shows a broad-based soft-tissue mass along the outer surface of the mandible. The bone was generally thinned with perforations or demineralization, but some of the structure of the cortex remained visible. The signal of the adjacent bone marrow is extensively replaced.

B, Contrast-enhanced axial T1-weighted MR image shows generalized contrast enhancement of the mass and the affected bone marrow.

C, Bone window of the CT scan reveals cortical thinning and breakdown at the right body of the mandible.

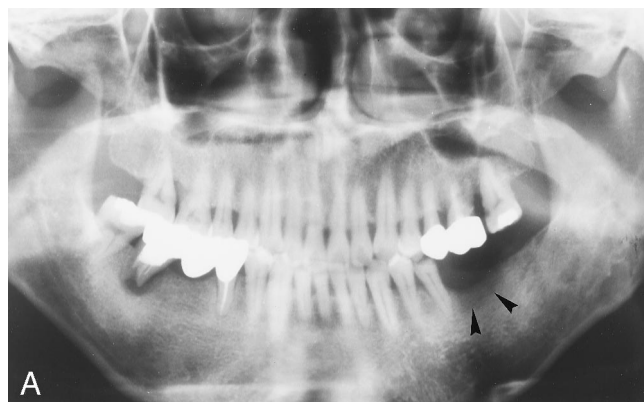


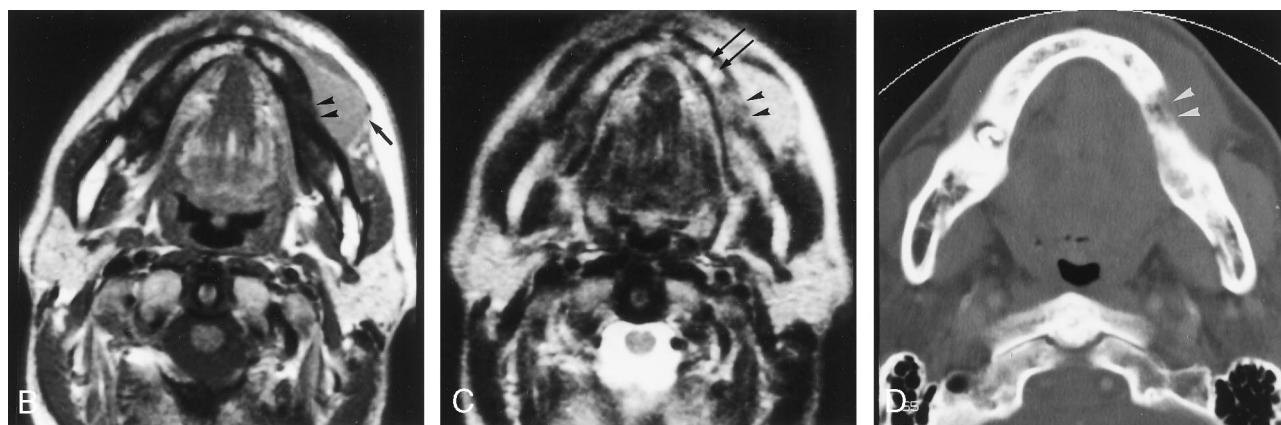FIG 3. Patient 4: 60-year-old man with a nodular mandibular gingival mass (biopsy proved Hodgkin disease).

A, Thinning of alveolar bone with a small lytic area (arrowheads) is noted on panoramic radiograph.

B, Axial T1-weighted MR image (670/15) shows a broad-based mass (arrow) that is slightly hyperintense relative to the buccinator muscle. A small cortical defect (arrowheads) is seen at the outer surface of the mandibular body.

C, Axial T2-weighted MR image (4600/90) shows a mass that is isointense with the oral mucosa. Anterior to the cortical defect (arrowheads), small cystic changes (arrows) are seen within the bone marrow.

D, Bone window of the CT scan shows a small cortical defect (arrowheads) on the buccal side of the mandible and a thinning of the lingual cortex.



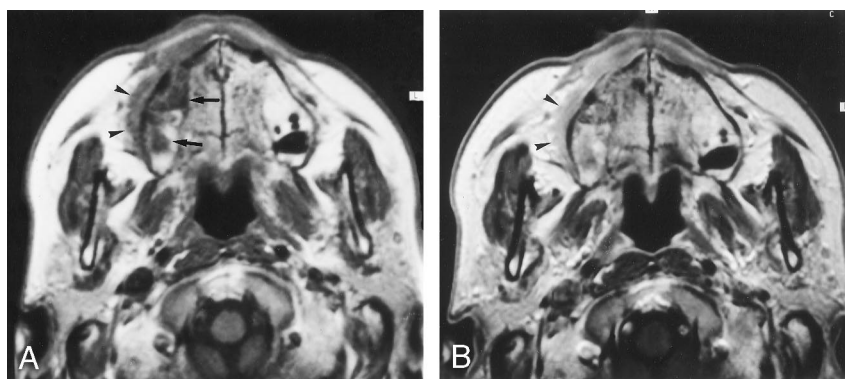
actively favored intraoral sites other than Waldeyer's ring are the palatal mucosa and bone, especially the mandible and maxilla (10). Malignant lymphomas occur more frequently in the mandible as bone tumors, with a predominance in males; radiographically, they are often accompanied by poorly defined, variably sized areas of lysis within the mandible (2). This is partially accounted for by

the fact that lymphomatous tissue is normally found in the bone marrow but not in the gingiva (3). Only isolated cases of gingival lymphoma have been reported (3-7). Some malignant lymphomas of the mandibular gingiva may arise from facial (mandibular) nodes, since they lie along the external surface of the mandible (11). Hodgkin lymphoma of the oral cavity is far less common (7).

FIG 4. Patient 5: 76-year-old man with an ulcerated swelling of the right maxillary gingiva (biopsy proved Hodgkin disease).

A, Axial T1-weighted MR image (610/14) through the maxilla shows a broad-based low-signal mass (arrowheads) along the alveolar process of the maxilla. The buccal cortex is eroded but still recognizable. The marrow space is also involved (arrows).

B, Contrast-enhanced axial T1-weighted MR image shows general contrast enhancement of the mass (arrowheads).



To our knowledge, no previous reports have emphasized the radiologic features of gingival malignant lymphoma nor has this entity been imaged, other than by either periapical and/or panoramic radiography. Previously, evaluation of tumor size was based solely on visual and tactile examinations. The clinical appearance of gingival malignant lymphoma varies: it may be nodular and plaque-like, ulcerating or papillary and exophytic (1, 3–7), and it may be confused with benign inflammatory or reactive lesions that are common in these areas (1). Although tissue diagnosis can only be made by biopsy, MR imaging has been shown to be effective in certain circumstances (12–15).

Gould and Alpert (4) reported a case of primary non-Hodgkin lymphoma (mixed cellular diffuse type) of maxillary gingiva with no apparent osseous abnormality. The 25-mm mass was removed, and the underlying bone cortex was observed to be intact at surgery. Other cases have also shown either no localized bone destruction or minimal localized alveolar bone loss with a mass size ranging from one tooth width to 60 mm (3, 5–7). These findings are in accordance with our results. Panorex films are useful for evaluating gross invasion by adjacent tumors, but subtle changes are often obscured. Moreover, the loss of permanent teeth is always followed by absorption of the corresponding parts of the alveolar processes (16). Without tumor localization, bone change cannot be well delineated by panoramic radiographs. MR imaging can show gingival masses and their bone marrow involvement more clearly.

In our limited study population, a broad-based gingival mass generally eroded through the cortex into the marrow space, although the cortex was still recognizable. In squamous cell carcinoma of the oral cavity, proximity to the bone rather than tumor size is the most important factor determining mandibular involvement by tumors (17). Therefore, even small gingival squamous cell carcinomas often destroy the adjacent bone aggressively, and destruction of both buccal and lingual cortical surfaces is frequent. Unlike gingival squamous cell carcinoma, gingival malignant lymphoma tends to erode through the underlying cortex into the marrow without entirely destroying the cortex. According to the report by Amano et al (18), the mandibular marrow changes seen on MR images may reflect increased cellularity in the mar-

row, be it lymphoma or other types of cells. However, regarding the bone marrow of the mandible, it would be prudent to be alert to false-positive diagnoses. Various causes of bone marrow changes, such as tooth extraction, inflammatory odontogenic disease, postradiation fibrosis, osteoradionecrosis, and/or partial volume effects, have been reported (19).

Unless a gingival malignant lymphoma is an extranodal manifestation of widely disseminated disease, generalized or regional lymph node involvement appears to be less common (3–6). In our series, one patient was determined to have stage IV disease on the basis of involvement of the lung parenchyma, although no cervical nodes were involved at the time of staging.

Recently, the association between non-Hodgkin lymphoma and HIV infection has been established (20), and more cases of oral lymphoma as the initial manifestation are being reported (3, 6, 7). In addition, Harnsberger et al (21) reported a higher rate of occurrence of synchronous extranodal, extralymphatic sites of non-Hodgkin lymphoma in the head and neck. MR examination as part of staging of malignant lymphoma in the head and neck may depict these synchronous tumors of unusual intraoral sites better than CT does.

Conclusion

The MR signal characteristics of gingival lymphoma overlap those of other tumors of the head and neck. The cortex separating marrow involvement from the broad-based gingival mass generally appears to be permeated with small erosion but is still recognizable.

References

1. Batsakis JG. *Tumors of the Head and Neck*. 2nd ed. Baltimore: Williams & Wilkins; 1979:157–158.
2. Som PM, Curtin HD. *Head and Neck Imaging*. 3rd ed. St Louis: Mosby-Year Book; 1996:320–347.
3. Wilson TG, Wright JM. Non-Hodgkin's lymphoma of the gingiva: review of the literature and report of a case. *J Periodontol* 1986;57: 155–158.
4. Gould AR, Alpert B. Painless swelling of the anterior maxillary gingiva. *J Oral Maxillofac Surg* 1987;45:785–788.
5. Brahim JS, Katz RW, Roberts MW. Non-Hodgkin's lymphoma of the hard palate mucosa and buccal gingiva associated with AIDS.

- J Oral Maxillofac Surg* 1988;46:328-330
6. Rubin MM, Gatta CA, Cozzi GM. **Non-Hodgkin's lymphoma of the buccal gingiva as the initial manifestation of AIDS.** *J Oral Maxillofac Surg* 1989;47:1311-1313
 7. Laskaris G, Stergiou G, Kittas C, Scully C. **Hodgkin's disease involving the gingiva in AIDS.** *Oral Oncol Eur J Cancer* 1992;28B:39-41
 8. Freeman C, Berg JW, Cutler SJ. **Occurrence and prognosis of extranodal lymphomas.** *Cancer* 1972;29:252-260
 9. Wong DS, Fuller LM, Butler JJ, Shullenberg CC. **Extranodal non-Hodgkin's lymphomas of the head and neck.** *AJR Am J Roentgenol* 1975;123:471-481
 10. Eisenbud L, Sciubba J, Mir R, Sachs JA. **Oral presentation in non-Hodgkin's lymphoma: a review of thirty-one cases, I: data analysis.** *Oral Surg Oral Med Oral Pathol* 1983;56:151-156
 11. Tart RP, Mukherji SK, Avino AJ, Stringer SP, Mancuso AA. **Facial lymph nodes: normal and abnormal CT appearance.** *Radiology* 1993;188:695-700
 12. Lufkin RB, Wortham DG, Dietrich RB, et al. **Tongue and oropharynx: findings on MR imaging.** *Radiology* 1986;161:69-75
 13. Kassel EE, Keller MN, Kucharczyk W. **MRI of the floor of the mouth, tongue and oropharynx.** *Radiol Clin North Am* 1989;27:331-351
 14. Hudgins PA, Gussack GS. **MR imaging in the management of extracranial malignant tumors of the head and neck.** *AJR Am J Roentgenol* 1992;159:161-169
 15. Yasumoto M, Shibuya S, Takeda M, Korenaga T. **Squamous cell carcinoma of the oral cavity: MR findings and value of T1- versus T2-weighted fast spin-echo images.** *AJR Am J Roentgenol* 1995;64:981-987
 16. Smith JW, Murphy TR, Blair JSG, Lowe KG. *Regional Anatomy Illustrated.* Edinburgh, Md: Churchill Livingstone; 1983:440
 17. Marchetta FC, Sake K, Ballido J. **Periosteal lymphatics of the mandible and intraoral carcinoma.** *Am J Surg* 1964;122:711-713
 18. Amano Y, Wakabayashi H, Kumazaki T. **MR signal change in bone marrow of mandible in hematologic disorders.** *J Comput Assist Tomogr* 1995;19:552-554
 19. Chung TS, Yousem DM, Seigerman BN, Schlakman GS, Weinstein GS, Hayden RE. **MR of mandibular invasion in patients with oral and oropharyngeal malignant neoplasms.** *AJNR Am J Neuroradiol* 1994;5:1949-1955
 20. Biggar RT, Burnett W, Mikl J, Nasca P. **Cancer among New York men at risk of acquired immunodeficiency syndrome.** *Int J Cancer* 1989;43:979-985
 21. Harnsberger HR, Bragg DG, Osborn AG, et al. **Non-Hodgkin's lymphoma of the head and neck: CT evaluation of nodal and extranodal sites.** *AJR Am J Roentgenol* 1987;149:785-791