



Discover Generics

Cost-Effective CT & MRI Contrast Agents



WATCH VIDEO

AJNR

MR imaging technique for the diagnosis of pituitary iron overload in patients with transfusion-dependent beta-thalassemia major.

G Sparacia, A Banco, M Midiri and A Iaia

This information is current as of June 21, 2025.

AJNR Am J Neuroradiol 1998, 19 (10) 1905-1907
<http://www.ajnr.org/content/19/10/1905>

MR Imaging Technique for the Diagnosis of Pituitary Iron Overload in Patients with Transfusion-Dependent β -Thalassemia Major

Gianvincenzo Sparacia, Aurelia Banco, Massimo Midiri, and Alberto Iaia

Summary: To identify the optimal MR imaging technique for diagnosing pituitary iron overload, we compared spin-echo and gradient-echo MR imaging with measurements of pituitary T2 relaxation times in 30 patients with secondary hemochromatosis due to transfusion-dependent β -thalassemia major and in 10 healthy volunteers. We found that the optimal MR imaging technique to evaluate pituitary iron overload is the gradient-echo T2*-weighted technique, as it best demonstrated signal reduction in the anterior lobe of the pituitary gland.

MR imaging has long been considered a potential method for determining tissue iron overload in such conditions as primary or secondary hemochromatosis. The latter may be seen in patients with transfusion-dependent β -thalassemia major, in whom repeated transfusions lead to iron accumulation in the liver (1–5), pituitary gland (6, 7), and other organs (8) in the form of ferritin or hemosiderin. Initial results with MR imaging have shown that iron overload causes a reduction in signal intensity stemming from a decrease in T2 relaxation time (1). The aim of this study was to identify the optimal MR imaging technique for diagnosing pituitary iron overload, comparing spin-echo (SE) and gradient-echo (GRE) imaging with measurements of pituitary T2 relaxation times.

Methods

Subjects

Thirty patients (12 males and 18 females; ages 16 to 39 years; median age, 21 years) with transfusion-dependent β -thalassemia major underwent MR examination of the pituitary gland. All patients were being treated with a transfusion regimen that maintained the pretransfusion hemoglobin level between 9.5 and 10.5 g/dL. They received iron chelation therapy with deferoxamine (Desferal, Ciba-Geigy, Basel, Switzerland). All patients had increased serum ferritin levels (mean value, 3326 ng/mL vs normal value of <300 ng/mL), a parameter that reflects the severity of iron overload. Ten healthy volunteers were imaged as a control group.

MR Imaging

MR studies were performed with a 0.5-T superconducting MR system. All examinations included an SE T1-weighted sequence with parameters of 400/20 (TR/TE), a multiecho SE sequence (1000/20,40,60,80), and a GRE T2*-weighted sequence (650/30 with a flip angle of 20°). Coronal and sagittal 4-mm-thick sections through the pituitary gland with an inter-section gap of 1 mm were obtained. Two-to-four excitations were used. The image matrix was 192 × 256. The field of view was 24 cm.

Quantitative Image Analysis

Signal intensities of the anterior lobe of the pituitary gland, pterygoid muscles, and nasopharyngeal fat were measured with the use of operator-defined regions of interest (ROIs) of 3 mm² on both SE T1-weighted and GRE T2*-weighted coronal images. The signal intensity of the anterior lobe of the pituitary gland was averaged from three different ROIs. The ratio of the average pituitary gland signal intensity to that of the pterygoid muscles and that of nasopharyngeal fat was assessed, both on T1- and T2*-weighted images. In addition, pituitary T2 relaxation times were obtained using the vendor-supplied T2 calculation program involving a monoexponential fitting of ROI intensity data plotted against TE on the multiecho SE sequence (Fig 1). The T2 values obtained were averaged. Data acquired from the control group were used as reference.

Statistical Analysis

Data are presented as means \pm SD. The significance in differences in mean values between patients and control subjects was assessed using Student's *t*-test. A *P* value of less than .05 was considered significant.

Discussion

We found that at 0.5 T, the anterior lobe of the pituitary gland showed a significant decrease in signal intensity as compared with that of the control subjects on GRE T2*-weighted images (Fig 2).

The best predictor of pituitary iron overload was the pituitary-to-fat ratio rather than the pituitary-to-muscle signal intensity ratio (see Table). This may be because fat behaves as inert tissue in relation to iron

Received March 4, 1998; accepted after revision June 22.

Presented in part at the annual meeting of the American Society of Neuroradiology, Toronto, Canada, May 1997.

From the Institute of Radiology "P. Cignolini," University of Palermo, Italy (G.S., A.B., M.M.); and the Department of Radiology, Brigham and Women's Hospital, Harvard Medical School, Boston, MA (A.I.).

Address reprint requests to Gianvincenzo Sparacia, MD, Viale Strasburgo 167, 90146 Palermo, Italy.

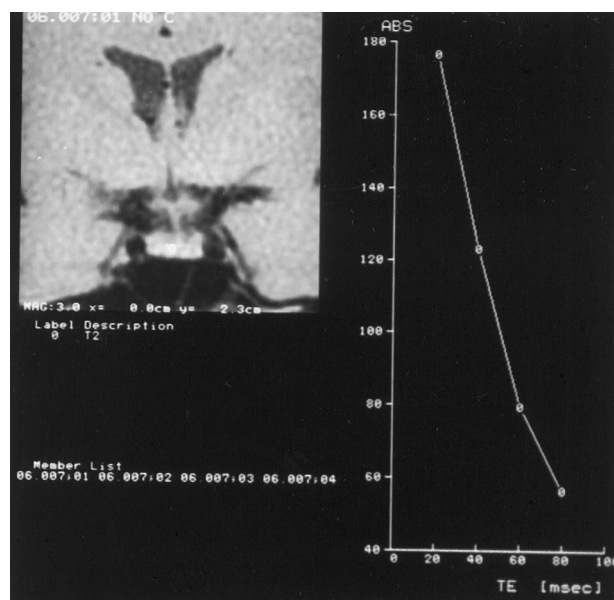
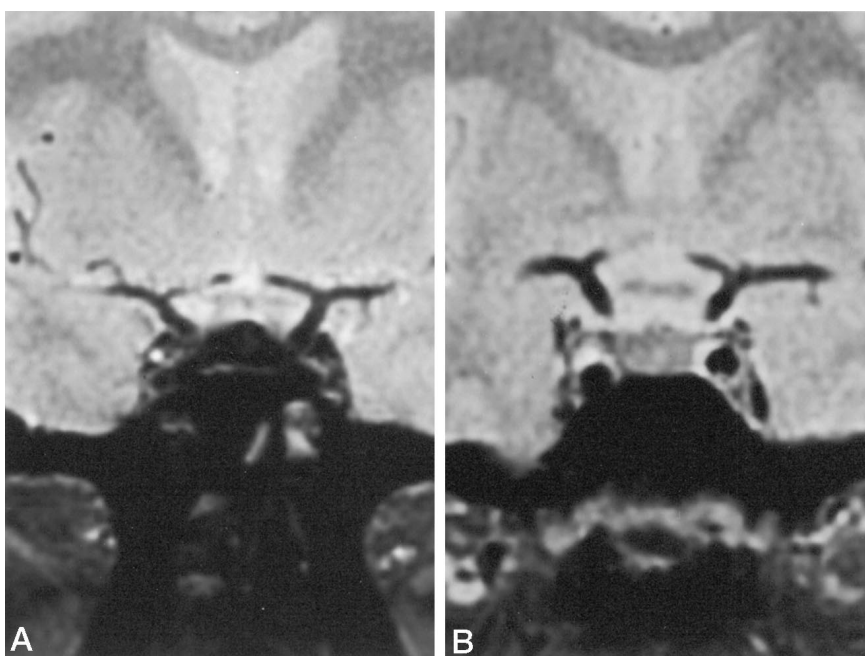


FIG 1. Pituitary T2 relaxation times were obtained using the vendor-supplied T2 calculation program involving a monoexponential fitting of ROI intensity data plotted against TE on a multiecho SE sequence (1000/20,40,60,80/2).

FIG 2. A and B, Coronal T2*-weighted GRE images (650/30/4; flip angle, 20°) of the pituitary gland in a 28-year-old man with transfusion-dependent β -thalassemia major (A) and in a control subject (B). The anterior lobe of the pituitary gland in the patient shows markedly decreased signal intensity compared with that of the control subject.



Mean signal intensity ratios of the anterior lobe of the pituitary gland to that of pterygoid muscle and to that of nasopharyngeal fat in patients and control subjects on SE T1-weighted and GRE T2*-weighted MR images

	SE T1-Weighted Images		GRE T2*-Weighted Images	
	Pituitary-to-Fat Ratio	Pituitary-to-Muscle Ratio	Pituitary-to-Fat Ratio	Pituitary-to-Muscle Ratio
Patients	.57 \pm .1*	1.4 \pm .2*	1 \pm .4†	1.3 \pm .4‡
Control subjects	.66 \pm .1	1.6 \pm .2	1.8 \pm .6	1.7 \pm .3

Note.—Values are expressed as mean \pm SD.

* Not significant ($P > .05$) compared with controls.

† $P < .001$ compared with controls.

‡ $P < .05$ compared with controls.

deposition while the same is not true for muscle; the latter had been used as a reference in the majority of prior studies (1, 5, 6).

Others (6, 7) have used SE sequences, but we found that ratios measured on SE T1-weighted images were not significantly decreased (Table). Our findings confirm results reported in studies of liver iron overload with GRE sequences (4, 5), pointing to exquisite sensitivity of GRE T2*-weighted sequences to iron deposition. This is believed to be secondary to the lack of a 180° refocusing pulse that partially recovers the field inhomogeneity signal loss on SE images (1, 4).

According to some authors, the best predictor of pituitary iron overload is the measurement of T2 relaxation times (2, 3). In our study, we used four measurements with the shortest echo delays (20 milliseconds) available in our MR system and calculated a time constant that characterizes the decay of signal intensity on successive echoes. Such T2 relaxation time is not the actual spin-spin relaxation time that requires extremely short interecho times. In our patient population, the calculated T2 values were not significantly decreased compared with those of control subjects (44.9 ± 14 milliseconds vs 52.1 ± 16 milliseconds), probably because the low signal-to-

noise ratio on the latest echo images does not allow precise fitting of the four echoes.

It has been reported (9) that in patients with hemochromatosis there is an uneven distribution of the iron load, the preferred iron storage site being the liver; this may explain the less prominent T2 shortening for pituitary iron overload relative to that of the liver (2, 3).

In the setting of pituitary iron overload reported by some authors (7), the anterior lobe of the pituitary gland had almost no signal intensity on T1- and T2-weighted images at 1.5 T. This may be explained by the more prominent signal intensity loss at higher field strengths. Our findings, however, seem to indicate that SE sequences at a lower field strength (0.5 T) are unable to reveal slight pituitary iron overload, even with longer TEs. Conversely, we found that GRE sequences with a long TE (30 milliseconds here) have the highest sensitivity for detection of slight iron overload, owing to the inherent higher sensitivity of T2* over T2 weighting to iron deposits (4, 5).

Conclusion

Our data suggest that the most sensitive sequence for establishing iron overload in the pituitary gland is GRE T2*, as it shows significant signal loss in patients affected by secondary hemochromatosis. We found that the best predictor of pituitary iron overload is the pituitary-to-fat signal ratio, a parameter that, to date,

has not been used in prior studies of pituitary hemochromatosis (6, 7). In the future, MR pulse sequences that allow acquisition of multiple spin echoes with shorter TE delays, or other MR techniques that improve signal-to-noise ratios, will most likely improve the accuracy of T2 determination and quantification of pituitary iron overload.

References

1. Brasch RC, Wesbey GE, Gooding CA, Koerper MA. **Magnetic resonance imaging of transfusional hemosiderosis complicating thalassemia major.** *Radiology* 1984;150:767-771
2. Gomori JM, Horev G, Tamary H, et al. **Hepatic iron overload: quantitative MR imaging.** *Radiology* 1991;179:367-369
3. Stark DD, Moseley ME, Bacon BR, et al. **Magnetic resonance imaging and spectroscopy of hepatic iron overload.** *Radiology* 1985;154:137-142
4. Gandon Y, Guyader D, Heautot JF, et al. **Hemochromatosis: diagnosis and quantification of liver iron with gradient-echo MR imaging.** *Radiology* 1994;193:533-538
5. Ernst O, Sergeant G, Bonvarlet P, Canva-Delcambre V, Paris J, L'Herminé C. **Hepatic iron overload: diagnosis and quantification with MR imaging.** *AJR Am J Roentgenol* 1997;168:1205-1208
6. Miaux Y, Daurelle P, Zagdanski AM, Passa P, Bourrier P, Frija J. **MRI in haemochromatosis: pituitary versus testicular iron deposition in five patients with hypogonadism.** *Eur Radiol* 1995;5:165-171
7. Fujisawa I, Morikawa M, Nakano Y, Konishi J. **Hemochromatosis of the pituitary gland: MR imaging.** *Radiology* 1988;168:213-224
8. Housman JF, Chezmar JL, Nelson RC. **Magnetic resonance imaging in hemochromatosis: extrahepatic iron deposition.** *Gastrointest Radiol* 1989;14:59-60
9. Bergeron C, Kovacs K. **Pituitary siderosis: a histologic, immunocytologic and ultrastructural study.** *Am J Pathol* 1978;93:295-310