



Discover Generics

Cost-Effective CT & MRI Contrast Agents



WATCH VIDEO

AJNR

Cornelius G. Dyke and the Neurological Institute of New York: the foundations of American neuroradiology.

S A Kieffer

AJNR Am J Neuroradiol 1997, 18 (5) 801-809
<http://www.ajnr.org/content/18/5/801.citation>

This information is current as
of June 22, 2025.

HISTORY

Cornelius G. Dyke and the Neurological Institute of New York: The Foundations of American Neuroradiology

Stephen A. Kieffer

It was not only that he had the extraordinary skill of every outstanding roentgenological diagnostician to see every tiny shadow in the film before him. He had in addition a thorough knowledge of neuroanatomy, neuropathology, and clinical neurology.

L. M. DAVIDOFF (1)

Cornelius Gysbert Dyke, MD (Fig 1), is widely acknowledged as the first American radiologist to devote his full professional effort to the field of neuroradiology. A brilliant diagnostician, careful and thorough, he established respect for the contributions of the neuroradiologist with the neuroclinicians of his time. More than anyone else then or for a number of years thereafter, he set the standard for the growth and acceptance of neuroradiology in North America.

Dyke spent his entire (albeit tragically short) professional career at the Neurological Institute of New York, the first institution in the western hemisphere wholly devoted to the diagnosis and treatment of disorders of the nervous system and related teaching and research. The concurrence of the individual and the place created a rare serendipity that enabled major advances in knowledge within a relatively short span of time and made an impact on the clinical neurosciences that endures to the present day.

The Neurological Institute of New York

The Neurological Institute was founded by three New York neurologists (Joseph Collins, Joseph Fraenkel, and Pearce Bailey) as an independent institution in 1909. It remained independent for the first decade and a half of its existence (2). The Institute (commonly referred



Fig 1. Cornelius Gysbert Dyke, MD. This photograph was made at the time of Dr Dyke's assuming the presidency of the Harvey Cushing Society. Printed with appreciation to and by permission of the Archives of the American Association of Neurological Surgeons, Park Ridge, Ill.

to then and now as the "NI") was located on the upper east side of Manhattan at 149 E 67th St near Lexington Avenue in what was then and still remains today one of the more affluent areas of the city. During its first decade, the NI had no formal affiliation with any medical school, although students from Cornell Medical College were taught clinical neurology on its wards. In 1915, the Department of Neurological Surgery was organized under the leadership of Charles A. Elsberg with Alfred S. Taylor as associate surgeon (2). With the entry of the United States into World War I, the War Department, recognizing the unique strengths and capabilities of the NI staff and facilities, requested that the faculty of the Institute provide special training courses for medical officers of the US Army in the fields of neurosurgery and neuropsychiatry.

Address reprint requests to Stephen A. Kieffer, MD, Department of Radiology, State University of New York Health Science Center, 750 E Adams St, Syracuse, NY 13210.

During 1917 and 1918, a series of such courses was organized and conducted by the NI staff.

In the ensuing 2 decades, the neurosurgical service under Charles Elsberg achieved national and international recognition for its pioneering development of surgery of the spinal cord. Elsberg authored two texts that became classics in the field, *Diseases of the Spinal Cord and Membranes* (1916) (3) and *Tumors of the Spinal Cord* (1925) (4).

In 1921, in response to an "urgent need," a radiologic laboratory was created at the NI. The following year saw the appointment of Charles Wadsworth Schwartz as director of the newly organized Department of Radiology (5). Schwartz had received his MD from Harvard Medical School in 1919 and subsequently became the first resident in radiology at the Peter Bent Brigham Hospital in Boston, Mass, under Merrill C. Sosman. Sosman was then beginning his long and very fruitful collaboration with Harvey Cushing, and it was likely that "Waddy" Schwartz was involved in the ferment of discovery that characterized the clinical neurosciences at the Brigham at that time. After completing his training, he was recruited to New York to organize the new department at the NI and remained as its director from 1922 through 1940, when declining health led to his resignation.

A fellow house officer with Waddy Schwartz at the Brigham, Ross Golden, was also recruited to New York City in 1922 to become radiologist at the Presbyterian Hospital, but at the time the two institutions were independent and unaffiliated. Indeed, Dr Schwartz's appointment at the NI was only part time; he maintained a private practice nearby at 33 E 68th St and was also consultant to the Hospital for Special Surgery. Under his directorship, the first air ventriculogram was performed at the NI in 1922.

As early as 1919, Nicholas Murray Butler, president of Columbia University, recognized the potential value of a close affiliation or integration of the NI with Columbia's College of Physicians and Surgeons. However, the Institute's trustees preferred remaining independent and declined Dr Butler's offer. By 1924, however, a new medical campus for Columbia was being planned on the upper west side of Manhattan in conjunction with a new Presbyterian Hospital, and the trustees of the NI renewed their interest. The following year, a formal affiliation agreement with Columbia University and Presbyterian Hospital was concluded, and plans

were immediately developed for a new 14-story Institute building on a site donated by Columbia-Presbyterian at the corner of Fort Washington Avenue and West 168th Street. With remarkable alacrity (at least by current standards), some \$2 million was raised by private subscription to cover the cost of construction, and ground was broken for the new hospital on October 19, 1927 (2). On March 16, 1929, the new Neurological Institute opened its doors to patients for hospitalization. Outpatient consultations were conducted at the adjacent Vanderbilt Clinic; the new hospital was an inpatient facility.

The year 1929 proved also to be notable for the NI in another way and indeed also for the specialty of radiology, for in that year Cornelius Gysbert Dyke was recruited to join the staff at the NI as its first full-time radiologist. He arrived only a few months after the new hospital had opened its doors.

Cornelius G. Dyke: Origins and Development

Cornelius Dyke was born on July 25, 1900, in Orange City, Iowa. His paternal grandparents had emigrated from the Netherlands in 1874 and settled on a large farm in northwestern Iowa. Their forebears included theologians, scholars, and physicians. His mother's family (named Maris) were of French Huguenot origin and included three artists whose paintings are in the permanent collection of the Rijksmuseum in Amsterdam. His father, Charles, the youngest of 10 children, was in the farm implement business and was also a writer whose anecdotal history of early settlement in the region, *Story of Sioux County*, was a local best-seller that ran through two editions. Cornelius was the second of four children (he had an older brother, Lester, and two younger sisters, Grace and Esther) in a family described by Lester as "extremely keen on learning" (6). Lester described their family life as happy and free with a stream of friends often in the house, particularly on weekends. Esther (who married a urologist, Wayland Hicks, and currently resides in Sioux City) also recalls a vibrant family life centered on the church (Dutch Reformed) and on music. The four Dyke offspring formed a quartet (with Lester as bass, "Corny" as tenor, Grace as alto, and Esther as soprano) and presented many musicals at school and in the church.

Cornelius was a bright student in school and

displayed a capacity for both original and analytic thinking. Cornelius and Lester particularly admired and respected two maternal uncles, one of whom was a physician and the other a surgeon, and both eventually chose medicine as a career. Lester became an orthopedic surgeon.

At age 12, Cornelius contracted poliomyelitis, an illness that left him with a slight limp for the rest of his life. Despite this mild disability, he participated actively in organized sports, playing baseball and basketball in high school and baseball in college. He began his college education at Morningside College in Sioux City, later transferring to the State University of Iowa in Iowa City. Tall, slim, and muscular, he was not only an outstanding student but also a fine athlete who pitched well enough to make the university's varsity baseball team and to win games against the top teams in the Big Ten. It was later said of him that "throughout his life, he never lost the eager stance of an athlete" (6).

Dyke attained both a BS and an MD from the State University of Iowa College of Medicine in 1926. He then accepted a commission as a lieutenant junior grade in the US Navy to pursue an internship at the US Naval Hospital in Chelsea (Boston), Mass (1926-27), after which he spent a year at the Boston City Hospital as a house officer (1927-28). He then obtained an appointment as an assistant resident at the Peter Bent Brigham Hospital in radiology for one year (1928-29). One can only wonder what a year that must have been! By this time, Merrill Sosman's collaboration with Harvey Cushing had already yielded a rich harvest of valuable clinical-radiologic correlations that had contributed greatly to the advancement of knowledge and the improvement of medical treatment of patients with suspected lesions of the brain and spinal canal. Sosman was not only a gifted teacher but "was presiding over the richest collection of neuroradiologic material in the world" (6). We can only speculate that Cornelius Dyke's eventual contributions to neuroradiology derived in a significant way from his exposure to Sosman and to Cushing. Other contributors to American neuroradiology who spent all or a part of their training with Merrill Sosman included John Camp of the Mayo Clinic (in the 1920s) and Harold Peterson of the University of Minnesota (in the mid-1930s).

Little is known today of Dyke's family or personal life after he completed his professional education. Davidoff (6) records that Dyke met



Fig 2. Dr Dyke holding his young son Gysbert ("Bert"). Printed by courtesy of and with special appreciation to Esther Dyke Hicks, Sioux City, Iowa.

his future wife Doris in 1927 at the Peter Bent Brigham Hospital, where she was the administrative dietitian, but that they really did not start dating until early 1928. After a journey later that year to Europe, Doris was appointed head of dietetics at the Waterbury Hospital in Waterbury, Conn. She and Cornelius were married at the home of her parents in Milwaukee, Wis, in September 1930. Davidoff describes the marriage as "happy, uncomplicated" and indicates that Dyke was devoted to his family and was "deeply and sincerely religious" but did not regularly attend church. Esther Dyke Hicks recalls her brother as "good natured, generous to his family, and good to his parents." The young couple resided first in White Plains, NY, and later in Chappaqua, NY.

Doris and Cornelius had two sons, Cornelius E. and Gysbert C., who were still very young when they lost their father (Fig 2). Cornelius ("Neil" to his family) made his career in education, eventually becoming principal of a school in the Milwaukee, Wis, area. Gysbert ("Bert") was last known to be residing in California.

Dyke and the Neurological Institute

A Fortuitous Concurrence

Despite the special strength in the clinical neurosciences at the Brigham during Dyke's year in residency, it is likely that he would have become a general radiologist on completion of

his training. There was great demand for physicians trained in this emerging specialty in the late 1920s. During his residency, Dyke collaborated with Sosman on an analysis of postoperative massive pulmonary atelectasis, his only publication during his lifetime in general diagnostic radiology (7), and his training with one of the acknowledged masters of radiologic analysis would surely have brought him many good offers. It was therefore a most fortuitous concurrence that the newly relocated and expanded Neurological Institute saw fit at the same time to recruit a full-time radiologist, and it was not at all surprising that it turned to the same program in which Charles W. Schwartz, its director of radiology, had trained.

According to neurosurgeon Leo M. Davidoff (6), when Dyke accepted the NI appointment, "he then and there became a student of neuroanatomy, neurophysiology, neuropathology, and clinical neurology. Combining his knowledge of these disciplines with a keen eye for details in the roentgenogram, he quickly became one of the leaders in the field of neuroradiology."

Within a short time after his appointment, Dyke began exploring the rich accumulation of case experience he found at the NI. Over the ensuing 13½ years, he carefully and methodically built a solid foundation of clinical application for the radiologic method in the evaluation and treatment of patients with suspected disorders of the central nervous system. His contributions during this extraordinary period encompassed the entire spectrum of neuroradiologic procedures that were available in his era, including plain-film diagnosis of the spine and skull, pneumoencephalography, and myelography (with iodized oil, for this was before the synthesis of iophendylate).

A Productive Beginning

With Charles Elsberg, perhaps the foremost spinal surgeon of his time, Dyke defined the normal range of spinal interpediculate diameters and firmly established this measurement as a reliable tool for detection and location of intraspinal tumors (8, 9). Although the utility of plain skull radiography in the diagnosis of intracranial tumors had been established during the 1920s (mainly by the extensive experience of Sosman working with Cushing at Brigham), Dyke nevertheless was able in his first publica-

tion in neuroradiology (1930) to document the usefulness of displacement of the calcified pineal gland as a reliable indirect indicator of the presence of a space-occupying intracranial mass (10). It is interesting to note that this work was based mainly on stereoscopic lateral views of the skull, anteroposterior views not being part of the "routine skull series" at the time. Two years later (1932), Kasabach and Dyke definitively documented with serial radiography the transition from osteoporosis circumscripta to full-blown Paget disease involving the cranial vault (11), a relationship that had been suspected but not proved until that report.

Davidoff and Dyke

In the same year, Leo M. Davidoff (at that time a junior neurosurgeon at the Neurological Institute) and Dyke described *An Improved Method of Encephalography* (12) in which, by injecting small aliquots of oxygen via lumbar puncture, obtaining a preliminary film after the first 20 mL in order to ascertain ventricular size, and "using only enough additional gas to obtain satisfactory visualization of the ventricular system in accordance with its size" (6), they were able to reduce significantly the morbidity associated with this procedure. They were also able to improve its information content by using the patient's posture and position to place the air in the area of clinical interest. This seminal publication led to a major change in clinical practice. Previously, clinicians had been reluctant to use pneumoencephalography; the then-accepted method required a "complete" exchange of ventricular fluid with gas and was associated with a high incidence of severe patient discomfort. The improvements described by Davidoff and Dyke led to a much increased acceptance of pneumoencephalography and a corresponding reduction in the use of ventriculography.

Davidoff and Dyke had in essence created a new diagnostic examination, and the additional information provided by this technique led to a series of basic papers defining the normal pneumoencephalographic anatomy of the choroid plexuses (13), the quadrigeminal plate (14), the cerebral gyri and sulci (15), the subarachnoid cisterns and their contents (16), and the ventricular system (17). This series was published in rapid succession by the two young collaborators in the *Bulletin of the Neurological Insti-*

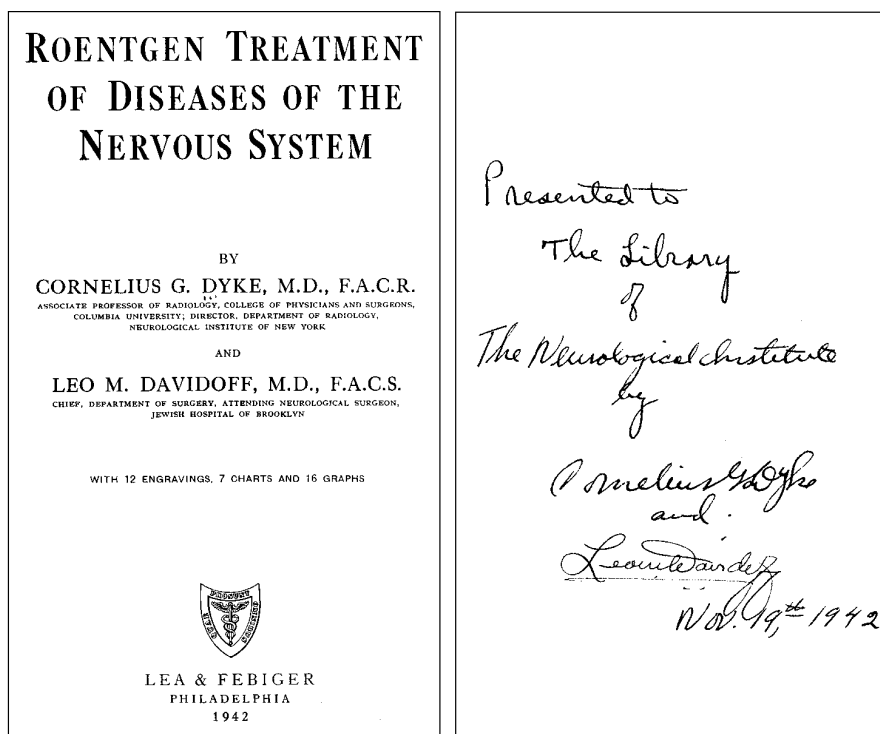


Fig 3. Title page and inner page with personal inscription from a copy of Dyke and Davidoff's monograph on therapeutic radiology presented by its authors to the Neurological Library of Columbia University's College of Physicians and Surgeons. Printed with appreciation to and by permission of the Department of Neurology, Columbia University College of Physicians and Surgeons, New York, NY.

tute of New York between 1932 and 1935. These studies were then expanded into a more comprehensive monograph, *The Normal Encephalogram* (1937) (18), which became an instant classic, widely used throughout the world for the next quarter century.

For Cornelius Dyke and Leo Davidoff, the extensive exploration of the limits of normal of the anatomy of the brain as depicted on air studies represented a true magnum opus, a major work. It also provided the foundation for a further body of work defining abnormal radiographic anatomy and correlating their observations with clinical manifestations and with gross pathology. The first of these publications (1933) described a series of nine patients who presented with a history of infantile hemiplegia and demonstrated cerebral hemiatrophy with ipsilateral compensatory hypertrophy of the calvaria, paranasal sinuses, and mastoid air cells (19). This condition is still recognized today by the eponym of the authors (Dyke, Davidoff, and Masson) who originally described it.

Other notable contributions by Davidoff and Dyke included papers defining the pneumoencephalographic findings in agenesis of the corpus callosum (20), absence of the septum pellucidum (21), tumors involving the corpus

callosum (22), recurrent chronic subdural hematoma (23), intraventricular epidermoid tumor (24), pseudotumor cerebri (25), heman-gioblastoma of the cerebellum (26), and acquired pressure diverticulum of the medial wall of the atrium of the lateral ventricle with herniation of the diverticulum downward through the tentorial incisura (27). This extensive oeuvre formed a major foundation for Davidoff and Epstein's text *The Abnormal Encephalogram* (28), published in 1950.

The reader should be aware that at the time most of these entities were either poorly understood or not recognized clinically. Methodical observation and careful analysis by the radiologist and the surgeon, both firmly grounded in neuroanatomy and in clinical neurology and working in close collaboration at an institution with extraordinary case material, resulted in a major expansion and refinement of the field of neurologic diagnosis in which the radiographic studies provided the foundations on which clinical knowledge and understanding were developed.

Therapeutic Radiology

A facet of Cornelius Dyke's professional activity that is little known to diagnostic radiolo-



Fig 4. Dr Dyke in a moment of relaxation on the porch of the Neurological Institute shortly after his appointment to its staff. Printed by courtesy of and with special appreciation to Esther Dyke Hicks, Sioux City, Iowa.

gists today is his contribution to the field of radiation oncology. In the early years of radiology's emergence as a separate and identifiable medical specialty, its practitioners were responsible for all clinical applications of ionizing radiation, including therapeutic as well as diagnostic. As early as 1931, Dyke and Sidney Gross described the early and largely favorable results of "roentgenotherapy" in patients with pituitary tumors (29). As further experience was accumulated, successive papers by C. C. Hare and Dyke in 1933 (30) and 1936 (31) provided longer-term follow-up in larger patient trials.

This initial success led Charles Elsberg to investigate the possibility of intraoperative radiation therapy for treating unresectable brain tumors. Elsberg noted that in 1936 that "a large shockproof roentgen apparatus was installed in the operating room for treatment patients with irremovable tumors of the brain by direct radiation through the open wound. . .the experimental investigations and the treatment of patients were conducted by the chief of the surgical service, by Dr Davidoff, and by Dr Dyke of the roentgen department" (5). However, the results were disappointing, and the intraoperative radiation experiment was discontinued. Nevertheless, Dyke continued to practice therapeutic radiology as applied to lesions affecting the central nervous system and to accumulate considerable clinical experience in that field, publishing a small monograph on this topic in 1942 (32) (Fig 3).

Insights and Personal Aspects

When Cornelius Dyke joined the staff of the Neurological Institute in 1929 (Fig 4), he was appointed assistant director of its Department of Radiology. However, his initial academic appointment to the faculty of Columbia University's College of Physicians and Surgeons with the rank of assistant professor did not take place until 1935. The incongruity between Dyke's hospital and academic appointments likely relates to the semi-independent status of the Neurological Institute at that time, with its own separate board of trustees and a separate financial structure. In 1937, the three clinical entities affiliated with Columbia (Presbyterian Hospital, the Neurological Institute, and Babies Hospital) merged their boards and their finances into a single corporate entity that survives to the present day. One year later, Dyke was proposed for promotion to associate professor of clinical radiology by Charles W. Schwartz, his chief at the NI, and by Ross Golden, director of radiology at Presbyterian Hospital and chairman of radiology at Columbia. The promotion was readily approved and granted.

Charles Schwartz, although always in a part-time status, had headed the Department of Radiology at the NI since its creation in 1922. In the late 1930s, he developed essential hypertension, and by 1940 his illness had limited his professional activity to the point where he felt constrained to resign both his hospital and his academic appointments. However, he remained actively interested in the department and the medical center, participating in special events and activities until his death in 1957.

Dyke succeeded Dr Schwartz as director of radiology in 1940. Since 1929, the Department of Radiology had occupied a small suite of rooms on the tenth floor of the Neurological Institute. J. Lawrence Pool, who headed the Department of Neurological Surgery in the 1950s and 1960s, recalled that "the location of the x-ray department. . .on the same floor with the operating room was. . .an advantage to the surgeons" (33). Pool noted that Dyke "combined ability, enthusiasm and energy, and under his guidance the roentgen laboratory became an important and productive department of the institution" (33).

Dyke worked in a relatively small radiologic suite on the tenth floor of the Neurological Institute. He interpreted most of his plain film studies

using a Wheatstone bridge, a simple but effective device that used angled mirrors to enable stereoscopic film pairs to be superimposed efficiently in the visual field of the reader. The small reading room also contained a wall-mounted set of eight viewboxes (four over four). Dyke dictated his reports and interpretations to a typist, who also functioned as technologist and receptionist. The department consisted of two diagnostic rooms, one of which contained a fluoroscope and a tilting table ($90^{\circ}/60^{\circ}$) for myelography, and a single radiation therapy room with an orthovoltage (200 kV) apparatus.

In late 1942, Ernest H. Wood, who was subsequently to become director of radiology at the NI in 1946, was a second-year resident in radiology at Presbyterian Hospital and was awaiting orders for activation by the US Army when he requested to "spend some time" with Dr Dyke as a rotating resident. Dyke had not up to that time accepted radiology residents on his service. Wood subsequently wrote, "I am not sure why he accepted me, but he did seem to like the fact that I had previously taken extra work in neurology under Dr H. H. Merritt and had gone into radiology largely as a result of the inspiring teaching of Dr M. C. Sosman" (34).

Wood's uncertainty as to why he was accepted as a trainee and his revelation that he was the first radiology resident at Columbia to be formally assigned and accepted for training with one of the accepted masters of the subspecialty suggest that Dyke was not particularly interested in mentoring residents in radiology. Indeed, his day-to-day clinical work as well as his clinical research were almost entirely in consultation and collaboration with neurologists and neurosurgeons. Wood adds that "Dr Dyke's predominantly clinical interest is pointed up by the fact that the great majority of his publications were with clinical colleagues, some were written alone but only a few with other radiologists" (34). Lois Cowan Collins, who joined the faculty at Columbia in mid-1942, recalls that when the radiology residents at Columbia-Presbyterian would cross Fort Washington Avenue to seek Dr Dyke's consultation on a particular case, they would generally be given courteous but brief assessments without elaboration. Dr Collins gained the impression that he was a "rather aloof" person, but adds that she had little opportunity for personal contact with him.

These comments and those of Dyke's close collaborator Leo Davidoff (6) provide a picture

of a true scholar and innovator, eager for discovery and stimulated by the challenge of a clinical diagnostic problem. According to Lois Collins, Dyke's knowledge of clinical neurology and neuropathology were legendary; he "held his own very well" with neurologists and neurosurgeons, and his opinions were held in high esteem by them. He performed neurologic examinations on many patients, and more than one radiologic colleague wondered what part of his outstanding reputation as a neurodiagnostician was based on his clinical acumen.

Dyke developed an outstanding reputation as a teacher. His scientific exhibits and instructional courses at the annual meetings of the American Roentgen Ray Society attracted wide interest. He was actively involved in the organizational aspects of the rapidly developing speciality of radiology and held the position of first vice president of the American Roentgen Ray Society at the time of his death in early 1943. It is especially interesting to note that he was one of the 23 founding members of the Harvey Cushing Society (now the American Association of Neurological Surgeons) and served as its president in 1940-41 (Fig 1).

A Premature Conclusion

Only a few weeks after Ernest Wood began his training in neuroradiology with Cornelius Dyke, Dyke's health began to fail. In the fall of 1942, after speaking at a meeting in Cleveland, he journeyed by rail to visit his parents and family in northwestern Iowa. His sister Esther recalls the visit and remembers his running a low-grade fever during his stay. He was admitted to the hospital shortly after Christmas 1942, and a diagnosis of acute myelogenous leukemia was established. During January and February of 1943, he attempted to continue his professional work but was frequently interrupted by the need for rehospitalization for transfusions. His disease followed a rapid downhill course, and he died on April 23, 1943.

In a memorial tribute delivered to the Harvey Cushing Society at its meeting in New York on May 8, 1943, his longtime associate and close friend Leo Davidoff stated, "He was a staunch friend and possessed a shining honesty that blazed through superficialities to the heart of every matter he touched. He was judicious to the point where often other and more experienced colleagues sought his judgment. He was

calm, self-possessed and patient so that he was one of the most instructive and popular teachers at both the medical school and hospital" (1).

Cornelius G. Dyke, MD, was only 42 years old when he died. In the relatively short span of less than 13 years that he worked at the Neurological Institute of New York, he not only contributed an immense body of new clinical knowledge but also established a pattern for the practice of clinical neuroradiology that was solidly based on clinical and pathologic correlation, reliable and thorough. In so doing, he laid extraordinarily strong foundations for the development of the subspecialty of neuroradiology in North America. Succeeding generations of neuroradiologists have placed great reliance on those foundations and have not been disappointed. In recognition of Dyke's contributions, the American Society of Neuroradiology created the Cornelius G. Dyke Award in 1971 for the best original research contribution by a junior investigator in the field of neuroradiology. This is the premier recognition awarded by the Society each year. It serves as a singularly appropriate reminder of the clinician/scholar who in essence created the subspecialty of neuroradiology in North America.

Acknowledgments

I wish to acknowledge with deep gratitude the contributions of the following persons who aided immensely in the gathering of information for this article: Alexander G. Khandji, associate professor of radiology and clinical director of neuroradiology, Sadek K. Hilal, professor of radiology and director of neuroradiology, Martin Collins, archivist, and Sheila Crescenzo, administrative aide, Department of Neurology, all at the Columbia University College of Physicians and Surgeons, New York, NY; Norman E. Leeds, professor of radiology and director of neuroradiology at the University of Texas M. D. Anderson Hospital, Houston, Tex; Lois Cowan Collins, Houston, Tex; Chris Ann Philips, archives coordinator of the American Association of Neurological Surgeons, Park Ridge, Ill; Peter C. Dyke, Dana Point, Calif, nephew of Cornelius G. Dyke; and Esther Dyke Hicks, Sioux City, Iowa, sister of Dr Dyke.

My research for this article was hampered by a paucity of sources of original information. The files of the Department of Radiology at Columbia-Presbyterian Medical Center no longer include information regarding Cornelius G. Dyke. The archives of Columbia's College of Physicians and Surgeons and of the American Association of Neurological Surgeons contained only very limited documents and information. The interested reader who seeks further information on Dr Dyke by exploring the bibliographic

sources listed below will quickly realize that in preparing this review I borrowed heavily from Leo Davidoff's published recollections (6). I note these inadequacies neither by way of apology nor of criticism but rather as an observation on the fleeting and transitory nature of the recognition of a major contributor to the development of neuroradiology. Neuroradiology is still a reasonably young field, but we cannot ignore the inevitable. This leads me to wonder whether the American Society of Neuroradiology might wish to consider creating an archive of its historical foundations, milestones, and heritage and of the lives of the individuals who contributed to that heritage.

References

1. Davidoff LM. Cornelius Gysbert Dyke. *AJR Am J Roentgenol* 1943;50:113
2. Riley HA. The Neurological Institute of New York: the first hospital in the western hemisphere for the treatment of disorders of the nervous system: the intermediate years. *Bull N Y Acad Med* 1966; 42:654-678
3. Elsberg CA. *Diagnosis and Treatment of Surgical Diseases of the Spinal Cord and Its Membranes*. Philadelphia, Pa: WB Saunders Co; 1916
4. Elsberg CA. *Tumors of the Spinal Cord and the Symptoms of Irritation and Compression of the Spinal Cord and Nerve Roots: Pathology, Symptomatology, Diagnosis and Treatment*. New York, NY: PB Hoeber Inc; 1925
5. Elsberg CA. *The Story of a Hospital, the Neurological Institute of New York, 1909-1938*. New York, NY: PB Hoeber Inc; 1944
6. Davidoff LM. Cornelius Gysbert Dyke, pioneer neuroradiologist. *Bull N Y Acad Med* 1969;45:665-680
7. Dyke CG, Sosman MC. The postural treatment of postoperative massive atelectatic collapse. *Surg Gynecol Obstet* 1929;49:752-763
8. Elsberg CA, Dyke CG. The diagnosis and localization of tumors of the spinal cord by means of measurements made on the x-ray films of the vertebrae and correlation of clinical and x-ray findings. *Bull Neurol Inst N Y* 1933;3:359-394
9. Elsberg CA, Dyke CG, Brewer ED. The symptoms and diagnosis of extradural cyst. *Bull Neurol Inst N Y* 1934;3:395-417
10. Dyke CG. Indirect signs of brain tumor as noted in routine roentgen examinations: displacement of the pineal shadow. *AJR Am J Roentgenol* 1930;23:598-606
11. Kasabach HH, Dyke CG. Osteoporosis circumscripta of the skull as a form of osteitis deformans. *AJR Am J Roentgenol* 1932;28: 192-203
12. Davidoff LM, Dyke CG. An improved method of encephalography. *Bull Neurol Inst N Y* 1932;2:75-94
13. Dyke CG, Davidoff LM. The demonstration of normal cerebral structures by means of encephalography, I: the choroid plexuses. *Bull Neurol Inst N Y* 1932;2:331-346
14. Davidoff LM, Dyke CG. The demonstration of normal cerebral structures by means of encephalography, II: the corpora quadrigemina. *Bull Neurol Inst N Y* 1933;3:138-146
15. Davidoff LM, Dyke CG. The demonstration of normal cerebral structures by means of encephalography, III: the cerebral convolutions and sulci. *Bull Neurol Inst N Y* 1933;3:147-189
16. Dyke CG, Davidoff LM. The demonstration of normal cerebral structures by means of encephalography, IV: the subarachnoid cisterns and their contents. *Bull Neurol Inst N Y* 1934;3:428-445
17. Davidoff LM, Dyke CG. The demonstration of normal cerebral structures by means of encephalography, V: the ventricles, inter-

- ventricular foramina, and aqueduct of Sylvius. *Bull Neurol Inst N Y* 1935;4:91-132
18. Davidoff LM, Dyke CG. *The Normal Encephalogram*. Philadelphia, Pa: Lea & Febiger; 1937
 19. Dyke CG, Davidoff LM, Masson CB. Cerebral hemiatrophy with homolateral hypertrophy of skull and sinuses. *Surg Gynecol Obstet* 1933;57:588-600
 20. Davidoff LM, Dyke CG. Agenesis of the corpus callosum: its diagnosis by encephalography: report of three cases. *AJR Am J Roentgenol* 1934;32:1-10
 21. Dyke CG, Davidoff LM. Congenital absence of the septum pellucidum: its diagnosis by encephalography. *AJR Am J Roentgenol* 1935;34:573-578
 22. Dyke CG, Davidoff LM. The pneumoencephalographic diagnosis of tumors of the corpus callosum. *Bull Neurol Inst N Y* 1936;4:602-623
 23. Dyke CG, Davidoff LM. Relapsing juvenile chronic subdural hematoma: a clinical and roentgenographic study. *Bull Neurol Inst N Y* 1938;7:95-111
 24. Dyke CG, Davidoff LM. Encephalographic appearance of an intraventricular epidermoid. *Bull Neurol Inst N Y* 1937;6:489-493
 25. Davidoff LM, Dyke CG. Hypertensive meningeal hydrops. *Am J Ophthalmol* 1937;20:908-927
 26. Dyke CG, Davidoff LM. The pneumoencephalographic appearance of hemangioblastoma of the cerebellum. *AJR Am J Roentgenol* 1940;44:1-8
 27. Dyke CG. Acquired subtentorial pressure diverticulum of a cerebral lateral ventricle. *Radiology* 1942;39:167-174
 28. Davidoff LM, Epstein BS. *The Abnormal Pneumoencephalogram*. Philadelphia, Pa: Lea & Febiger; 1950
 29. Dyke CG, Gross SW. The roentgenotherapy of pituitary tumors. *Bull Neurol Inst N Y* 1931;1:211-228
 30. Hare CC, Dyke CG. Roentgen therapy of pituitary tumors: report of twenty cases. *Arch Ophthalmol* 1933;10:202-225
 31. Dyke CG, Hare CC. Roentgen therapy of pituitary tumors: report of sixty-three cases. *Proc Assoc Res Nerv Mental Dis* 1936;17:651-664
 32. Dyke CG, Davidoff LM. *Roentgen Treatment of Diseases of the Nervous System*. Philadelphia, Pa: Lea & Febiger; 1942
 33. Pool JL, ed. *The Neurological Institute of New York, 1909-1974, with Personal Anecdotes*. Lakeville, Conn: Pocket Book Press; 1975
 34. Wood EH. Neuroradiology. In: Pool JL, ed. *The Neurological Institute of New York, 1909-1974, with Personal Anecdotes*. Lakeville, Conn: Pocket Book Press; 1975:86-89