



## Discover Generics

Cost-Effective CT & MRI Contrast Agents

 FRESENIUS  
KABI

[WATCH VIDEO](#)

# AJNR

## **Functional MR of the primary auditory cortex: an analysis of pure tone activation and tone discrimination.**

J C Strainer, J L Ulmer, F Z Yetkin, V M Haughton, D L Daniels and S J Millen

This information is current as of June 4, 2025.

*AJNR Am J Neuroradiol* 1997, 18 (4) 601-610  
<http://www.ajnr.org/content/18/4/601>

# Functional MR of the Primary Auditory Cortex: An Analysis of Pure Tone Activation and Tone Discrimination

John C. Strainer, John L. Ulmer, F. Zerrin Yetkin, Victor M. Haughton, David L. Daniels, and Steven J. Millen

**PURPOSE:** To use functional MR imaging to measure the effect of frequency (pitch), intensity (loudness), and complexity of auditory stimuli on activation in the primary and secondary auditory cortices. **METHODS:** Multiplanar echo-planar images were acquired in healthy subjects with normal hearing to whom auditory stimuli were presented intermittently. Functional images were processed from the echo-planar images with conventional postprocessing methods. The stimuli included pure tones with a single frequency and intensity, pure tones with the frequency stepped between 1000, 2000, 3000, or 4000 Hz, and spoken text. The pixels activated by each task in the transverse temporal gyrus (TTG) and the auditory association areas were tabulated. **RESULTS:** The pure tone task activated the TTG. The 1000-Hz tone activated significantly more pixels in the TTG than did the 4000-Hz tone. The 4000-Hz tone activated pixels primarily in the medial TTG, whereas the 1000-Hz tone activated more pixels in the lateral TTG. Higher intensity tones activated significantly more pixels than did lower intensity tones at the same frequency. The stepped tones activated more pixels than the pure tones, but the difference was not significant. The text task produced significantly more activation than did the pure tones in the TTG and in the auditory association areas. The more complex tasks (stepped tones and listening to text) tended to activate more pixels in the left hemisphere than in the right, whereas the simpler tasks activated similar numbers of pixels in each hemisphere. **CONCLUSION:** Auditory stimuli activate the TTG and the association areas. Activation in the primary auditory cortex depends on frequency, intensity, and complexity of the auditory stimulus. Activation of the auditory association areas requires more complex auditory stimuli, such as the stepped tone task or text reading.

**Index terms:** Hearing; Magnetic resonance, functional

*AJNR Am J Neuroradiol* 18:601-610, April 1997

Functional magnetic resonance (MR) imaging is a relatively new technique for detecting discrete areas of metabolic change within the brain resulting from neuronal activity. Indirect visualization of this neural activity is made possible by the accompanying changes in regional cerebral blood flow (rCBF) and local blood de-

oxyhemoglobin concentration within the activated cortex (1, 2). Functional MR imaging offers anatomic detail not available with positron emission tomography (PET) or other functional imaging techniques and more precise localization of activation centers within the cerebral cortex. Investigators have shown the feasibility of using functional MR imaging to examine cerebral cortical activation in response to sensory, motor, and tactile stimuli (3-6).

Recent studies with functional MR imaging have shown consistent signal changes within the superior temporal gyrus in response to various auditory stimuli (7, 8). Thus far, these reports have described the effects of stimulus rates and content of auditory stimuli on the pattern of cortical activation from binaural stimuli. The focus of these efforts has been the function of auditory association areas in response to these stimuli. A recent investigation has re-

---

Dr Strainer received the Cornelius G. Dyke Memorial Award at the annual meeting of the American Society of Neuroradiology, Seattle, Wash, June 1996.

Received January 12, 1996, for Dyke award; received for *AJNR* April 10; accepted after revision October 10.

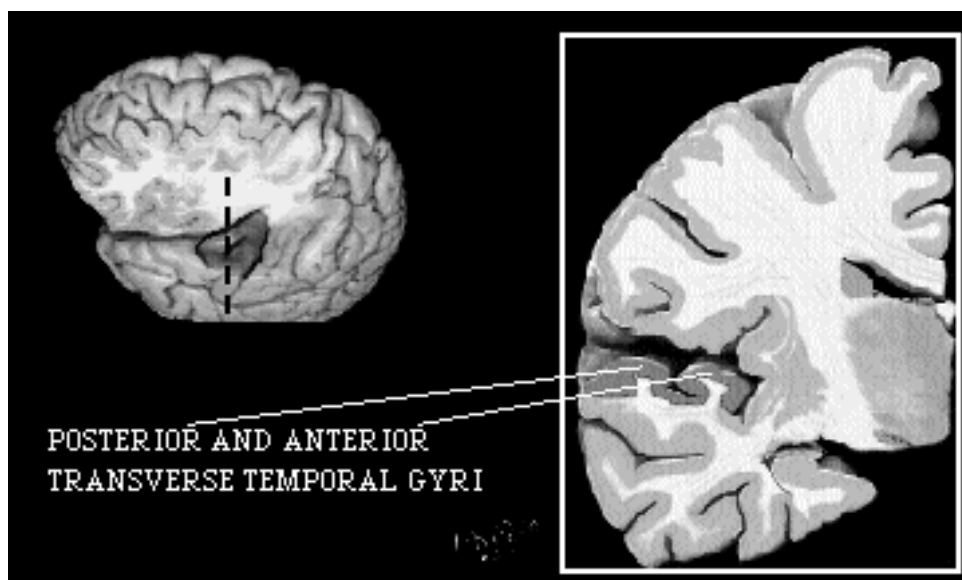
From the Department of Radiology (J.C.S., J.L.U., F.Z.Y., V.M.H., D.L.D.), the Medical College of Wisconsin, Milwaukee, and Milwaukee Otologic (S.J.M.).

Address reprint requests to John L. Ulmer, MD, Department of Radiology, Medical College of Wisconsin, 9200 W Wisconsin Ave, Milwaukee, WI 53226.

*AJNR* 18:601-610, Apr 1997 0195-6108/97/1804-0601

© American Society of Neuroradiology

Fig 1. Illustration of the TTG (shaded area) of the superior temporal gyrus (left), exposed by partial resection of frontal and parietal lobes. Note oblique orientation of the gyrus and intermediate transverse temporal sulcus, which may be complete, partial, or non-existent. The TTG (Heschl's gyrus) contains the primary auditory cortex. Coronal section through the temporal lobe (right) shows the location of the TTG (shaded area) in relation to other brain areas (coronal section modified from Duvernoy [56]).



vealed activation within the primary auditory cortex (transverse temporal gyrus [TTG]) in response to a simple pure tone stimulus (9). To date, the tonotopic organization of the primary auditory cortex and the effect of tone intensity on cortical activation have not been thoroughly studied by means of functional MR imaging techniques. The purpose of this study was to investigate the functional integration of the primary auditory cortex and to develop tasks for probing both the primary and association areas of the auditory cortex. Specifically, our goal was to examine the effects of tone frequency, tone intensity, and tone complexity as they relate to activation within the auditory cortex.

## Subjects and Methods

### Subjects

Ten volunteers (three women and seven men, 22 to 32 years old) were studied. All subjects reported good health and no history of auditory abnormalities. All subjects were right-handed as determined by the Edinburgh handedness inventory. Prior to testing, normal auditory thresholds were confirmed in all subjects. In accordance with institutional standards, all subjects gave written informed consent and received an hourly stipend for their participation. Subjects were positioned within the gantry after tightly occlusive ear plugs were placed to minimize ambient noise, and they were instructed not to move during image acquisitions.

### Equipment and Scanning Procedure

A commercial 1.5-T scanner was used, equipped with a bird-cage prototype whole-volume echo-planar local gra-

dient three-axis head coil. An experimental program provided a single-shot, blipped, echo-planar sequence with multisection or multirepetition capabilities with either a spin echo or gradient-echo. Chemical shift saturation was used before the excitation pulse to diminish ghost artifacts from the fat-containing tissues in the head.

A series of localizer images was obtained in the sagittal and coronal planes. On the basis of these images, a coronal plane was selected (Fig 1) for obtaining the anatomic reference images upon which the functional data were superimposed. These anatomic reference images were obtained with parameters of 600/20/2 (repetition time/echo time/excitations), 24-cm field of view,  $128 \times 256$  matrix, and 1-cm-thick sections.

Each functional image was generated from 90 images obtained in the selected plane at 2-second intervals. A series of 90 echo-planar images was collected, which consisted of four 20-second stimulation intervals, during which auditory stimuli were presented, alternating with four 20-second rest intervals, during which no auditory stimuli were presented (except ambient scanner noise). Technical parameters for the functional data acquisition included gradient echo-planar pulse sequences as follows: 2000/40,  $64 \times 64$  matrix, 24-cm field of view, and 1-cm-thick sections. The series of images was analyzed by viewing the images consecutively in cine mode to determine whether the volunteer moved. If significant motion occurred, images for that task were not included in the data set. The time course of the signal intensity within each pixel over 180 seconds was plotted and compared with a reference pixel by means of an  $n$ -dimensional vector cross-correlation program. For each task, only those pixels with clear, temporally correlated signal increases were considered to be activated and subsequently selected for referencing (Fig 2). Pixels that cross-correlated significantly with the reference pixel ( $P < .0001$ ) were displayed in the functional images as activated pixels. The activated

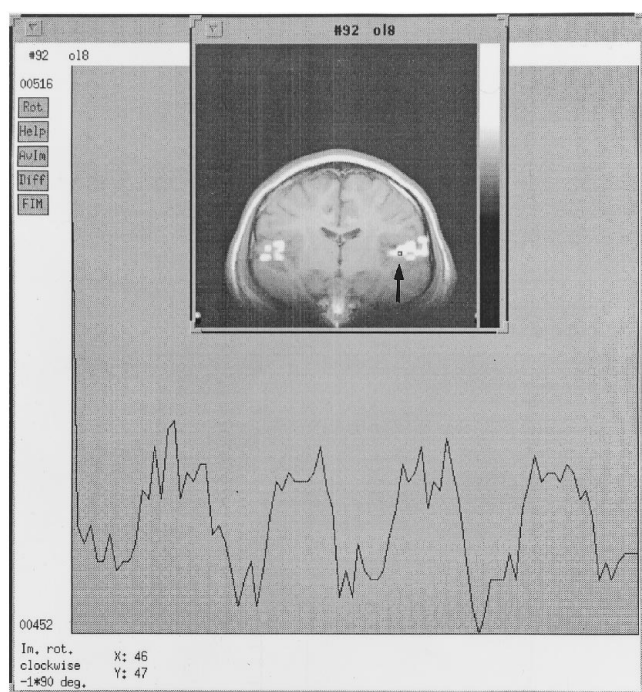


Fig 2. Signal intensity change over time is displayed in a single pixel (arrow) of the superior temporal gyrus in an individual subject. The horizontal axis of the pixel represents the total duration of an image series lasting 3 minutes (180 seconds), which includes a series of four 20-second activation periods, alternating with five 20-second rest periods. The vertical axis indicates a percentage of signal change relative to the mean signal. The active pixel as shown here, chosen for referencing, shows temporal increases in signal change corresponding in time course to the auditory stimuli presented.

pixels in the functional image were then overlaid on the exactly corresponding coronal anatomic reference images by means of the image processing program. Regional activation was calculated as the number of pixels activated in the TTG, which encompasses the primary auditory cortex. Activated pixels were also assessed in the adjacent associative auditory cortex. The region of interest in which pixels were counted was identical for each subject.

#### *Auditory Stimuli*

Auditory stimuli were as follows: (a) pure tones of constant intensity (20 or 50 dB above threshold) and frequency (1000, 2000, 3000, or 4000 Hz) in separate series of pulsed tones; (b) pure tones of constant intensity varying stepwise in frequency between 1, 2, 3, and 4 kHz; and (c) written text read to the subject at constant sound intensity (50 dB above threshold). Auditory stimuli during each functional imaging series were delivered in four 20-second intervals alternating with five 20-second rest intervals. The presentation of separate tone series was counterbalanced to minimize the effects of habituation or learning. Pure tones were generated by a calibrated audiometer. All auditory stimuli were delivered monaurally to

the right ear via an air conduction speaker system equipped with a pair of plastic tubes 4 ft in length. Detection thresholds were established separately for text reading and for each frequency tone. In each subject, stimuli were delivered at intensities that were 20 or 50 dB above the subject's threshold or sensation level (SL) (ie, 20 or 50 dB SL). Thresholds were determined with the subject in the gantry during scanner operation with the associated ambient scanner noise present.

## **Results**

### *Pure Tone Activation of the Primary Auditory Cortex*

In all 10 subjects, pixels were activated over background levels in the region corresponding to the TTG after pure tone stimulation of 1000 Hz at 50 dB SL. On the other hand, only four of six subjects showed activation at a pure tone intensity of 20 dB SL. For 12 TTGs in six subjects, the mean number of pixels activated with a 20-dB SL stimulus was 4.3 compared with 11.0 with 50 dB SL, indicating a significantly greater neuronal response to the higher intensity ( $P < .05$ ) (Fig 3). There was no significant difference between right and left TTG activation to pure tone stimuli, despite the fact that all tones were delivered monaurally to the right ear.

### *Primary Auditory Cortex: Response to Different Frequencies*

Our findings indicate an affinity of the primary auditory cortex for tones in the lower (1000 to 2000 Hz) frequency range relative to tones in the higher (3000 to 4000 Hz) frequency range under our experimental conditions. This effect is illustrated in Figure 4, in which the number of pixels activated within the TTG is greater in response to 1000 Hz than to 4000 Hz. While all subjects showed TTG activation to a 1000-Hz tone stimulus, activation was detected in only 50% of subjects at 4000 Hz. Figure 5 illustrates a graded increase in activation of the TTG as tones of decreasing frequency were presented, resulting in a significantly greater number of pixels activated at 1000 Hz than at 4000 Hz ( $P < .01$ ).

Analysis of tonotopic organization was performed by comparing the location of activation from low-frequency tones with high-frequency tones. For the 1000-Hz tone, the proportion of activated pixels in the *lateral* half of the TTG

Fig 3. A, Coronal section through the TTG shows no detectable TTG activation in response to a 1000-Hz tone at 20 dB SL.

B, Image obtained from the same subject shows pronounced cortical activation within the right TTG and a small amount of activation within the left TTG after delivery of a 1000-Hz pure tone at 50 dB SL.

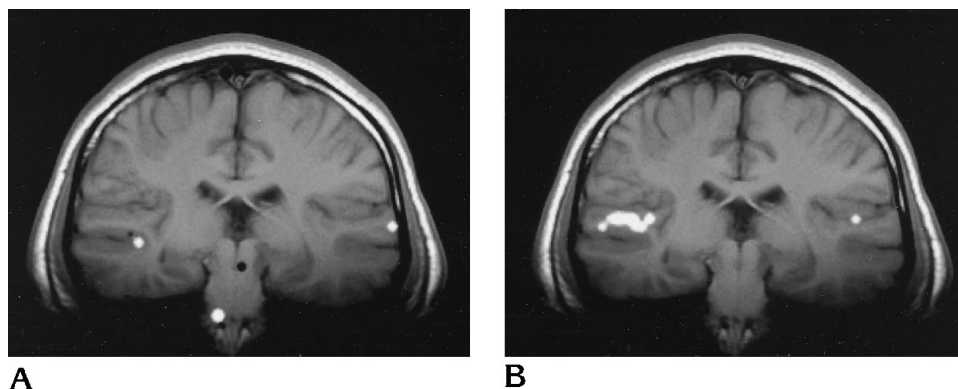
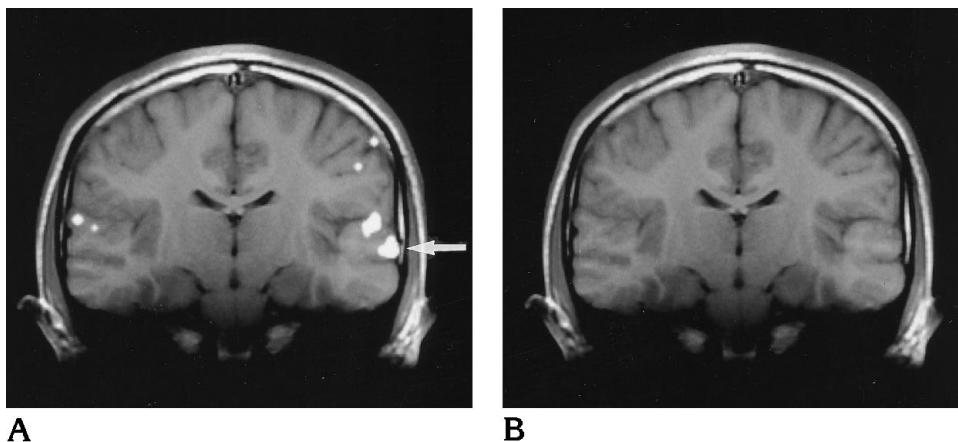


Fig 4. A, Coronal section shows prominent left and mild right cortical activation within the region of the TTG in response to a 1000-Hz pure tone (arrow indicates activity more inferiorly in areas of auditory association cortex of the left temporal lobe).

B, Coronal section obtained from the same subject shows no detectable cortical activity within the TTG in response to a 4000-Hz pure tone stimulus.



was on average 67%. For the 4000-Hz tone, the proportion of activated pixels in the *medial* half of the TTG was 83%. Figures 6 and 7 illustrate this tonotopic distribution with predominant lateral activation following low-frequency stimulation and medial activation with higher frequency tones.

#### Auditory Cortex: Stepped Frequencies

Delivery of stepwise increasing tones from 1000 to 4000 Hz resulted in TTG activation similar to that shown with single pure tone stimuli (Fig 8). However, an increased total area of activation occurred when cortical areas outside the TTG were considered. These additional areas of increased activity were located in adjacent cortex, clearly separate from the primary auditory cortex. These regions have previously been designated as the *association auditory cortex* and their activation here may be an indicator of functional tone discrimination. Although the increased activation of the association cortex to stepped tones was not statistically different

from that seen in response to pure tone stimuli, a definite trend was observed (Fig 9). A nonsignificant trend of dominant (left) hemisphere activation in the association cortex was also observed (Fig 9).

#### Auditory Cortex: Text Listening

As with stepwise tone delivery, listening to text also resulted in activation of not only the primary auditory cortex but also of the surrounding areas of association cortex. The area of activation in both the TTG (Fig 8) and the association cortex (Fig 9) was significantly greater than that seen with any other task ( $P < .05$ ) (Fig 10), including the stepped frequencies. A graded activation response was noted with text listening, which activated more association cortex than stepped tones, which in turn activated more than separate pure tones. As with the stepped tones stimulus, a nonsignificant trend toward activation of the dominant (left) hemisphere association cortex was observed in response to listening to text (Fig 9).

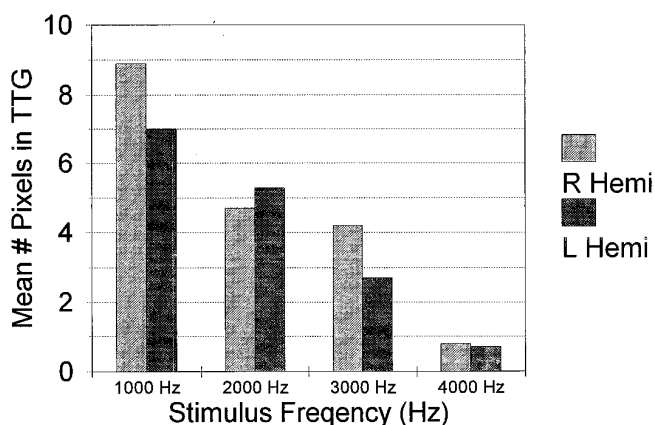


Fig 5. Mean number of pixels activated within the right and left TTG in response to a variable range of frequencies from 1000 Hz to 4000 Hz ( $n = 9$ ). Note that low-frequency pure tones result in significantly increased activation bilaterally within the TTG compared with higher frequency pure tones.

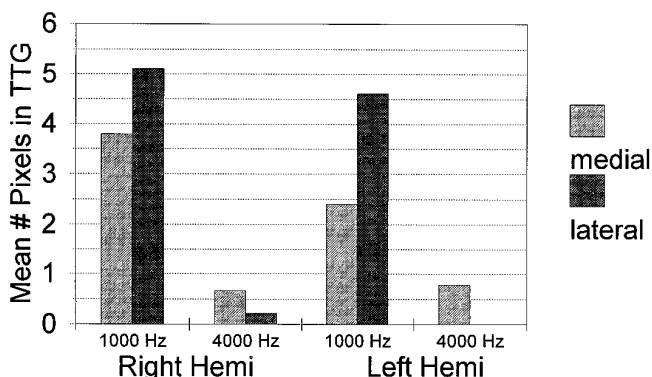


Fig 6. Right and left TTG pixel activation displayed separately in response to 1000-Hz and 4000-Hz pure tone stimuli ( $n = 9$ ). Anatomic division of the TTG into medial and lateral segments shows a greater proportion of cortical activation laterally in response to lower frequency pure tones, whereas higher frequency pure tones resulted in a proportionally greater medial activation.

## Discussion

The auditory cortex has been the subject of numerous investigations in both humans and animals. In 1937, Kornmüller (10) mapped the auditory cortex in cats by recording electrical responses to acoustical stimulation. Further pathologic and animal studies showed the complexity of the auditory cortex microstructure and its processing of auditory stimuli (11–13). In 1968, Braak (14) recorded human electrical responses to auditory stimuli in the lateral temporal lobe. Subsequently, efforts by Ceesia and others (15–17) have obtained electrical responses directly from the human primary auditory cortex within the TTG (Heschl's gyrus) as well as from the posterosuperior temporal lobe and frontoparietal opercular regions. These lat-

ter areas of cortex have since been shown to play a role in associative auditory processing in animal species and humans (18–20).

More recently, newer imaging techniques, such as PET and functional MR imaging, have been used to study cerebral activation in response to specific motor and sensory stimuli in vivo (21–28). Responses of the auditory cortex (ie, changes in rCBF) during a variety of listening tasks, including rhythm sequences (29), tone sequences (30), single words (31), word lists, and tone intensity discrimination (32), have been evaluated with PET. However, these studies were limited by their inability to measure rCBF within the deep cortical regions (ie, TTG). The functional organization of the primary auditory cortex and surrounding areas of associative auditory cortex have since been studied by others (33–37).

The feasibility of using functional MR imaging to evaluate the primary auditory cortex has recently been described (7–9). The superior temporal gyrus is activated in the perception and processing of auditory stimuli. Specifically, cortical activation from within the superior temporal gyrus has been described in response to nonspeech noise, meaningless speech noise, single words, pure tone stimulation, and text reading.

The results described in our investigation further substantiate the feasibility and usefulness of functional MR imaging in the evaluation of the complex functional organization within the primary and association auditory cortex. Activation localized to the TTG was greater in response to lower frequency tones than to higher frequency tones. While it is possible that this result was a function of our experimental conditions (ie, ambient scanner noise), there was no difference in detection thresholds across the range of pure tone frequencies delivered to our volunteers, and therefore all tones were delivered at a constant intensity level. Thus, this finding could suggest an increased sensitivity of the primary auditory cortex to lower frequency stimuli, or it may indicate less efficient processing of low-frequency tones with a subsequently increased level of vascular recruitment. The preferential response of individual cochlear nerve cells to a specific sound frequency, known as *characteristic frequencies*, has been described (38). This spatial organization within the cochlear apparatus enables appropriate responses to the full audible range of frequencies

Fig 7. Illustration of activation distribution within the TTG in response to 1000 Hz and 4000 Hz pure tones. Note that a 1000-Hz tone activates a larger area of cortex with lateral TTG predominance, whereas activation in response to a 4000-Hz tone is relatively confined to the medial aspect of the gyrus.

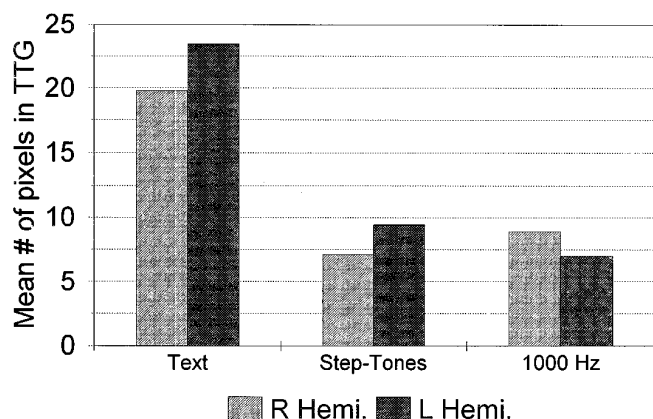
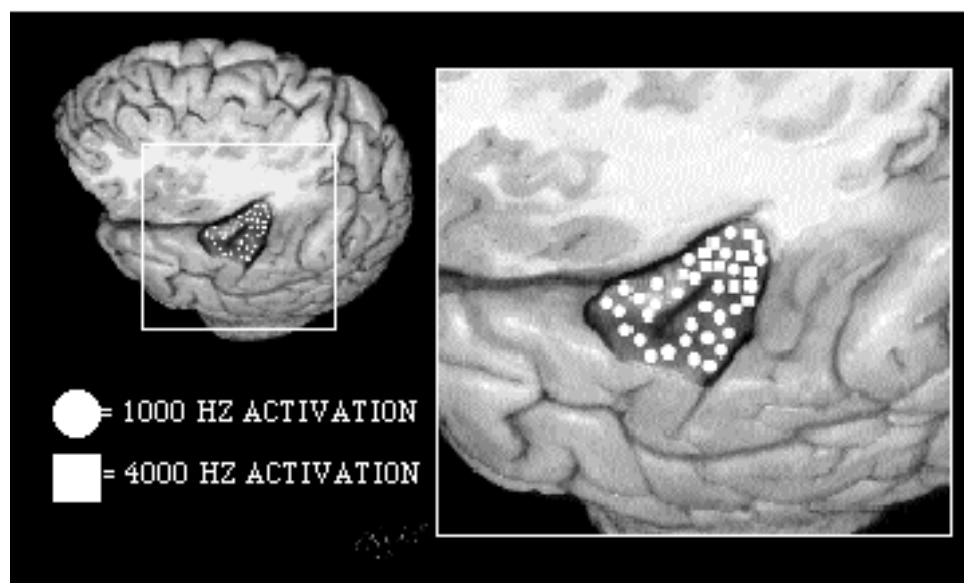


Fig 8. Mean number of pixels activated within the right and left TTG in response to variable task stimulation. Note that while no significant difference in activation is seen between 1000-Hz pure tones ( $n = 9$ ) and stepped tones ( $n = 7$ ), listening to text ( $n = 9$ ) results in significantly increased activity within both the right and left TTG relative to the other auditory tasks.

perceived by humans (20 to 20 000 Hz). While it is known that the ear has an increased sensitivity to sounds between 500 and 8000 Hz, no preferential cortical response to specific frequencies within this range has yet been described in humans. The mechanism and significance of this greater activation with low-frequency tones seen in our investigation are uncertain and remain to be elucidated. However, our findings indicate that future research and clinical evaluation into the primary auditory cortex using similar methods would be optimized at frequencies near 1000 Hz.

Our results show a tonotopic relationship within the TTG, supporting early histologic,

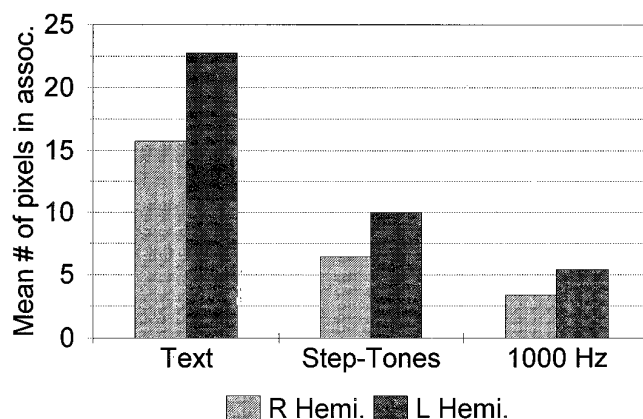


Fig 9. Mean number of pixels activated within the right and left auditory association cortex in response to three separate auditory stimuli. Note that listening to text ( $n = 9$ ) results in significantly increased activity within both hemispheres relative to either stepped tones ( $n = 7$ ) or to a 1000-Hz pure tone ( $n = 9$ ). While the difference in association cortex activation between stepped tones and a 1000-Hz tone is not significant, a definite trend toward increased activity with stepped tones stimulation is noted. Additionally, a trend toward asymmetric activation within the left (dominant) hemispheric association cortex is shown.

evoked potential, magnetoencephalographic, and PET studies (15, 39–41). We found predominant activation within the lateral portion of the TTG with lower frequency tones (1000 Hz) and a relative confinement of activity to the medial portion of Heschl's gyrus upon stimulation with higher frequency tones (4000 Hz). The structural tonotopic array of neurons within the cochlear apparatus is maintained in the complex neural pathways of the central auditory centers (42). This tonotopic organization was described by Woolsey et al (43) in 1943 and

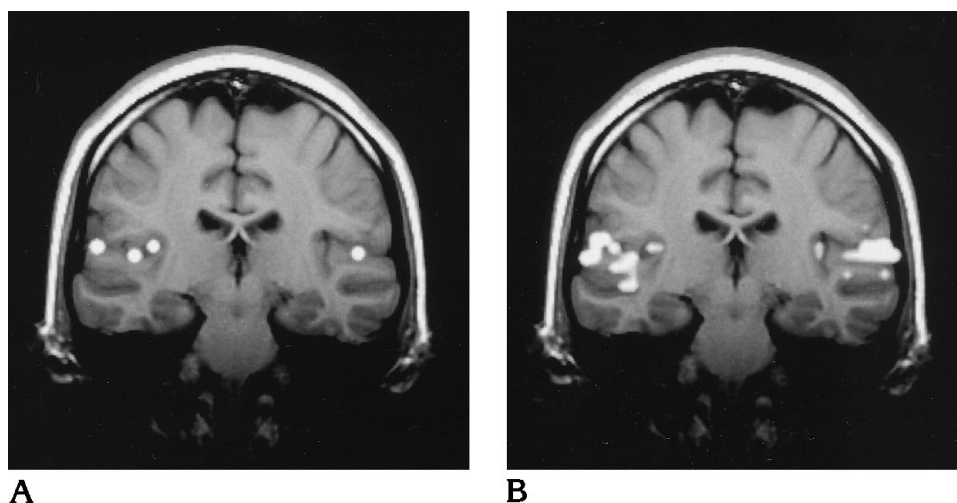


Fig 10. A, Coronal image obtained through the TTG after activation with a 1000-Hz pure tone delivered at 50 dB SL. Note the activation localized primarily to the TTG bilaterally.

B, Coronal image from the same subject obtained in an identical location after listening to text. Significantly increased activation is noted not only within the region of the TTG but also within the surrounding association cortex.

has also been demonstrated in recent PET studies (21). Functional MR imaging, with its ability to detect this relationship, provides an additional noninvasive means for probing the functional microstructure of the primary auditory cortex and should have even greater potential as higher resolution fast imaging techniques are developed. These findings suggest that pathologic states affecting various frequency responses within the auditory centers may be studied in the future with functional MR imaging.

Larger areas of activation were also noted within the primary auditory cortex in response to auditory stimuli of increasing intensities. To date, this relationship has not been demonstrated with PET imaging. Future technical refinements in functional MR imaging may further improve temporal and spatial resolution and allow for even greater definition of sound amplitude response within the primary auditory cortex. The ear is not equally sensitive to all frequencies. Greater intensities are required to reach threshold at the lower and higher ends of the frequency scale than in the medium range (500 to 8000 Hz). However, the fact that less cortical activation was detected with the lower intensity tones most likely reflects the threshold criteria used in our study rather than a true lack of activation from such intensities. We investigated a limited range of sound intensities (20 dB SL and 50 dB SL) and frequencies (1000 Hz). The extent to which the combined effects of frequency and intensity variables affect activation is an additional subject for further research with the use of similar functional MR imaging methodology.

The sequencing of four tones produced greater activation than did the individual tones presented separately. In particular, greater activation was noted in the auditory association cortex with the presentation of the stepped frequency tone series than with the pure tone stimulus. The presentation of spoken text showed even greater activation outside the primary auditory cortex than did stepped tones. Our results are in agreement with previous studies using auditory evoked potentials, which showed greater auditory cortical responses from modulated tones than from steady tones (44). Additionally, previous PET and functional MR imaging studies have shown activation localized to the TTG in response to nonspeech (white) noise, whereas more widespread cortical activation has been detected in response to speech (8, 45). Tone stimuli delivered rhythmically also resulted in rCBF increases in auditory association areas within the superior temporal gyrus (29). Findings in our study offer further evidence to support the hypothesis that the association cortex is active in tone discrimination. A greater variety of frequencies should be studied. Additionally, studying activation patterns in musicians and nonmusicians may help us understand the organization of auditory processing.

The finding that spoken text results in greater activation in areas of association cortex than that produced by nonverbal cues may be attributed to the cognitive processing required in the analysis of spoken words (21, 44, 46). In theory, then, the finding may be due to the activation of additional areas of cortex known as the



*semantic system* (47–50), which requires process activation and implementation of previously learned meaningful phenomes, word groups, and associations. These cognitive processes may occur without the subject's awareness (51, 52). Another explanation for these findings is that the modulation present within spoken text is processed at a higher level within the auditory association cortex than are non-word stimuli. Future investigations of the patterns of brain activation in response to verbal and nonverbal stimuli may illuminate the cognitive pathways used in the processing of semantic stimuli.

Several authors have described relationships between monaural or binaural stimulation as it relates to sidedness of cortical stimulation. Results in this area have been inconsistent from investigation to investigation. Some reports show increased contralateral temporal lobe activation with monaural stimulation (17–27, 29–33, 35, 53, 54). Nishizawa et al (55) showed a left hemispheric activation dominance in response to speech stimuli and a right-sided dominance with nonverbal stimuli. Other investigators, using both PET and functional MR imaging techniques, have shown no significant difference in symmetry of cerebral activation (7, 34). Our results agree with these later findings in that they showed no significant asymmetry in TTG activation, although a trend toward left-dominant association cortex activation was seen with the presentation of increasingly complex stimuli. Nevertheless, the reason for these discrepancies in the literature remains unknown. Symmetry of cerebral activation may in part be determined by stimulus content and/or mode of presentation. Additionally, the variability of imaging techniques in terms of their capacity to effectively quantitate activation magnitude may play a role in contributing to these apparent inconsistencies. Future work should help elucidate the various factors affecting symmetry of brain activation.

Our results demonstrate the usefulness of functional MR imaging in investigating the functional anatomy and processing pathways of the primary auditory cortex. Future studies should produce higher spatial resolution and better define the optimal methods for probing the auditory cortex. The clinical application of these techniques should be considered. Theoretical uses include differentiation of functional from nonorganic hearing loss and central from pe-

ripheral hearing loss. Additionally, functional MR imaging may prove useful in preoperative testing of cochlear implant patients. Since this imaging technique avoids the subjectivity inherent in audiometric testing, it may also prove useful in the evaluation of psychogenic auditory disorders.

In conclusion, we have shown the feasibility of using functional MR imaging to assess the functional organization of the primary auditory cortex. With the use of simple auditory stimuli, we showed greater primary auditory cortex activation in response to tones of increasing intensity. Additionally, increased activation of the primary auditory cortex to tones of lower frequency (~1000 Hz) was shown, as was the tonotopic organization within the primary auditory cortex. Areas of activation were described outside the primary auditory cortex within regions of the auditory association cortex in response to graded/stepwise frequency tones and spoken text. Future investigations are expected to produce refinements in technique and further information regarding the functional organization of the primary auditory cortex.

## Acknowledgment

We thank Jane Harmeyer for her assistance.

## References

1. Bandettini PA, Wong EC, Hinks RS, Tikofsky RS, Hyde HS. Time course EPI of human brain function during task activation. *Magn Reson Med* 1992;25:390–397
2. Kwong KK, Belliveau JW, Chesler DA, et al. Dynamic magnetic resonance imaging of human brain activity during primary sensory stimulation. *Proc Natl Acad Sci U S A* 1992;89:5675–5679
3. Belliveau JW, Kennedy DN, McKinstry RC, et al. Functional mapping of the human visual cortex by magnetic resonance imaging. *Science* 1991;254:716–719
4. Menon RS, Ogawa S, Kim S-G, et al. Functional brain mapping using magnetic resonance imaging: signal changes accompanying visual stimulation. *Invest Radiol* 1992;27(Suppl 2):S47–S53
5. Belliveau JW, Kwong KK, Kennedy DN, et al. Magnetic resonance imaging mapping of brain function: human visual cortex. *Invest Radiol* 1992;27(Suppl 2):S59–S65
6. Yetkin FZ, Mueller WM, Hammeke TA, et al. Functional magnetic resonance imaging mapping of the sensorimotor cortex with tactile stimulation. *Neurosurgery* 1995;36:921–925
7. Binder JR, Rao SM, Hammeke TA, et al. Functional magnetic resonance imaging of human auditory cortex. *Ann Neurol* 1994;35:662–672
8. Binder JR, Rao SM, Hammeke TA, et al. Effects of stimulus rate on signal response during functional magnetic resonance imaging of auditory cortex. *Cogn Brain Res* 1994;2:31–38
9. Millen SJ, Houghton VM, Yetkin FZ. Functional magnetic resonance imaging of the central auditory pathway following speech and pure-tone stimuli. *Laryngoscope* 1995;105:1305–1310

10. Kornmüller AE. Lokalisationslehre Odor Ganshelt Des Zentralnervensystems. *Neurol u Psychiatr* 1937;158:244–246
11. Braak H. The pigment architecture of the human temporal lobe. *Anat Embryol* 1978;154:213–240
12. Galaburda A, Sanides F. Cytoarchitectonic organization of the human auditory cortex. *J Comp Neurol* 1980;190:597–610
13. Morel A, Kaas JH. Subdivisions and connections of auditory cortex in owl monkeys. *J Comp Neurol* 1992;318:27–63
14. Braak E. Ultrastructure of the small pigmented stellate cell in lamina II of the human isocortex [in German]. *Verh Anat Ges* 1977;71:949–952
15. Cellesia GG. Organization of auditory cortical areas in man. *Brain* 1976;99:403–414
16. Cellesia GG, Puletti F. Auditory cortical areas of man. *Neurology* 1969;19:211–219
17. Liegeois-Chauvel C, Musolino A, Chauvel P. Localization of the primary auditory area in man. *Brain* 1991;114:139–153
18. Brugge JF. Auditory cortex in the primate. In: Woolsey CN, ed. *Cortical Sensory Organization. Multiple Auditory Areas*. Clifton, NJ: Humana Press; 1982;3
19. Imig TJ, Reale RA, Brugge JF. The auditory cortex. Patterns of corticocortical projections related to physiological maps in the cat. In: Woolsey CN, ed. *Cortical Sensory Organization. Multiple Auditory Areas*. Clifton, NJ: Humana Press; 1982;3
20. Creutzfeldt O, Ojemann G, Lettich. Single neuron activity in the right and left human temporal lobe during listening and speaking. In: Engel J Jr, ed. *Fundamental Mechanisms of Human Brain Function*. New York, NY: Raven Press; 1987:69–81
21. Lauter JL, Herscovitch P, Formby C, et al. Tonotopic organization in human auditory cortex revealed by positron emission tomography. *Hear Res* 1985;20:199–205
22. Roland PE, Skinhoj E. Focal activation of the cerebral cortex during visual discrimination in man. *Brain Res* 1981;222:166–171
23. Price C, Wise R, Ramsay S, et al. Regional response differences within the human auditory cortex when listening to words. *Neurosci Lett* 1992;146:179–182
24. Fox PT, Raichle ME. Stimulus rate dependence of regional cerebral blood flow in human striate cortex, demonstrated by positron emission tomography. *J Neurophysiol* 1984;51:1109–1120
25. Fox PT, Raichle ME. Stimulus rate determines regional brain blood flow in striate cortex. *Ann Neurol* 1985;17:303–305
26. Mazziotta JC, Phelps ME, Carson RE, et al. Tomographic mapping of human cerebral metabolism: subcortical responses to auditory and visual stimulation. *Neurology* 1984;34:825–828
27. Bartlett EJ, Brown JW, Wolf AP, et al. Correlation between glucose metabolic rates in brain regions of healthy male adults at rest and during language stimulation. *Brain Lang* 1987;32:1–18
28. Rao SM, Binder JR, Bandettini PA, et al. Functional magnetic resonance imaging of complex human movements. *Neurology* 1993;43:2311–2318
29. Roland PE, Skinhoj E, Lassen NA. Focal activations of human cerebral cortex during auditory discrimination. *J Neurophysiol* 1981;45:1139–1151
30. Roland PE, Larsen B, Skinhoj E, et al. Regional cerebral blood flow increase due to treatment of somatosensory and auditory information in man. In: Meyer JS, Lechner H, Reivich M, eds. *Cerebral Vascular Disease*. Amsterdam, the Netherlands: Excerpta Medica; 1974:540–541
31. Larsen B, Skinhoj E, Soh K, et al. The pattern of cortical activity provoked by listening and speech revealed by rCBF measurements. In: Ingvar DH, Lassen NA, eds. *Cerebral Function Metabolism and Circulation*. Copenhagen, Denmark: Munksgaard; 1975;56:268–269
32. Knopman DS, Ruben AB, Klassen AC, et al. Regional cerebral blood flow patterns during verbal and non-verbal auditory activation. *Brain Lang* 1980;9:93–112
33. Greenberg JH, Reivich M, Alavi A, et al. Metabolic mapping of functional activity in human subjects with the [<sup>18</sup>F]fluorodeoxyglucose technique. *Science* 1981;212:678–680
34. Mazziotta JC, Phelps ME, Carson RE, et al. Tomographic mapping of human cerebral metabolism: auditory stimulation. *Neurology* 1982;32:921–937
35. Greenberg JH, Reivich M, Alavi A, et al. Metabolic mapping of functional activity in human subjects with the [<sup>18</sup>F]fluorodeoxyglucose technique. *Science* 1981;212:678–680
36. Reivich M, Greenberg J, Alavi A, et al. The use of the 18F-fluorodeoxyglucose technique for mapping of functional neural pathways in man. *Acta Neurol Scand* 1979;72(Suppl):198–199
37. Petersen SE, Fox PT, Posner MI, et al. Positron emission tomographic studies of the cortical anatomy of single-word processing. *Nature* 1988;331:585–589
38. Liberman MC. The cochlea frequency map for the cat: labeling auditory-nerve fibers of known characteristic frequency. *J Acoust Soc Am* 1982;72:1441
39. Roland PE. Language. In: Roland PE. *Brain Activation*. New York, NY: Wiley-Liss; 1993:158–163
40. Liegeois-Chauvel C, Musolino A, Badier JM, Marquis P, Chauvel P. Evoked potentials recorded from the auditory cortex in man: evaluation and topography of the middle latency components. *Electroencephalogr Clin Neurophysiol* 1994;92:204–214
41. Romani GL, Kaufman L. Tonotopic organization of the human auditory cortex. *Science* 1982;216:1339–1340
42. Brugge JF. Neurophysiology of the central auditory and vestibular systems. In: Paparella MM. *Otolaryngology*. Philadelphia, Pa: Saunders; 1991;1:281–301
43. Woolsey CN, Marshall WH, Baird P. Note on organization of tactile sensory area of cerebral cortex of chimpanzee. *J Neurophysiol* 1943;6:287–291
44. Zatorre RJ, Evans AC, Meyer E, et al. Lateralization of phonetic and pitch discrimination in speech processing. *Science* 1992;256:846–849
45. Momose T, Sasaki Y, Nishikawa J, et al. Functional brain studies with H<sub>2</sub>(15)O-PET: Strategies and problems for approaching higher brain functions with H<sub>2</sub>(15)O-PET. *Radiat Med* 1991;9:122–126
46. Wise R, Chollet F, Hadar U, et al. Distribution of cortical neural networks involved in word comprehension and word retrieval. *Brain* 1991;114:1803–1817
47. Sidman M. Reading and auditory-visual equivalences. *J Speech Hear Res* 1971;14:5–13
48. Tulving E. Episodic and semantic memory. In: Tulving E, Donaldson W, eds. *Organization of Memory*. New York, NY: Academic Press; 1972:381–403
49. Rosch E. Cognitive representation of semantic categories. *J Exp Psychol Gen* 1975;104:192–233
50. Shallice T. Specialisation within the semantic system. *Cogn Neuropsychol* 1988;5:133–142
51. Carr TH, McCauley C, Sperber RD, et al. Words, pictures, and priming: on semantic activation, conscious identification, and the automaticity of information processing. *J Exp Psychol Hum Percept Perform* 1982;8:757–777
52. Marcel AJ. Conscious and unconscious perception: experiments on visual masking and word recognition. *Cogn Psychol* 1983;15:197–237
53. Nishizawa Y, Olsen TS, Larsen B, et al. Left-right cortical asymmetries of regional cerebral blood flow during listening to words. *J Neurophysiol* 1982;48:458–466

54. Kushner M, Schwartz R, Alavi A, et al. Cerebral activation by nonmeaningful monaural verbal auditory stimulation. *Brain Res* 1987;409:79-87
55. Nishizawa Y, Olson TS, Larsen B, et al. Left-right cortical asymmetries of regional cerebral blood flow during listening to words. *J Neurophysiol* 1982;48:458-465
56. Duvernoy HM. *The Human Brain: Surface, Three-Dimensional Sectional Anatomy and MRI*. New York, NY: Springer-Verlag; 1991

**Please see the Commentary on page 621 in this issue.**