



## Discover Generics

Cost-Effective CT & MRI Contrast Agents



FRESENIUS  
KABI

WATCH VIDEO

# AJNR

## **Malignant plasmacytoma appearing as invasive paranasal sinus disease after cardiac transplantation.**

G S Kramer and R A Gatenby

*AJNR Am J Neuroradiol* 1996, 17 (8) 1582-1584

<http://www.ajnr.org/content/17/8/1582>

This information is current as  
of June 24, 2025.

---

# Malignant Plasmacytoma Appearing as Invasive Paranasal Sinus Disease after Cardiac Transplantation

Gary S. Kramer and Robert A. Gatenby

**Summary:** Invasive plasmacytoma appearing as a mass in the paranasal sinuses developed in two patients after cardiac transplantation. Radiographic findings included a sinus mass with bony invasion and expansion. The findings were radiographically indistinguishable from common malignant neoplasms and aggressive infectious processes. Malignant plasmacytoma should be considered in the differential diagnosis of invasive paranasal sinus masses in chronically immunosuppressed patients.

**Index terms:** Immune deficiency; Paranasal sinuses, neoplasms; Transplants

Patients who receive organ transplants require chronic immunosuppression and are at increased risk for a variety of infections and malignant processes. The rate of occurrence of malignant tumors (approximately 5% to 6%) is 100 times greater in patients receiving immunosuppressive therapy than in the population at large. Tumor types have included squamous cell carcinomas of the skin, in situ carcinomas of the uterine cervix, various lymphomas, and Kaposi sarcomas. Less common malignant lesions in this population include renal cell carcinoma, hepatoma, primary bronchogenic carcinoma, and various sarcomas (1, 2). When an invasive lesion in the maxillary sinus is discovered in transplant patients, infection, particularly from *Mucoraceae*, *Aspergillus*, and *Pseudomonas* organisms, is a common causative factor (3). Tumors included in the differential diagnosis are usually squamous cell carcinoma, since it is the most common sinus tumor in nonimmunosuppressed patients, and lymphoma, because it is the most common overall tumor in posttransplant patients.

Plasma cell malignancies are a rare complication of transplantation (4, 5). We describe two patients in whom plasma cell malignancies developed after cardiac transplantation. In both

cases, an extramedullary plasmacytoma appeared as an invasive maxillary sinus lesion.

## Case 1

A 54-year-old man was admitted 4 years after cardiac transplantation with recurrent epistaxis. His cardiovascular status had remained stable on azathioprine, cyclosporine, and prednisone. A CT scan (Fig 1) showed a large mass in the left maxillary sinus with associated partial destruction of the medial wall in the region of the middle turbinate and maxillary ethmoid plate, and extension into the nasal cavity and ethmoidal sinus. There is also expansion with upward bowing of the orbital floor with a smaller area of expansion in the lower lateral wall of the sinus. There was no associated adenopathy. CT scans of the chest, abdomen, and pelvis showed no abnormality. Biopsy of the mass revealed poorly differentiated, malignant plasma cells. Immunohistochemical stains were positive for light  $\kappa$  chains and for plasma cell markers. Results of bone marrow aspirate and biopsy were normal, as were results of a serum protein electrophoresis and urine protein electrophoresis. Complete clinical and radiologic regression of the tumor was obtained with radiation therapy.

## Case 2

A 66-year-old man was admitted 5 years after cardiac transplantation with a painless lump in the retromolar region of the right maxilla. His medications included cyclosporine, azathioprine, and prednisone. A CT scan (Fig 2) showed a soft-tissue mass in the right maxillary sinus with destruction of the maxillary tuberosity. Biopsy findings showed malignant plasma cells. Results of bone marrow aspirate and biopsy also revealed malignant plasma cells.

## Discussion

The maxillary sinus lesions in both our patients were of similar appearance on CT scans. The first patient had a mass that completely opacified the maxillary sinus, invaded the me-

---

Received July 18, 1995; accepted after revision December 12.

From the Department of Diagnostic Imaging, Temple University Hospital, Broad and Ontario Streets, Philadelphia, PA 19140. Address reprint requests to Gary S. Kramer, MD.

AJNR 17:1582-1584, Sep 1996 0195-6108/96/1708-1582 © American Society of Neuroradiology

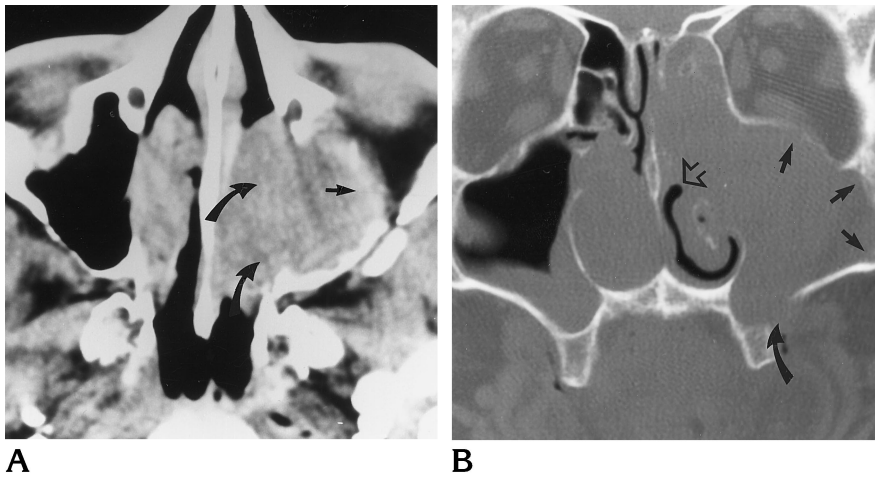


Fig 1. Fifty-four-year-old man with recurrent epistaxis 4 years after cardiac transplantation.

A, Axial CT scan shows a large soft-tissue mass in left maxillary sinus with bowing of the orbital floor (*straight arrow*) and invasion through the medial wall (*curved arrows*).

B, Coronal CT scan shows a large soft-tissue mass in maxillary sinus causing partial destruction of the inferior lateral wall (*curved arrow*) with associated expansion of the sinus (*straight arrows*). Furthermore, the tumor extends through the maxillary ethmoid plate into the ethmoidal sinus and also protrudes into the ostium and middle meatus (*open arrow*).

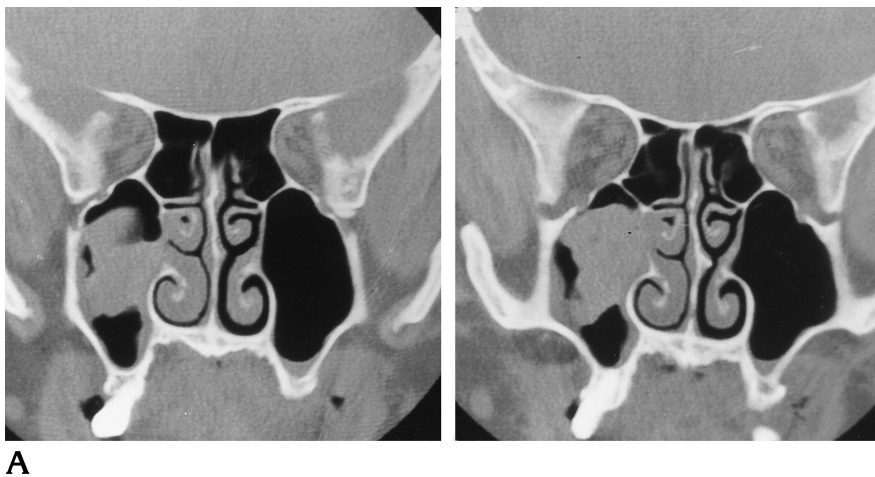
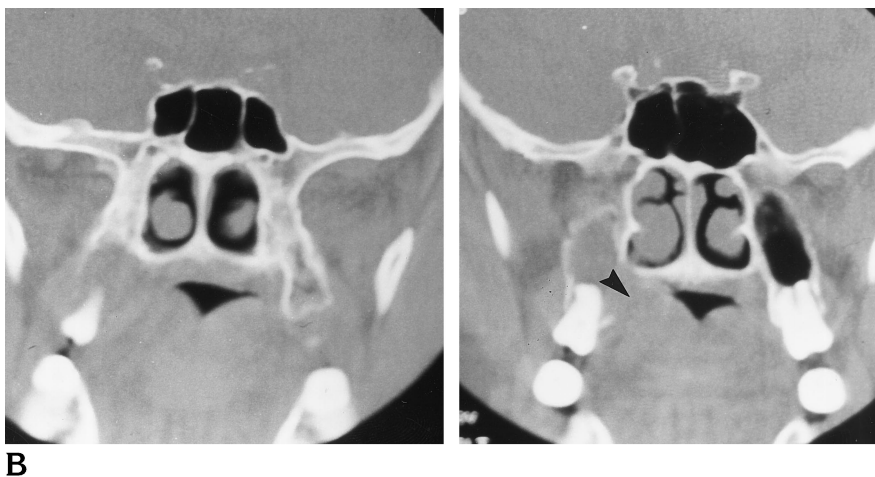


Fig 2. Sixty-six-year-old man with painless lump in the retromolar region of the right maxilla 5 years after cardiac transplantation. Coronal CT scans show a soft-tissue density in the right maxillary sinus with destruction of the maxillary tuberosity (*arrowhead*).



dial wall, and expanded the sinus. The mass exhibited some bony destruction and expansion, with extension into the nasal cavity. The second patient also had a maxillary sinus mass with bony destruction of the maxillary tuberosity.

Malignant neoplasms are severe complications of organ transplantation and immunosuppression. Among these patients, the rate of occurrence of malignant lesions ranges from 4% to 18% (average, 6%) (6). The most common lesions are squamous cell tumors of the skin and cervix, lymphoproliferative disorders, and Kaposi sarcomas. The lymphoproliferative disorders range from polymorphic reactive proliferations to malignant lymphomas. The overall frequency of lymphoproliferative disorders is approximately 2% (7).

Multiple myeloma is a rare posttransplant lymphoproliferative disorder. We found four reported cases of posttransplant myelomas, two of which followed cardiac transplantation. None of these cases involved the head and neck region.

In nonimmunosuppressed patients, squamous cell carcinoma is the most common tumor of the paranasal sinuses. Less common tumors include adenocarcinoma, adenoid cystic carcinoma, lymphoma (particularly in the setting of immunosuppression), esthesioneuroblastoma, inverted papilloma, and melanoma. Plasma cell tumors of the head and neck are ordinarily exceedingly rare.

In immunosuppressed patients, maxillary sinus lesions are frequently infectious in origin, particularly from such agents as *Mucoraceae*, *Aspergillus*, and *Pseudomonas* organisms. These aggressive infections can appear radio-

graphically much like neoplasms, and can cause bony destruction and soft-tissue invasion (8).

Although the pathogenesis of invasive paranasal sinus masses is limited, biopsy is always necessary to differentiate a malignant process from infection and to confirm the diagnosis.

These two cases of extramedullary plasmacytoma appearing in the maxillary sinus after cardiac transplantation expand the differential diagnosis in this patient group. Plasmacytoma should be considered a diagnostic possibility in a transplant patient who has an invasive mass in the paranasal sinuses.

## References

1. Penn I. Tumors after renal and cardiac transplantation. *Hematol Oncol Clin North Am* 1993;7:431-435
2. Fleming RH, Jennison SH, Naunheim KS. Primary bronchogenic carcinoma in the heart transplant recipient. *Ann Thorac Surg* 1994;57:1300-1301
3. Lebovics R. Diseases of the upper respiratory tract. In: Wilson JD, Braunwald E, Isselbacher KJ, et al, eds. *Harrison's Principles of Internal Medicine*. 12th ed. New York, NY: McGraw-Hill; 1991: 1096-1100
4. Chucrallah AE, Crown K, Rice LE, et al. Multimyeloma after cardiac transplantation: an unusual form of post transplant lymphoproliferative disorder. *Hum Pathol* 1994;25:541-545
5. Guerci AP, Burtin P, Mattei S, Lederlin P. Lymphoproliferative syndromes after cardiac transplant and treatment with cyclosporine. *Ann Med Interne (Paris)* 1992;143:155-159
6. Penn I. Neoplastic complications of transplantation. *Semin Respir Infect* 1993;8:233-239
7. Nalesnik MA, Jaffe R, Starzl TE, et al. The pathology of post-transplant lymphoproliferative disorders occurring in the setting of cyclosporin A: prednisone immunosuppression. *Am J Pathol* 1988;133:173-192
8. Anand UK, Azemar G, Griswold JA Jr. Intracranial complications of mucormycosis: an experimental model and clinical review. *Laryngoscope* 1992;102:656-662