



Providing Choice & Value

Generic CT and MRI Contrast Agents



**FRESENIUS
KABI**

CONTACT REP

AJNR

Balloon test occlusion of the internal carotid artery with hypotensive challenge.

S C Standard, A Ahuja, L R Guterman, T D Chavis, K J Gibbons, A P Barth and L N Hopkins

AJNR Am J Neuroradiol 1995, 16 (7) 1453-1458

<http://www.ajnr.org/content/16/7/1453>

This information is current as of July 31, 2025.

Balloon Test Occlusion of the Internal Carotid Artery with Hypotensive Challenge

Scott C. Standard, Arvind Ahuja, Lee R. Guterman, Tamerla D. Chavis, Kevin J. Gibbons, Adrienne P. Barth, and L. N. Hopkins

PURPOSE: To evaluate the usefulness of provocative testing with hypotensive challenge during balloon test occlusion of the internal carotid artery before carotid sacrifice and to correlate tolerance of balloon test occlusion with clinical outcome after carotid artery sacrifice. **METHODS:** Forty-seven consecutive cases of balloon test occlusions performed at our institution during the past 4 years were retrospectively reviewed. Occlusion was performed under normotensive conditions with distal perfusion of heparinized saline for 20 minutes, or until a deficit was perceived. If 20 minutes of normotension was tolerated, hypotension was induced to two thirds of mean arterial pressure for 20 minutes, or until a deficit was perceived. **RESULTS:** Of 47 patients, 4 (9%) had deficits at normotension. Of the remaining 43 patients, 9 (21%) had deficits at hypotension. One patient with a positive hypotensive test occlusion underwent carotid artery sacrifice after extracranial-intracranial bypass without sequelae. In one of the 19 patients who clinically tolerated test occlusion with hypotension and had carotid sacrifice (surgical ligation of the intracranial carotid artery), a mild embolic stroke developed, probably from the giant carotid wall aneurysm. This patient fully recovered; MR imaging showed mild changes consistent with emboli distal to the aneurysm. Symptomatic complications were noted in 2 (4%) patients, and asymptomatic arterial dissections were noted in 3 (6%) patients. **CONCLUSION:** Balloon test occlusion with hypotensive challenge is safe, economical, and greatly increases the sensitivity of balloon test occlusion. The predictive value of a negative test is high. However, to determine the test's specificity compared with quantitative imaging, controlled trials will be necessary.

Index terms: Interventional neuroradiology, provocative testing; Arteries, carotid, internal

AJNR Am J Neuroradiol 16:1453–1458, August 1995

Endovascular techniques for balloon test occlusion (BTO) of parent vessels have been developed to assess the vascular reserve of a particular vascular territory with neurologic monitoring before arterial sacrifice. The endovascular approach also offers the ability to perform permanent occlusion within surgically inaccessible portions of the carotid artery to reduce the column of thrombus that may propagate and subsequently embolize (1).

Abrupt carotid artery occlusion is associated with a neurologic ischemic rate of 49% for internal carotid artery (ICA) ligation and 28% for common carotid artery occlusion, as reported in the Cooperative Study of Intracranial Aneurysms and Subarachnoid Hemorrhage (2–4), whereas after a clinically tolerated test occlusion, the rate varies from 5% to 20% (5, 6). In an effort to reduce this morbidity, several investigators have used sophisticated measurements of cerebral blood flow, such as ^{99m}Tc hexamethylpropylene-amine oxime (HMPAO) and xenon-133 single-photon emission computed tomography (SPECT) (5, 7, 8), during BTO. However, these techniques require specialized equipment and add to the overall cost of patient treatment. Furthermore, although these techniques have further defined patients at highest and lowest risk for carotid artery occlusion and reduced the risk of stroke to 5% to 8%, they have

Received May 10, 1994; accepted after revision February 9, 1995.

Presented in part at the 32nd Annual Meeting of the American Society of Neuroradiology, Nashville, Tenn, May 1–7, 1994.

From the Department of Neurosurgery, State University of New York at Buffalo, School of Medicine and Biomedical Sciences.

Address reprint requests to L. N. Hopkins, MD, Department of Neurosurgery, 3 Gates Circle, Buffalo, NY 14209.

AJNR 16:1453–1458, Aug 1995 0195-6108/95/1607-1453

© American Society of Neuroradiology

failed to reliably identify patients with limited reserve (5, 7, 8). Recently, Origiano et al (9) reported a rate as high as 22% for delayed neurologic deficits after negative BTO with SPECT imaging. In addition, the need to transport patients with balloons in the ICA and to inflate and deflate balloons without constant fluoroscopic control may increase the risk of complications.

To identify those patients at highest risk for vascular compromise after carotid sacrifice, we developed a protocol for test occlusion of the internal carotid artery with the adjunct of hypotensive challenge to two thirds of mean arterial pressure. We retrospectively reviewed 47 consecutive cases of BTO from 1989 to the present and compared the test results with clinical outcome after carotid artery sacrifice.

Materials and Methods

Forty-seven patients (34 women and 13 men; 32 to 74 years old) were referred for BTO of the ICA from March 1989 to April 1994, and each patient was included in the study protocol. Diagnoses at the time of test occlusion were aneurysms (36 patients), intracranial tumors (5 patients), and head and neck carcinomas (6 patients). Pre-existing neurologic deficits of oculomotor nerve paresis were observed in 2 (4%) patients with intracranial aneurysms. Four of the patients with aneurysms and 2 of the patients with head and neck carcinoma had a history of cardiovascular or pulmonary disease.

Patients were admitted on the day of the procedure and received vigorous hydration therapy with normal saline (150 mL every hour for at least 4 hours). They were premedicated with dexamethazone (4 mg every 6 hours intravenously) and nimodipine (60 mg every 4 hours orally) for the cerebroprotective effect (10, 11). During test occlusion procedures, patients were maintained under neuroleptanalgesia with hydromorphone hydrochloride (1 to 3 mg every hour intravenously), or fentanyl (50 to 70 μ m every hour) and midazolam hydrochloride (2 to 4 mg every hour intravenously). A Foley catheter was placed for patient comfort and to monitor urinary output. Mean arterial pressure was transduced through a femoral cannula in 10 patients and with an automated blood pressure cuff (Dynamap, Johnson & Johnson Critikon, New Brunswick, NJ) in all 47 patients.

An 8F femoral introducer catheter was inserted, and cervical and cerebral angiography of both carotid arteries was performed. Superselective angiography also was performed as appropriate to evaluate complex aneurysms. All patients were systemically heparinized to maintain activated clotting times above 300 seconds (2 to 3 times baseline) using an intravenous bolus injection of 5000 U initially and additional boluses (1000 to 3000 U every hour intravenously) to maintain the targeted activated clotting time values. Selective catheterization of the appropriate

ICA was performed by flow direction of a Swan-Ganz balloon catheter (125 cm in length) in 43 patients and a nondetachable silicone balloon catheter (150 cm in length, 1.5-mm noninflated diameter) in 4 patients. The Swan-Ganz catheter was the preferred catheter unless it could not be flow directed into the appropriate location because of tortuous proximal vascular anatomy. The distal port of the Swan-Ganz catheter was perfused with heparinized saline (1 U/mL at 1 mL/min). The silicone balloon catheters do not have distal ports. Angiography was used to confirm carotid artery occlusion.

Tolerance to test occlusion was assessed by a detailed neurologic examination consisting of evaluation of cranial nerve function, muscle strength, and language ability every 5 minutes or when a deficit was perceived. A test occlusion was considered positive if any new neurologic deficit occurred, with the exception of decreased acuity in the ipsilateral eye. The latter resulted from perfusion of the distal port with saline solution in eight patients and resolved in all cases when the rate of saline infusion was decreased.

If the patient tolerated 20 minutes of normotension, hypotension was induced by the infusion of sodium nitroprusside (2.5 to 7.5 μ m/kg body weight per minute) or labetalol (total dose, 5 to 20 mg). After the mean arterial pressure was reduced to two thirds of baseline, hypotension was maintained for 20 minutes. The balloon then was deflated, and heparinization was reversed with intravenous protamine (1g protamine per 100 U heparin). The study was terminated immediately if a new neurologic deficit developed during test occlusion under normotensive or hypotensive conditions.

Permanent occlusion of the carotid artery was performed as a separate procedure with either Selverstone clamps, surgical ligation, detachable silicone balloons, or platinum coils. Surgical occlusion was performed on the cervical ICA. Endovascular occlusion was performed within the cavernous ICA as distally as possible while assuring stable positioning of the device. Test occlusion was not repeated at the time of permanent occlusion. Collateral supply was usually demonstrated from the contralateral ICA or vertebrobasilar system, but this did not influence the site or technique of occlusion after a negative test occlusion.

Results

Forty-seven BTOs of the ICA (22 right, 25 left) were performed. Forty-three (91%) of 47 patients tested with normotension and 34 (79%) of 43 patients tested with hypotension tolerated temporary occlusion. Four (9%) of 47 patients had deficits appearing within 4 to 10 minutes at normotension. Nine (21%) of 43 patients had deficits after induced hypotension. Deficits appeared from 12 to 20 minutes after the target mean arterial pressure was achieved. One of these patients underwent carotid artery sacrifice

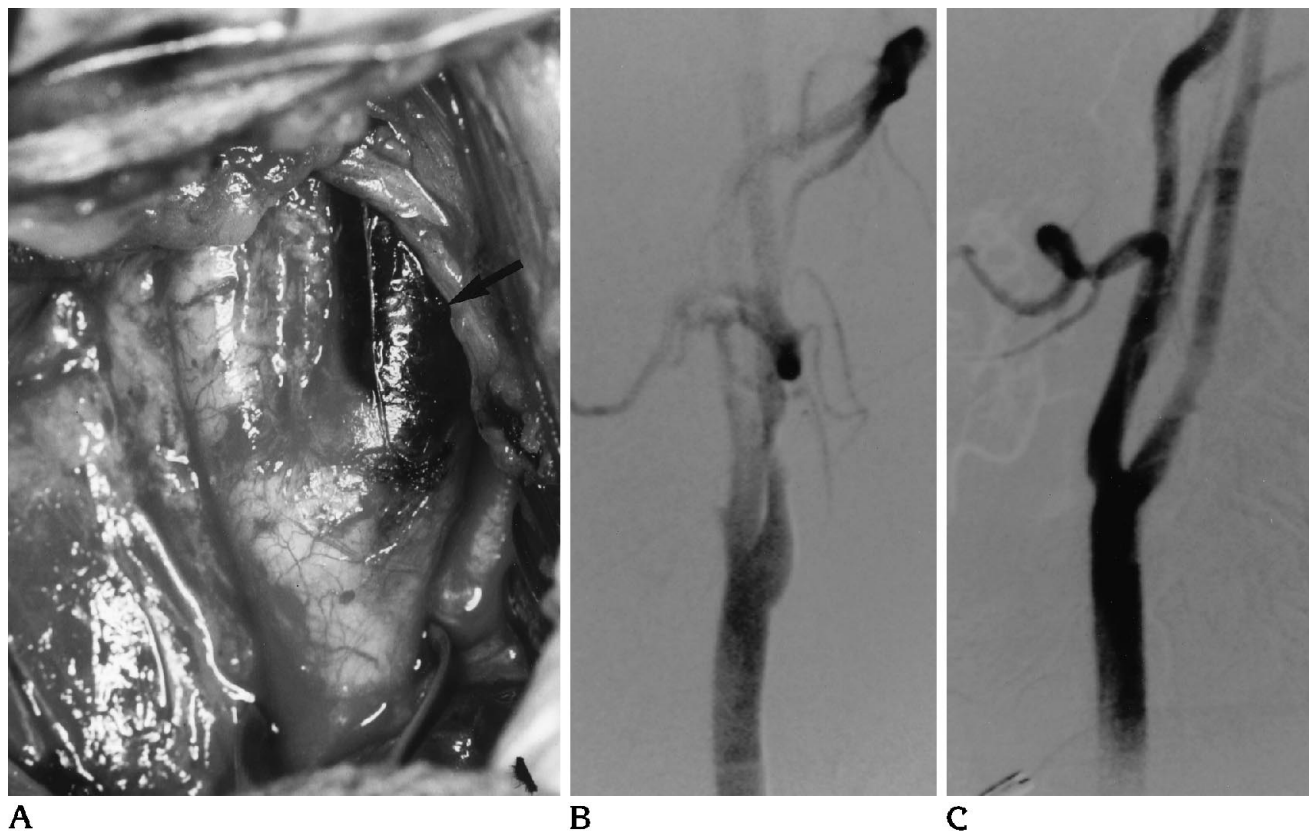


Fig 1. A 47-year-old man with a left medial sphenoid wing meningioma. BTO with hypotension was tolerated. At surgery, the carotid bifurcation was exposed for proximal vascular control, and an asymptomatic carotid artery dissection (A, oblique projection, arrow) was found. Carotid artery sacrifice was deemed unnecessary for complete tumor resection. Follow-up angiogram (B, lateral projection; C, oblique projection) revealed remodeling in the area of dissection without evidence of an intimal flap.

after extracranial-intracranial bypass without sequelae; the remaining patients have not required carotid sacrifice. One patient with a positive normotensive test occlusion had subsequent inadvertent occlusion of the right ICA with coils, resulting in hemispheric infarction and death.

Nineteen patients underwent intentional carotid artery sacrifice after a clinically tolerated hypotensive BTO with either detachable silicone balloons (12 patients), platinum coils (3 patients), Selverstone clamp (3 patients), or surgical ligation (1 patient). After a clinically tolerated hypotensive test occlusion in the single patient who had surgical ligation of the proximal intracranial carotid artery, a small infarction of the distal posterior division of the middle cerebral artery developed 5 months after the surgical procedure. Our clinical impression was of embolic ischemia because of the location of the infarction and the absence of hypotensive factors. Angiography was not performed, and the patient fully recovered. Magnetic resonance

imaging showed small lesions consistent with emboli distal to the aneurysm.

No cardiovascular events were noted during hypotensive test occlusion, and no procedural angina was identified. Two symptomatic complications of BTO occurred. One case of retroperitoneal hematoma resulted in transient post-procedural hypotension, and one case of distal middle cerebral artery embolization required superselective thrombolysis, which completely reversed the patient's neurologic deficit. Three asymptomatic complications of BTO were noted: a small carotid artery dissection (Fig 1) in two cases and a femoral artery dissection in another case.

Discussion

Abrupt carotid artery occlusion is associated with a neurologic ischemic rate of 49% for ICA ligation and 28% for common carotid artery occlusion, as reported in the Cooperative Study of Intracranial Aneurysms and Subarachnoid

Hemorrhage (2–4), although in the face of a clinically tolerated BTO, the rate varies from 5% to 20% (5, 6). Thus, a reliable and effective test is necessary to identify patients at risk for infarction after permanent carotid artery occlusion.

In an effort to reduce the morbidity of carotid artery occlusion, several investigators examined the use of quantitative blood flow imaging to determine the cerebrovascular reserve of the patient. ^{99m}Tc HMPAO and xenon-133 cerebral perfusion SPECT imaging (5, 7, 8) have been most widely used. Peterman et al (12) reported a series of 17 patients who tolerated BTO clinically, in which 2 patients had asymmetric perfusion deficits during BTO. One case is being followed. The other patient had significant electroencephalographic changes during temporary intraoperative occlusion. One of 15 patients with symmetric perfusion on SPECT imaging had a watershed infarct during profound hypotension at surgery. In a similar series of 11 patients, 5 patients had asymmetric changes in the SPECT study during test occlusion (13). Two of the patients with asymmetric perfusion studies underwent carotid artery sacrifice and experienced no ischemic sequelae. Therefore, the significance of SPECT perfusion asymmetry is unclear in these reports.

Eckard et al (14) reported a series of 29 patients in which 2 patients had asymmetric ^{99m}Tc HMPAO SPECT studies with no clinical changes during test occlusion. One of these patients had a delayed stroke (17 days) after ICA sacrifice related to an episode of hypotension. Interestingly, one patient with a symmetric cerebral blood flow study also had a delayed stroke after ICA sacrifice. The specificity of the test has not been determined. Yonas et al (15) noted that quantitative cerebral blood flow measurements may increase the sensitivity of the test occlusion by more exacting parameters but may exclude patients who might have tolerated carotid artery sacrifice.

These results are complemented by the work of Linskey et al (16) who promoted the use of stable xenon computed tomography to predict outcome after carotid artery occlusion. Their report categorized 43 patients into three groups based on quantitative blood flow measurements. Low-risk patients were defined as patients with blood flow greater than 30 mL/100 g per minute during BTO. High-risk patients were defined as those whose BTO failed clinically

because a neurologic deficit developed during 15 minutes of occlusion. High-risk patients underwent petrous-to-supraclinoid ICA bypass procedures before vessel sacrifice. The moderate-risk group was defined by clinical tolerance to BTO with perfusion changes on imaging. The risk of ICA occlusion in this group was thought to be significant, because these patients lacked vascular reserve. Two patients had cerebral infarctions after temporary or permanent vessel occlusion. In another patient, infarction was a complication of angiography. Two infarctions resulted from temporary occlusion of the parent vessel during surgery in 1 high-risk and 1 moderate-risk patient.

Therefore, quantitative perfusion imaging may define low-risk and high-risk groups for parent vessel sacrifice, particularly for ICA sacrifice. However, these methods have an undetermined specificity for the subset of patients who may be said to have limited vascular reserve and are at risk for stroke. Furthermore, quantitative blood flow imaging provides information regarding the hemodynamic profile at one moment and may not be an accurate indicator of the risk of infarction under a variety of hemodynamic conditions, particularly perioperative hypotension.

The addition of hypotensive challenge greatly increased the ability of test occlusion to predict tolerance to permanent carotid artery occlusion. In our series, no patient undergoing endovascular carotid sacrifice after tolerating carotid occlusion with hypotension had an acute or delayed neurologic deficit. The 1 patient who underwent surgical carotid ligation had a delayed deficit despite a negative test occlusion. If the entire group of 19 patients who underwent permanent carotid occlusion is considered, balloon test with hypotensive challenge correctly identified 18 (95%) patients who safely tolerated carotid occlusion after a negative test.

Origitano et al (9) recently reported that 4 (22%) of 18 patients undergoing endovascular carotid occlusion with negative normotensive BTO experienced delayed ischemic deficits. According to our data, the addition of hypotensive challenge lowers the rate to 5%.

The use of hypotensive challenge increased the number of patients identified with limited cerebrovascular reserve from 4 (9%) of 47 patients to 13 (28%) of 47 patients. Hypotensive challenge identified patients at risk for ischemia

during hypotensive stress and may signal a subgroup of patients who are at risk for hemodynamic infarction. In our subgroup of patients identified at risk for hemodynamic compromise by clinical intolerance to test occlusion, only 1 patient underwent subsequent carotid artery sacrifice, and this was accomplished after extracranial-intracranial bypass.

Clinical decisions were influenced in the patients in whom BTO failed with hypotension, so that the artery was preserved. In three patients with head and neck carcinomas, the carotid artery was preserved during en bloc dissection of the tumor mass. To date, no patient in this group has had a spontaneous carotid rupture. Detailed survival analysis is not presently available; however, the initial clinical outcome of these patients does not seem to have been adversely affected by this clinical decision. Four patients with carotid aneurysms had successful surgical clipping without parent vessel sacrifice. Two of these patients had transient cranial nerve deficits. Thus, although the true rate of false-positives is unknown, in the setting of a positive test, the patient may usually be successfully treated without parent vessel sacrifice. However, if parent vessel occlusion is contemplated during surgery in a patient with suspected limited cerebrovascular reserve, the surgeon should prepare for a bypass procedure.

If the adjunct of hypotensive challenge produces a test that is too sensitive and increases the number of false-positive results, a number of patients may be included in the high-risk category, despite an acceptable stroke risk. These patients may be needlessly subjected to revascularization procedures. However, the risk of revascularization in experienced hands is low (3% to 5%) and adds little to the overall risk of treatment of these patients (17). Such an additional risk may be warranted to prevent the devastating morbidity from hemispheric infarction.

Symptomatic complications of BTO occurred in 2 (4%) of our 47 patients. This compares favorably with a recent report of a 7% rate of transient ischemia during test occlusion (9). One patient in whom the balloon catheter did not allow distal perfusion with heparinized saline had a cerebral embolus requiring emergency thrombolysis. This patient's neurologic deficit has completely resolved. We now perfuse the distal artery meticulously with heparinized saline and monitor systemic heparinization closely.

Asymptomatic complications occurred in three patients. In two patients, asymptomatic carotid artery dissections developed after test occlusion. One dissection, which would have otherwise been unrecognized, was discovered during surgical exposure of the carotid artery for proximal control before craniotomy; another was discovered before balloon carotid artery sacrifice the day after test occlusion. Maintaining low inflation pressures in the balloon catheter might reduce the incidence of this complication. This complication may have been underestimated in some series, because follow-up angiography has not been routinely performed or has been performed on a delayed basis after intimal repair has occurred. In the third patient, an asymptomatic femoral artery dissection developed. We now use an 8F introducer sheath to minimize this complication.

The complications that occurred in this series represent an evolution of the technique and have been reduced in the most recent cases by meticulous angiographic technique. The development of a catheter that incorporates an easily navigable, compliant balloon and contains a distal port for perfusion with heparinized saline is needed to further enhance the safety of this procedure.

BTO with hypotensive challenge is useful in the evaluation of tolerance to carotid occlusion. Compared with presently available techniques, including radionuclide imaging, the procedure is easily performed and does not require additional imaging equipment. Furthermore, quantitative imaging determines blood flow only at a particular instant, which may or may not be a precise indicator of the hemodynamic profile of the hemisphere. To assess the relative specificity of test occlusion with hypotension as compared with quantitative imaging, controlled trials will be necessary.

Conclusions

Hypotensive challenge greatly increases the sensitivity of BTO of the carotid artery and is associated with a high positive predictive value for tolerance of permanent carotid artery occlusion. The predictive value of a negative test occlusion is 94% for all methods of carotid artery occlusion; but for the group undergoing endovascular occlusion of the ICA, the predictive value of a negative test approaches 100%. However, because the sensitivity of the test is

increased, its specificity may be decreased because of the addition of an unknown number of false-positive test occlusions. Patients testing false-positive may undergo unnecessary revascularization procedures. However, the additional morbidity and mortality associated with revascularization procedures is low and is preferable to the increased morbidity of hemispheric stroke associated with carotid occlusion. BTO of the carotid artery with hypotensive challenge is not associated with cardiovascular complications. However, the rate of angiographic complications is significant and may be reduced by improved catheter technology. BTO with hypotensive challenge is economical and may be performed at any site without expensive cerebral blood flow imaging equipment, and thus may be more cost effective than radionuclide imaging.

References

1. Berenstein A, Ransohoff J, Kupersmith M, Flamm E, Graeb D. Transvascular treatment of giant aneurysms of the cavernous carotid and vertebral arteries: functional investigation and embolization. *Surg Neurol* 1984;21:3-12
2. Nishioka H. Report on the Cooperative Study of Intracranial Aneurysms and Subarachnoid Hemorrhage, VIII, part I: results of the treatment of intracranial aneurysms by occlusion of the carotid artery in the neck. *J Neurosurg* 1966;25:660-682
3. Swearingen B, Heros RC. Common carotid occlusion for unclippable carotid aneurysms: an old but still effective operation. *Neurosurgery* 1987;21:288-295
4. Winn HR, Richardson AE, Jane JA. Late morbidity and mortality of common carotid ligation for posterior communicating aneurysms: a comparison to conservative treatment. *J Neurosurg* 1977;47:727-736
5. de Vries EJ, Sekhar LN, Horton JA, et al. A new method to predict safe resection of the internal carotid artery. *Laryngoscope* 1990;100:85-88
6. Gonzalez CF, Moret J. Balloon occlusion of the carotid artery prior to surgery for neck tumors. *AJNR Am J Neuroradiol* 1990;11:649-652
7. Erba SM, Horton JA, Latchaw RE, et al. Balloon test occlusion of the internal carotid artery with stable xenon/CT cerebral blood flow imaging. *AJNR Am J Neuroradiol* 1988;9:533-538
8. Jawad K, Miller JD, Wyper DJ, Rowan JO. Measurement of CBF and carotid artery pressure compared with cerebral angiography in assessing collateral blood supply after carotid ligation. *J Neurosurg* 1977;46:185-196
9. Origiano TC, Al-Mefty O, Leonetti JP, DeMonte F, Reichman OH. Vascular considerations and complications in cranial base surgery. *Neurosurgery* 1994;35:351-363
10. Braughler JM, Hall ED. Current application of "high-dose" steroid therapy for CNS injury: a pharmacological perspective. *J Neurosurg* 1985;62:806-810
11. Gelmers HJ, Gorter K, de Weerd CJ, Wiezer HJA. A controlled trial of nimodipine in acute ischemic stroke. *N Engl J Med* 1988;318:203-207
12. Peterman SB, Taylor A Jr, Hoffman JC Jr. Improved detection of cerebral hypoperfusion with internal carotid balloon test occlusion and 99mTc-HMPAO cerebral perfusion SPECT imaging. *AJNR Am J Neuroradiol* 1991;12:1035-1041
13. Monsein LH, Jeffery PJ, van Heerden BB, et al. Assessing adequacy of collateral circulation during balloon test occlusion of the internal carotid artery with 99mTc-HMPAO SPECT. *AJNR Am J Neuroradiol* 1991;12:1045-1051
14. Eckard DA, Purdy PD, Bonte FJ. Temporary balloon occlusion of the carotid artery combined with brain blood flow imaging as a test to predict tolerance prior to permanent carotid sacrifice. *AJNR Am J Neuroradiol* 1992;13:1565-1569
15. Yonas H, Linskey M, Johnson DW, et al. Internal carotid balloon test occlusion does require quantitative CBF (letter). *AJNR Am J Neuroradiol* 1992;13:1147-1152
16. Linskey ME, Sekhar LN, Horton JA, Hirsch WL Jr, Yonas H. Aneurysms of the intracavernous carotid artery: a multidisciplinary approach to treatment. *J Neurosurg* 1991;75:525-534
17. Serbinenko FA. Balloon catheterization and occlusion of major cerebral vessels. *J Neurosurg* 1974;41:125-145