



Discover Generics

Cost-Effective CT & MRI Contrast Agents



FRESENIUS
KABI

WATCH VIDEO

AJNR

MR of myelomatous meningitis.

D J Quint, R Levy and J C Krauss

AJNR Am J Neuroradiol 1995, 16 (6) 1316-1317

<http://www.ajnr.org/content/16/6/1316>

This information is current as
of June 24, 2025.

MR of Myelomatous Meningitis

Douglas J. Quint, Richard Levy, and John C. Krauss

Summary: In a 56-year-old woman with multiple myeloma involving the leptomeninges diffusely, MR of the spine showed multiple vertebral compression fractures and marked enhancement of the cauda equina region. Intracranial MR showed pathologic enhancement of the left third and fifth cranial nerves.

Index terms: Multiple myeloma; Meningitis

Central nervous system involvement by multiple myeloma can present as either a mass or a diffuse leptomeningeal process. We present a case of diffuse spinal canal leptomeningeal myelomatosis demonstrated on contrast-enhanced magnetic resonance (MR) imaging.

Case Report

A 56-year-old woman presented to the emergency room with a 1-week history of progressive bilateral lower extremity pain and weakness. She had a 7-year history of multiple myeloma (complicated by multiple thoracolumbar vertebral compression fractures), which had been successfully managed on an outpatient basis with occasional courses of melphalan/prednisone or cyclophosphamide/prednisone chemotherapy.

Physical examination revealed lower-extremity paraparesis and decreased rectal tone. Spine MR demonstrated multiple vertebral compression fractures (that had been demonstrated on previous plain radiographs) and marked enhancement of the cauda equina region (Fig 1). Subsequent lumbar puncture revealed plasma cells. This combination of findings was considered consistent with myelomatous meningitis. Intracranial MR demonstrated pathologic enhancement of the left third and fifth cranial nerves, also consistent with meningeal spread of myeloma.

Radiation therapy, intrathecal methotrexate, and prednisone therapy were instituted, but had to be stopped because of myelosuppression. The patient rapidly deteriorated and died 3 weeks after cessation of therapy.

Discussion

Involvement of the central nervous system by multiple myeloma can be attributed to direct invasion from contiguous involved bone or can be separate from bone involvement, presumably by hematogenous spread (1). Separate central nervous system lesions are believed to occur in fewer than 1% of patients with multiple myeloma (2). Central nervous system lesions can present as either diffuse leptomeningeal involvement or, more rarely, as extraaxial masses. In 1992, Leifer (1) reviewed 34 cases from the literature and reported 3 new cases of leptomeningeal involvement by multiple myeloma.

Our patient demonstrated dramatic enhancement of the distal thecal sac, including the cauda equina nerve roots, resulting from diffuse seeding of the leptomeninges/subarachnoid space by myeloma. Such enhancement is attributable to breakdown of the blood-nerve barrier (3). Although this MR finding is sensitive with respect to the presence of an abnormality, it is relatively nonspecific for the cause of the lesion: carcinomatous meningitis (primary central nervous system, breast, melanoma, lung, etc) (4), lymphomatous meningitis, arachnoiditis (eg, postoperative or secondary to intrathecal chemotherapy), Guillain-Barré syndrome (5), sarcoidosis, or infectious processes (6) such as parasitic, tuberculous, bacterial (including Lyme disease [7]), and viral (acquired immunodeficiency syndrome-related cytomegalovirus polyradiculomyelitis [8]) infections can have a similar appearance.

Therefore, in the appropriate clinical setting, dissemination of myeloma to the leptomeninges should be added to the differential diagnosis of diffuse enhancement of intradural, extramed-

Received March 8, 1994; accepted after revision May 20.

From the Departments of Radiology (D.J.Q., R.L.) and Internal Medicine (J.C.K.), University of Michigan Hospitals, Ann Arbor.

Address reprint requests to Douglas J. Quint, MD, Neuroradiology, B1D520B, Department of Radiology, Box 30, University of Michigan Hospitals, 1500 E Medical Center Dr, Ann Arbor, MI 48109-0030.

AJNR 16:1316-1317, Jun 1995 0195-6108/95/1606-1316 © American Society of Neuroradiology

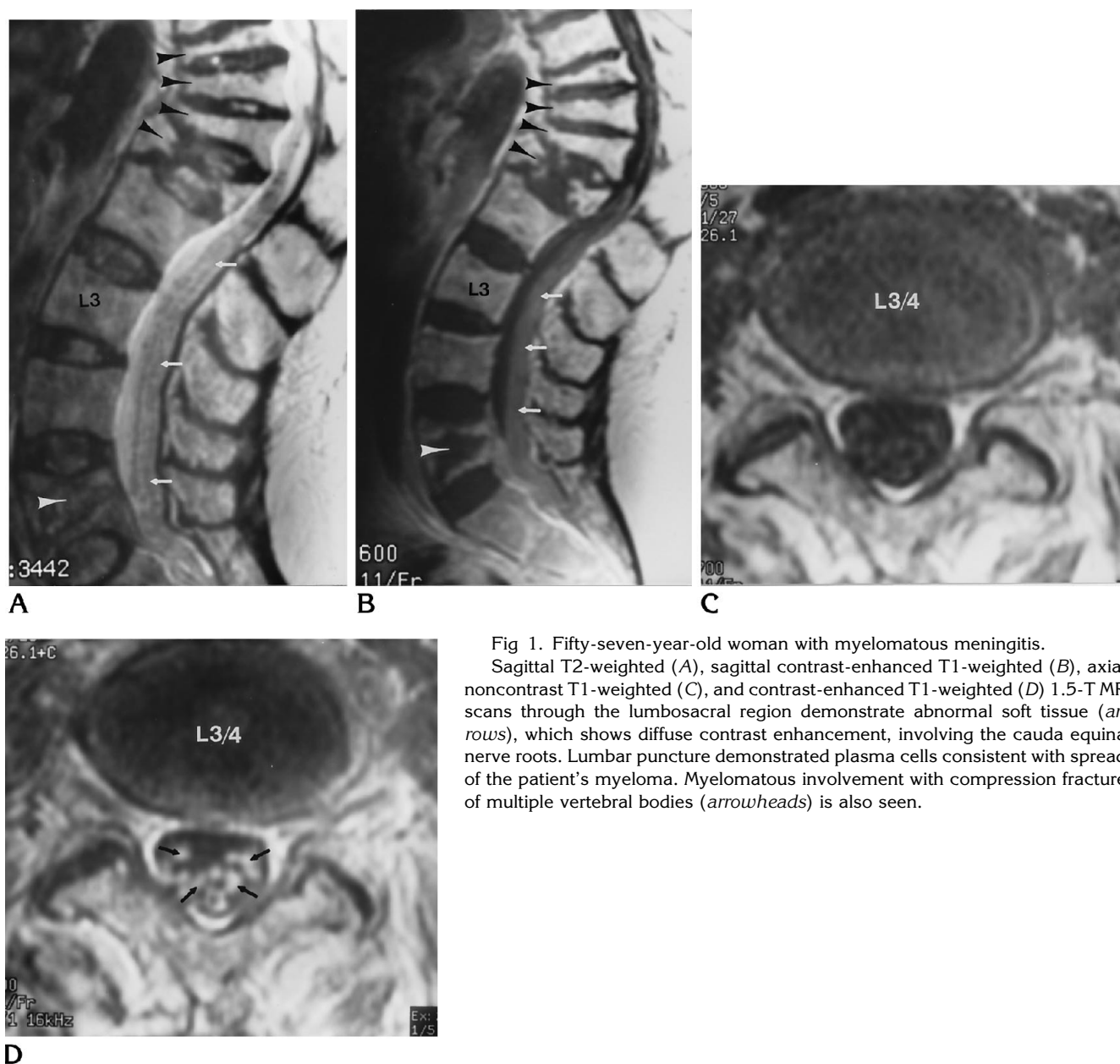


Fig 1. Fifty-seven-year-old woman with myelomatous meningitis.

Sagittal T2-weighted (A), sagittal contrast-enhanced T1-weighted (B), axial noncontrast T1-weighted (C), and contrast-enhanced T1-weighted (D) 1.5-T MR scans through the lumbosacral region demonstrate abnormal soft tissue (arrows), which shows diffuse contrast enhancement, involving the cauda equina nerve roots. Lumbar puncture demonstrated plasma cells consistent with spread of the patient's myeloma. Myelomatous involvement with compression fracture of multiple vertebral bodies (arrowheads) is also seen.

ullary structures on MR images. Cerebrospinal fluid analysis in these patients should always include studies to rule out both inflammatory/infectious processes and neoplastic processes.

References

1. Leifer D, Grabowski T, Simonian N, Demirjian ZN. Leptomeningeal myelomatosis presenting with mental status changes and other neurologic findings. *Cancer* 1992;70:1899-1904
2. Mouloupolous LA, Granfield CA, Dimopolous MA, Kim EE, Alexanian R, Libshitz HI. Extraosseous multiple myeloma: imaging features. *AJR Am J Roentgenol* 1993;161:1083-1087
3. Jinkins JR. MR of enhancing nerve roots in the unoperated lumbosacral spine. *AJNR Am J Neuroradiol* 1993;14:193-202
4. Watanabe M, Tanaka R, Takeda N. Correlation of MRI and clinical features in meningeal carcinomatosis. *Neuroradiology* 1993;35:512-514
5. Georgy BA, Chong B, Chamberlain M, Hesselink JR, Cheung G. MR of the spine in Guillain-Barre syndrome. *AJNR Am J Neuroradiol* 1994;15:300-301
6. Gero B, Sze G, Sharif H. MR imaging of inflammatory diseases of the spine. *AJNR Am J Neuroradiol* 1991;12:1009-1019
7. Demaeral P, Wilms G, Van Lierde S, Delanote J, Baert AL. Lyme disease in childhood presenting as primary leptomeningeal enhancement without parenchymal findings on MR. *AJNR Am J Neuroradiol* 1994;15:302-304
8. Hansman-Whiteman ML, Dandapani BK, Shebert RT, Donovan-Post MJ. MRI of AIDS-related polyradiculomyelitis. *J Comput Assist Tomogr* 1994;18:7-11