



## Discover Generics

Cost-Effective CT & MRI Contrast Agents

 FRESENIUS  
KABI

[WATCH VIDEO](#)

# AJNR

## Neuroimaging findings in rare amebic infections of the central nervous system.

D J Schumacher, R D Tien and K Lane

*AJNR Am J Neuroradiol* 1995, 16 (4) 930-935

<http://www.ajnr.org/content/16/4/930>

This information is current as  
of June 23, 2025.

---

# Neuroimaging Findings in Rare Amebic Infections of the Central Nervous System

D. James Schumacher, Robert D. Tien, and Kathy Lane

**Summary:** The imaging findings in a case of panamebic meningoencephalitis and in a case of granulomatous amebic encephalitis, two rare infections of the central nervous system caused by amebae, are presented and the world literature is reviewed. The brain CT findings in panamebic meningoencephalitis are nonspecific; our case showed diffuse edema. In the case of granulomatous amebic encephalitis, there was evidence of large arterial occlusions and MR demonstration of spinal cord infarctions.

**Index terms:** Nervous system, infection; Children, central nervous system

Free-living amebae are known to cause two distinct, rare infections of the central nervous system: primary amebic meningoencephalitis and granulomatous amebic encephalitis (1–3). The clinical presentation and pathologic characteristics of these two entities are sufficiently different that they are rarely confused with one another. This article demonstrates the imaging findings in one case of each of these rare diseases and reviews the literature.

## Case 1

Five days after swimming in a lake, a 4-year-old boy presented with fever, headache, vomiting, and meningeal signs. Cerebrospinal fluid contained 1830 white blood cells per cubic millimeter and empiric antibiotic therapy for presumed bacterial meningitis was begun. Seizures and mental status changes developed. A noncontrast brain computed tomography (CT) scan revealed diffuse brain edema (Fig 1). The patient died 48 hours after presentation and autopsy revealed *Naegleria fowleri* in the subarachnoid space, diagnostic of panamebic meningoencephalitis.

## Case 2

A 17-month-old boy presented to a local emergency room with irritability and vomiting. Augmentin therapy for otitis media was begun. One day later left body weakness

and lethargy developed, and the patient presented to our emergency room. An initial brain CT scan (Fig 2A–C) revealed lucency in the right middle cerebral artery territory with mass effect and early hydrocephalus suggestive of infarction. Occlusion of the right middle cerebral artery was documented angiographically (Fig 2D) and subsequent CTs revealed multiple large-vessel infarctions (Fig 2E). No source of embolic phenomenon could be identified. Cerebrospinal fluid studies revealed elevated protein (2180 mg/dL), decreased glucose (22 mg/dL), and 95 white blood cells per cubic millimeter. This was felt to be compatible with tuberculous meningitis, and the patient was treated with isoniazid, rifampin, and streptomycin. Cerebrospinal fluid protein from lumbar puncture was greatly elevated compared with that obtained from ventriculostomy, and therefore magnetic resonance (MR) imaging of the spine was performed to rule out spinal obstruction. A T1-weighted MR image (Fig 2F–H) revealed a diffusely enlarged cord with heterogeneous signal and enhancement that was most prominent along the surface of the cord (Fig 2I). The patient died on hospital day 24, and autopsy confirmed multiple cerebral and spinal infarctions secondary to a granulomatous meningitis and encephalitis caused by an ameba of the Leptomyxida order.

## Discussion

### *Panamebic Meningoencephalitis*

Panamebic meningoencephalitis is an acute, fulminant, rapidly fatal infection of the brain and meninges caused by *N fowleri* (1–4). Although this organism is found everywhere, the most common source of exposure for humans is by swimming in stagnant pools of warm freshwater, typically in summer months. Once the organism contacts the nasal mucosa, it penetrates the olfactory neuroepithelium and rapidly advances along the mesaxonal spaces of the olfactory nerves into the central nervous system. Dissemination occurs through the sub-

---

Received March 9, 1993; accepted after revision July 9.

From the Departments of Radiology (D.J.S., R.D.T.) and Pathology (K.L.), Duke University Medical Center, Durham, NC.

Address reprint requests to R.D. Tien, Department of Radiology, Duke University Medical Center, Box 3808, Durham, NC 27707.

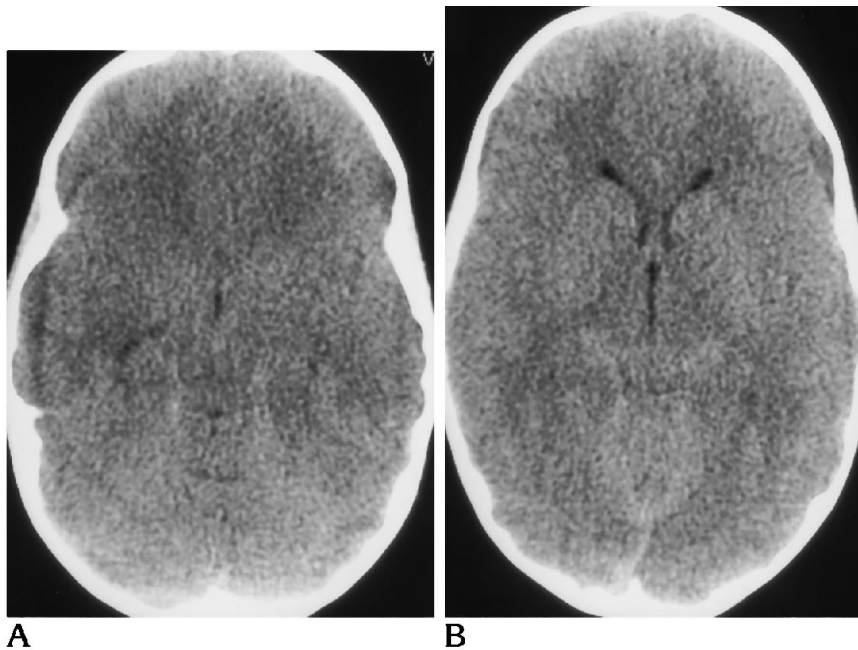


Fig 1. A, Noncontrast CT at the level of the temporal horns showing effacement of perimesencephalic cisterns.

B, Noncontrast CT at the level of the superior colliculus showing effacement of the quadrigeminal plate cistern. Sulci could not be identified anywhere in the cerebral cortex. At autopsy, *Naegleria fowleri* were identified in the subarachnoid space in this patient with panamebic meningoencephalitis.

arachnoid space and into the adjacent cerebral cortex, primarily at the base of the brain. Clinical symptoms are similar to acute bacterial meningitis. To date, there have been more than 140 cases of panamebic meningoencephalitis reported in the literature (2), and 3 documented survivors (5–9). Virginia, Florida, and Texas have the highest reported incidence within the United States (2). Prompt diagnosis and early initiation of appropriate amebicidal antibiotics (intravenous amphotericin B with supplemental intrathecal amphotericin B and oral rifampin [9]) are the cornerstones to improving survival (8, 9).

We reviewed 10 CTs that have been reported in the literature in cases of panamebic meningoencephalitis (including our own case and one case in which 2 CTs were done) (9–15). Intravenous contrast was administered in two cases, not administered in three cases, and not specifically mentioned in five cases. The CT was interpreted as normal in four cases. Cerebral edema was the only finding in four cases. One case showed both cerebral edema and contrast enhancement of the basilar cisterns and sulci. One case showed generalized meningeal enhancement in the basilar cisterns with mild hydrocephalus but no edema.

It has been more than a decade since the first report of the CT findings in panamebic meningoencephalitis (11). In that report, contrast enhancement and obliteration of the basilar cis-

terns was described as a nonspecific, but central feature of the disease. Our review of the literature suggests that the most common findings on CT (seen in 50%) are interpreted as “cerebral edema.” The CT appearance of cerebral edema is not described in detail in most of the studies in this review. Because panamebic meningoencephalitis primarily affects the base of brain and basilar subarachnoid cisterns, and because one of the hallmarks of diffuse cerebral edema is effacement of the basilar cisterns, one might speculate that the finding observed in the reported cases was actually edema involving the base of brain. In any case, the CT manifestations of panamebic meningoencephalitis correlate well with the pathologic descriptions by Carter (4), who reported the first autopsied cases:

The brains, normal to soft in consistency, were tight in the skull but only moderately swollen with no evidence of pressure coning . . . Incision of the brains revealed slight generalised vascular engorgement and a degree of lateral ventricular collapse consistent with the moderate swelling of the brain.

Given the moderate nature of the above-mentioned edema, it is also not surprising that early in the course of the disease the brain CT could appear normal, as occurred in 40% of the cases in the literature.

In our review of panamebic meningoencephalitis, only 20% of cases demonstrated menin-

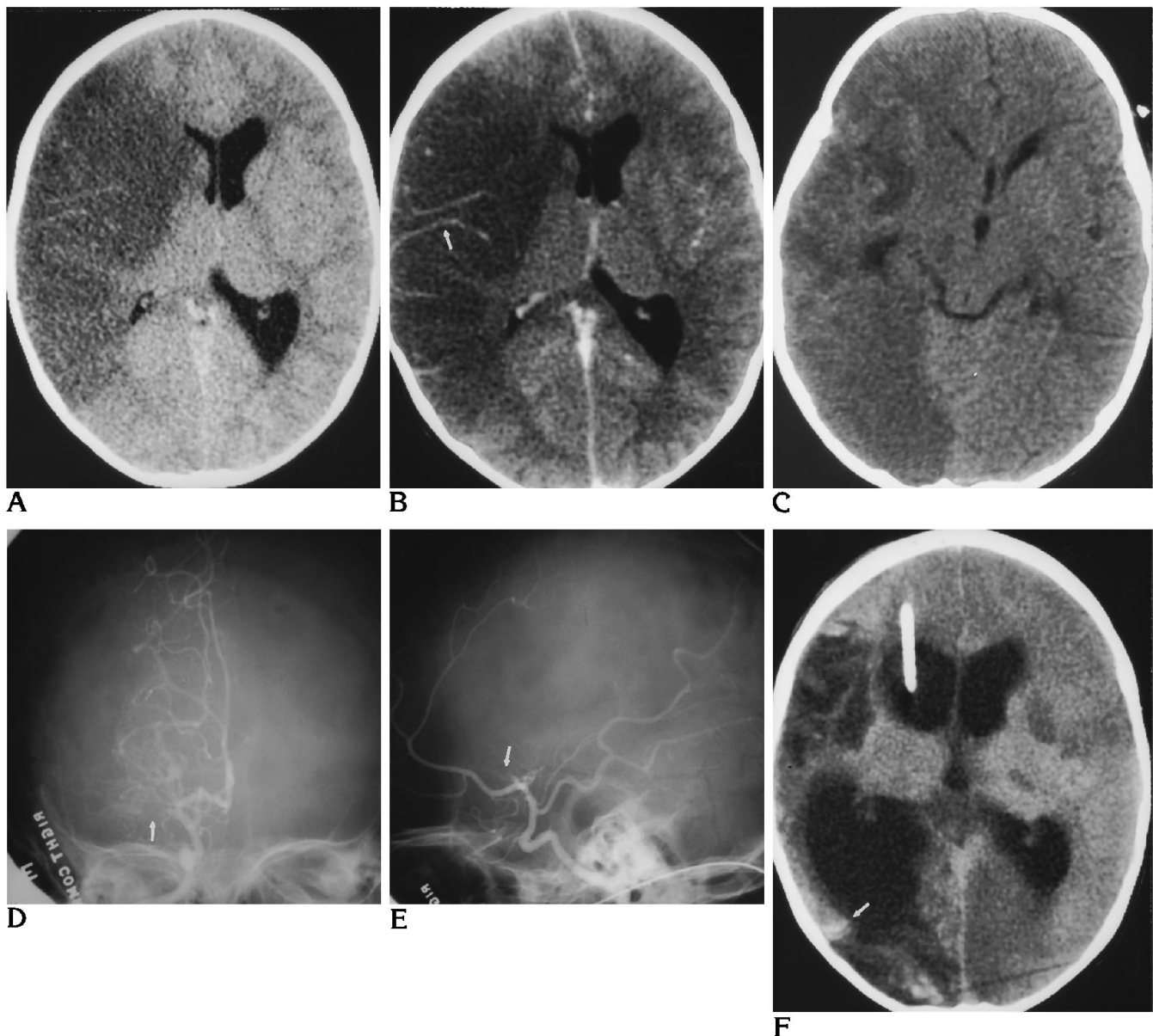


Fig 2. A, Noncontrast and B, contrast-enhanced CT images demonstrate low attenuation in the distribution of the right middle cerebral artery with mass effect (midline shift), trapping of the left lateral vehicle, and mild vascular enhancement (arrow in B).

C, Follow-up CT 1 week later demonstrates new low attenuation in the right posterior cerebral artery distribution.

D and E, Posterior-anterior and lateral arteriograms document occlusion of right proximal middle cerebral artery by filling defect (arrows).

F, Follow-up noncontrast CT 3 weeks later demonstrates ventriculomegaly with ventriculostomy tube in right frontal horn, early gyriform calcification in areas of prior infarction (arrows), and new multifocal areas of low attenuation in the left hemisphere and right anterior cerebral artery distribution. This patient died of granulomatous amebic encephalitis, and the areas of low attenuation were confirmed to be infarctions of major vascular territories. *Figure continues.*

geal enhancement on CT, and this enhancement was primarily basilar in distribution. Higher rates of enhancement can be seen in other forms of meningitis, including bacterial (40%) (16), and tuberculosis (62%) (16, 17). However, it should be noted that of the CT cases of panamebic meningoencephalitis we re-

viewed, only two had documented contrast administration, and both of these exhibited enhancement (11, 15). Therefore, the relative infrequency of meningeal enhancement in panamebic meningoencephalitis may be related to the infrequency of contrast use in examining this group of patients. This is not an

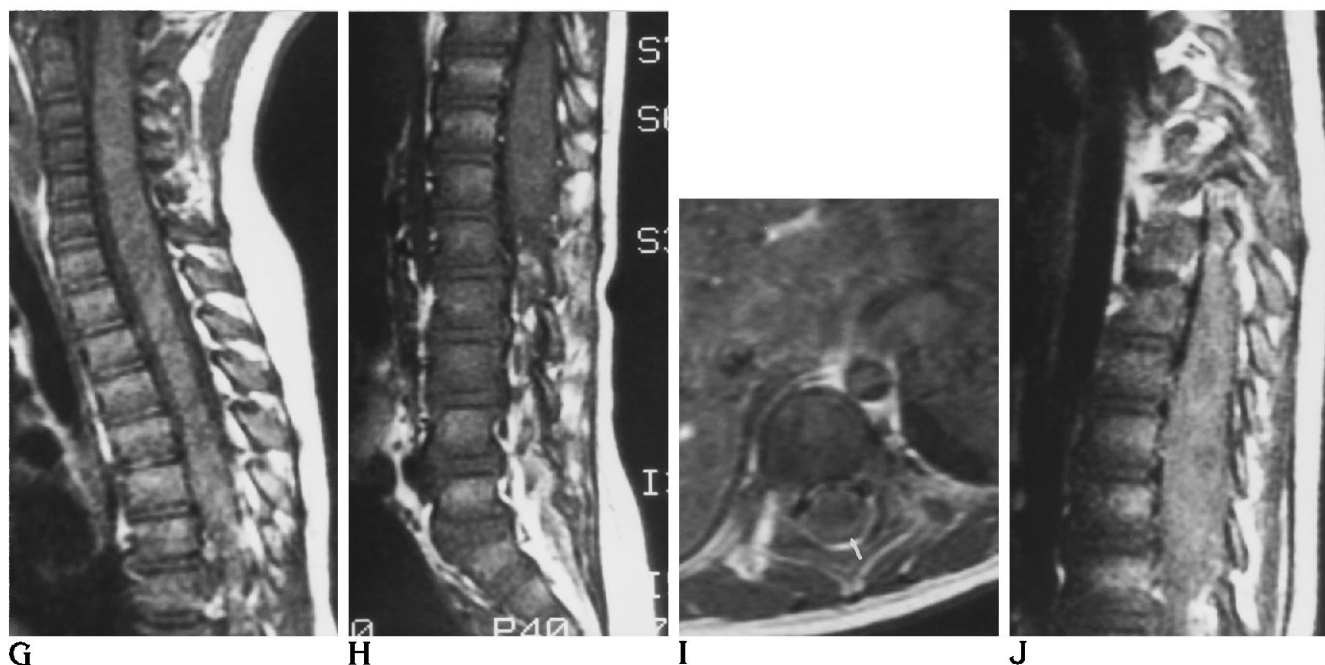


Fig 2.—continued.

G and H, T1-weighted MR imaging of the spine, 500/20/4 (repetition time/echo time/excitations), reveals diffuse enlargement of the cord with heterogeneous signal.

I and J, Postgadolinium MR image reveals heterogeneous enhancement especially along the surface of the cord (arrow in I). Autopsy confirmed multifocal areas of infarction in the spinal cord.

unexpected finding, because the accepted role of CT in evaluating patients with typical symptoms of meningitis is not to establish the diagnosis, but rather to identify potential complications of the disease (ie, hydrocephalus, infarction, abscess, or subdural empyema) and to screen for the presence of intracranial mass effect (18).

### *Granulomatous Amebic Encephalitis*

Granulomatous amebic encephalitis is typically a subacute or chronic disease characterized by the insidious onset of neurologic change, with death occurring within 8 days to several months (1–3). The disease occurs primarily in debilitated or immunosuppressed persons and is caused by amebae of *Acanthamoeba* or *Leptomyxa* species. Unlike the organisms responsible for panamebic meningoencephalitis, these amebae secondarily infect the central nervous system, possibly from the lower respiratory tract, genitourinary tract, or skin. There is no direct invasion through the nasal mucosa. Symptoms frequently resemble those of single or multiple space-occupying central nervous system lesions such as hemipar-

esis, personality changes, seizures, and headaches. Rarely, granulomatous amebic encephalitis can present with a fulminant, rapidly fatal course that mimics panamebic meningoencephalitis (6, 19, 20). More than 56 cases of granulomatous amebic encephalitis have been reported from all over the world (2). Although there is no proved effective therapy for this disease, three of the reported patients have survived (2).

Pathologically, granulomatous amebic encephalitis is characterized by multifocal areas of brain softening with hemorrhagic necrosis, edema, and abscess formation (1, 3). The posterior fossa structures, the thalamus, and the brain stem are the most frequently affected structures, but involvement of the cerebral hemispheres is common (no predilection for lobes). Leptomeningeal exudate is frequently patchy and can be moderate. Mass effect can result in uncus or cerebellar tonsil herniation. Microscopically, lesions consist of chronic granulomatous type reaction with focal necrosis and hemorrhage. Angiitis is invariably present secondary to amebic invasion into vascular walls and lumens and resulting fibrinoid necrosis and variable degrees of vessel thrombosis.

Imaging findings have been reported in the literature for 16 cases of granulomatous amebic encephalitis, including our own (20–34). A large proportion of patients (12 of 16, 75%) developed multifocal abnormalities on CT at some point in their illness, although single lesions were frequent at presentation (6 of 16, 38%). The lesions were usually hypodense (12 of 15, 80%), although one case (7%) exhibited a hyperdense lesion, one case (7%) exhibited an isodense lesion, and one case (7%) demonstrated an enhancing lesion that was not evaluated before contrast. Most CTs performed with contrast showed enhancement (8 of 10, 80%). Mass effect was common (9 of 15, 60%), but hydrocephalus was not (4 of 16, 25%). In a few instances, the CT findings were normal at presentation (2 of 16, 12%).

MR has been reported in two cases of granulomatous amebic encephalitis (29, 33). In one case in which the initial CT findings were normal, MR at the same time revealed multifocal areas of signal abnormality, which were confirmed on later CTs. Posterior fossa abnormalities are common at autopsy. However, these were demonstrated on only 1 of 16 CTs. One of two MR cases demonstrated brain stem lesions; this was a different case than the one in which they were discovered with CT.

Cerebral infarction (either venous or arterial) is a well-recognized complication of bacterial (18) and tuberculosis (35) meningitis. This complication also is seen pathologically in granulomatous amebic encephalitis secondary to invasion of vessels by amebae, but the process is typically confined to smaller vessels resulting in small areas of necrosis (3). Our case documents a large vessel arterial infarction in granulomatous amebic encephalitis and demonstrates the MR findings of spinal cord infarction.

This report reviews the CT manifestations of two rare amebic infections of the central nervous system: panamebic meningoencephalitis and granulomatous amebic encephalitis. Panamebic meningoencephalitis is uniformly fatal unless diagnosis and treatment are prompt. Unfortunately, the CT findings are nonspecific, consisting of either cerebral edema (40%) or normal brain (40%). Therefore, the radiologist must consider this diagnosis whenever these nonspecific findings are accompanied by the appropriate history suggestive of meningitis with exposure to warm, freshwater pools. Gran-

ulomatous amebic encephalitis typically presents clinically with unifocal or multifocal mass lesions in immunocompromised or debilitated patients. CT typically confirms multifocal cerebral lesions with mass effect, and these are most often hypodense. Whereas small areas of necrosis are common in granulomatous amebic encephalitis, we describe a case with infarction of multiple, major vascular territories in the brain and spinal cord.

## References

1. Ma P, Visvesvara GS, Martinez AJ, Theodore FH, Daggett PM, Sawyer TK. Naegleria and Acanthamoeba infections: review. *Rev Infect Dis* 1990;12:490–513
2. Visvesvara GS, Stehr-Green JK. Epidemiology of free-living ameba infections. *J Protozool* 1990;37:25S–33S
3. Martinez AJ. Is Acanthamoeba encephalitis an opportunistic infection? *Neurology* 1980;30:567–574
4. Carter RF. Primary amebic meningo-encephalitis: clinical, pathologic, and epidemiological features in six fatal cases. *J Pathol Bacteriol* 1968;96:1–25
5. Apley J, Clarke SKR, Roome APCH, et al. Primary amoebic meningoencephalitis in Britain. *Br Med J* 1970;1:596–599
6. Griffin JL. Letter: *Acanthamoeba* meningoencephalitis in brain. *Br J Med* 1976;1:153
7. Anderson K, Jamieson A. Primary amebic meningoencephalitis. *Lancet* 1972;1:902–903
8. Seidel JS, Harmatz P, Visvesvara GS, Cohen A, Edwards J, Turner J. Successful treatment of primary amebic meningoencephalitis. *N Engl J Med* 1982;306:346–348
9. Brown RL. Successful treatment of primary amebic meningoencephalitis. *Arch Intern Med* 1991;151:1201–1202
10. Rothrock JF, Buschsbaum HW. Primary amebic meningoencephalitis. *JAMA* 1980;243:2329–2330
11. Lam AH, de Silva M, Procopis P, Kan A. Primary amebic (*Naegleria*) meningoencephalitis. *J Comput Assist Tomogr* 1982;6:620–623
12. Seidel J. Primary amebic meningoencephalitis. *Pediatr Clin North Am* 1985;32:881–892
13. Benson RL, Ansbacher L, Hutchison RE, Rogers W. Cerebrospinal fluid centrifuge analysis in primary amebic meningoencephalitis due to *Naegleria fowleri*. *Arch Pathol Lab Med* 1985;109:668–671
14. Kline MW, Anderson DC, Dobson S, Strong J. Primary amebic meningoencephalitis. *Pediatr Emerg Care* 1986;2:173–175
15. Center for Disease Control. Primary amebic meningoencephalitis: North Carolina, 1991. *Morb Mortal Wkly Rep* 1992;41(25):437–440
16. Chang KH, Han MH, Roh JK, Han MC, Kim C. Gd-DTPA-enhanced MRI of the brain in patients with meningitis: comparison with CT. *AJNR Am J Neuroradiol* 1990;11:69–76
17. Offenbacher H, Fazekas F, Schmidt R, et al. MRI in tuberculous meningoencephalitis: report of four cases and review of the neuroimaging literature. *J Neurol* 1991;238:340–344
18. Wardle S, Carty H. CT scanning in meningitis. *Eur J Radiol* 1991;12:113–119
19. Gogate A, Singh BN, Deodhar LP, Jhala HI. Primary amebic meningoencephalitis caused by *Acanthamoeba*. *J Postgrad Med* 1984;30:125–128

20. Grunnet ML, Cannon GH, Kushner JP. Fulminant amebic meningoencephalitis due to *Acanthamoeba*. *Neurology* 1981;31:174-177
21. Gullett J. Disseminated granulomatous *Acanthamoeba* infection presenting as an unusual skin lesion. *Am J Med* 1979;67:891-895
22. Wessell HB, Hubbard J, Martinez AJ, Willaert E. Granulomatous amebic encephalitis (GAE) with prolonged clinical course: CT scan findings, diagnosis by brain biopsy, and effect of treatment. *Neurology* 1980;30:442
23. Martinez AJ, Sotelo-Avila C, Alcala H, Willaert E. Granulomatous encephalitis, intracranial arteritis, and mycotic aneurysm due to a free-living amoeba. *Acta Neuropathol (Berl)* 1980;49:7-12
24. Martinez AJ, Garcia CA, Halks-Miller M, Arce-Vela R. Granulomatous amebic encephalitis presenting as a cerebral mass lesion. *Acta Neuropathol (Berl)* 1980;51:86-91
25. Martinez AJ. Acanthamebiasis and immunosuppression. *J Neuropathol Exp Neurol* 1982;41:548-557
26. Lalitha MK, Anandi V, Srivastava A, Thomas K, Cherian AM, Chandi SM. Isolation of *Acanthamoeba culbertsoni* from a patient with meningitis. *J Clin Microbiol* 1992; 21:666-667
27. Ofori-Kwakye SK, Sidebottom DG, Herbert J, Fischer EG, Visvesvara GS. Granulomatous brain tumor caused by *Acanthamoeba*: case report. *J Neurosurg* 1986; 64:505-509
28. Wiley CA, Safrin RE, Davis CE, et al. *Acanthamoeba* meningoencephalitis in a patient with AIDS. *J Infect Dis* 1987;155:130-133
29. Matson DO, Rouah E, Lee RT, Armstrong D, Parke JT, Baker CJ. *Acanthamoeba* meningoencephalitis masquerading as neurocysticercosis. *Pediatr Infect Dis* 1988;7:121-124
30. Gardner HAR, Martinez AJ, Visvesvara GS, Sotrel A. Granulomatous amebic encephalitis in an AIDS patient. *Neurology* 1991;41: 1993-1995
31. Anzil AP, Rao C, Wrzolek MA, Visvesvara GS, Sher JH, Kozlowski PB. Amebic meningoencephalitis in a patient with AIDS caused by a newly recognized opportunistic pathogen. *Arch Pathol Lab Med* 1991;115:21-25
32. Gonzalez-Alfonzo JE, Martinez AJ, Garcia V, Garcia-Tamayo J, Cespedes G. Granulomatous encephalitis due to a leptomycid amoeba. *Trans R Soc Trop Med Hyg* 1991;85:480
33. Taratuto AL, Monges J, Acefe JC, Meli F, Paredes A, Martinez AJ. *Leptomyxid* amoeba encephalitis: report of the first case of Argentina. *Trans R Soc Trop Med Hyg* 1991;85:77
34. Karande SC, Lahiri KR, Sheth SS, Nadkarni US, Jain MK, Shah MD. *Acanthamoeba* meningoencephalitis complicating pyogenic meningitis. *Indian J Pediatr* 1991;28:794-797
35. Casselman ES, Hasso AN, Ashwal S, Schneider S. Computed tomography of tuberculous meningitis in infants and children. *J Comput Assist Tomogr* 4:211-216