

---

# Angiolymphoid Hyperplasia with Eosinophilia of the Head and Neck

Rebecca S. Cornelius, Paul W. Biddinger, and Jack L. Gluckman

**Summary:** We described a patient with a pulsatile retroauricular mass that was caused by pathologically proved angiolymphoid hyperplasia with eosinophilia. Angiography and contrast-enhanced CT were performed before surgical excision. Although rare, this entity should be considered in the differential diagnosis of hypervascular masses of the superficial head and neck.

**Index terms:** Arteries, abnormalities and anomalies; Neck, abnormalities and anomalies

Angiolymphoid hyperplasia with eosinophilia is an unusual vascular tumor most frequently located in the superficial head and neck. The lesion rarely arises from a native blood vessel. We report a case of angiolymphoid hyperplasia with eosinophilia arising from the posterior auricular artery. This entity is well described in pathology and dermatology literature. Imaging findings in our case will be described.

## Case Report

A 40-year-old woman presented with a 6-month history of a pulsatile mass behind the right ear. She had noted slow enlargement over the past 4 months. There was no history of trauma. Physical examination revealed a firm, nontender ovoid pulsatile 3-cm mass in the right retroauricular region. Complete blood count with differential, renal profile, and coagulation profile were normal.

The patient underwent angiography with a presumed diagnosis of postauricular aneurysm. Common carotid and selective external carotid artery injections revealed a well-circumscribed hypervascular mass arising from the posterior auricular branch of the external carotid artery. The lesion appeared to involve the wall of the vessel circumferentially and resulted in fusiform dilatation of the vessel wall. Linear striations of enhancement were oriented perpendicular to the axis of the parent vessel. Tumor blush progressively increased from arterial phase through the capillary and venous phase. (Fig 1A and B and Fig 2A and B) Contrast-enhanced computed tomography (CT) demonstrated a brightly enhancing subcutaneous mass (Fig 3).

Surgical resection was performed. Gross pathologic specimen consisted of a well-circumscribed  $3.0 \times 1.8 \times 1.5$  cm mass surrounding a central vascular structure (Fig 4A). Histologic examination revealed features characteristic of angiolymphoid hyperplasia with eosinophilia (Fig 4B). A large artery with intimal hyperplasia was surrounded by vaguely lobular proliferations of small-caliber blood vessels and lymphoid follicles. The stroma contained a diffuse inflammatory infiltrate with a high concentration of eosinophils.

## Discussion

Angiolymphoid hyperplasia with eosinophilia is an unusual vascular tumor that typically occurs at 20 to 40 years of age, more commonly in women. In about 50% of patients, multiple lesions develop. Approximately 30% of the lesions recur, but no metastatic lesions have been documented unequivocally (1).

The lesions are typically circumscribed masses in the subcutaneous tissue or dermis. They are most frequently located in the superficial head and neck, especially common in the periauricular region. They rarely may arise from native blood vessels, as is seen in our case (1).

Spontaneous regression has been reported, although most lesions require surgical excision (2, 3). Patients occasionally may have peripheral eosinophilia or enlarged regional lymph nodes.

Controversy exists regarding the nature of these lesions. Some authors consider them benign neoplasms, whereas others believe they are reactive in nature. Most evidence supports that these are neoplasms that elicit an inflammatory response (1, 4).

Characteristic histopathologic features include an exuberant proliferation of small caliber, capillary-size blood vessels and diffuse inflammatory infiltrate. The proliferation of blood

---

Received February 17, 1993; accepted after revision July 9.

From the Departments of Radiology (R.S.C.), Pathology (P.W.B.), and Otolaryngology (J.L.G.), University of Cincinnati (Ohio).

Address reprint requests to Rebecca S. Cornelius, MD, University of Cincinnati, Department of Radiology, Neuroradiology Section, 234 Goodman St, Cincinnati, OH 45267-0742.

AJNR 16:916-918, Apr 1995 0195-6108/95/1604-0916 © American Society of Neuroradiology

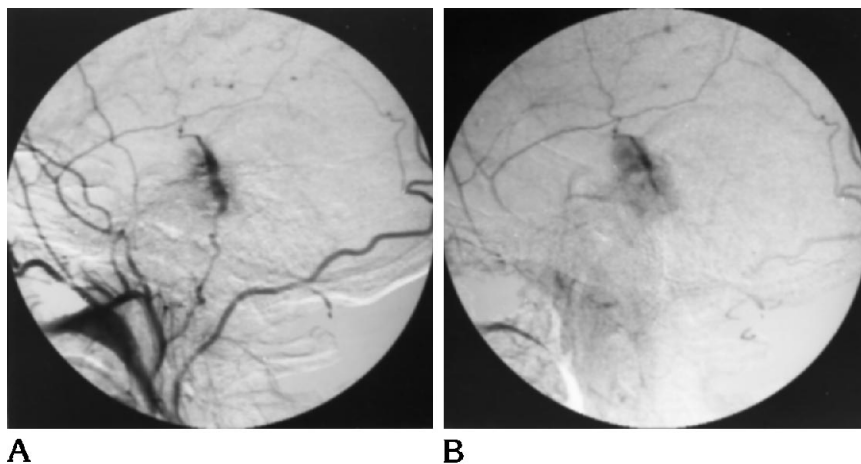


Fig 1. Lateral view of selective right external carotid arteriogram shows hypervascular mass arising from the posterior auricular artery.

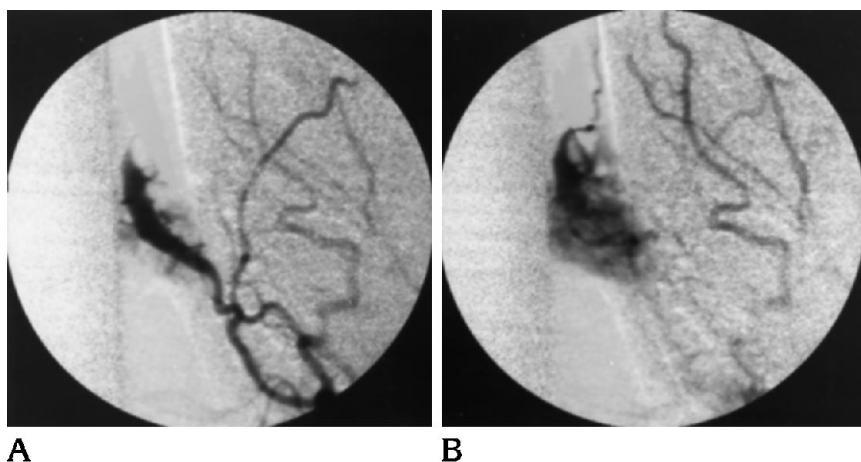


Fig 2. Anteroposterior view, right external carotid arteriograms in arterial and capillary phases show a vascular mass surrounding the posterior auricular artery with fusiform dilatation of the artery and linear neovascular channels.

vessels has a vague lobular pattern and frequently surrounds a larger blood vessel. The endothelial cells commonly are hypertrophic and sometimes form solid cords with cytoplasmic vacuoles resembling primitive lumina. The inflammatory infiltrate consists of abundant eosinophils along with lymphocytes, plasma cells, macrophages, and mast cells. Lymphoid follicles with germinal centers can be seen, particularly at the periphery of the lesion (Fig 4B).

Originally this condition was considered the same entity as Kimura disease described in Asian patients. More recent histologic studies indicate that angiolymphoid hyperplasia with eosinophilia and Kimura disease are different clinical and histologic entities (1, 5-9).


Review of the case reports in the literature revealed few references to imaging studies in these patients. Angiographic findings in three other case reports are not described in detail but

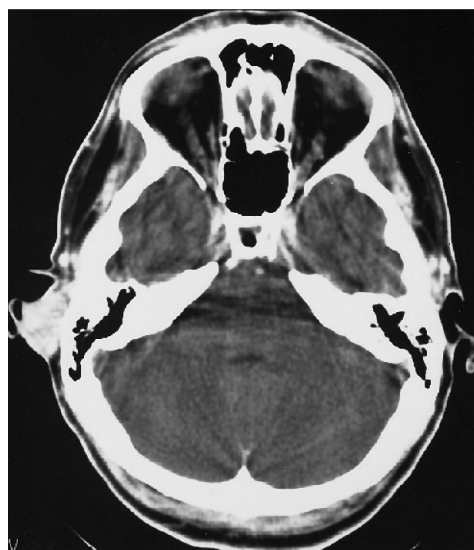

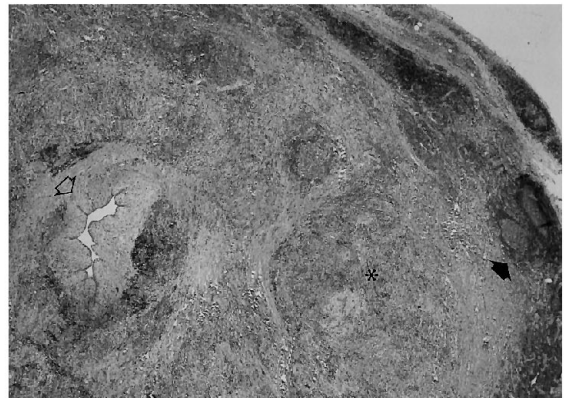Fig 3. Contrast-enhanced CT scan demonstrates enhancing subcutaneous postauricular mass.

Fig 4. A, Gross photomicrograph of cross section of 3-cm mass surrounding the posterior auricular artery.

B, Low-power photomicrograph showing large central artery, which has intimal hyperplasia (*open arrow*) and is surrounded by vaguely lobular proliferations of small caliber blood vessels (*asterisk*) and lymphoid follicles with germinal centers (*closed arrow*).



A



B

have similarities to our case (10–12). In a case reported in the otolaryngology literature, a patient with a lesion similar to our patient's had a CT scan showing a nonenhancing mass (8). There is a single reference to magnetic resonance images in a case reported by Calhoun et al. The features were not described other than to mention a lack of apparent feeding vessels (8).

The differential diagnosis of this lesion based on clinical and/or histopathologic findings includes pyogenic granuloma, nevus, keratosis, reaction to insect bite, hemangioma, glomus tumor, malignant angioendothelioma, angiosarcoma, and Kaposi sarcoma (3, 8–11, 13–15). Unfortunately there are cases reported in which initial histology was interpreted as angiosarcoma and malignant angioendothelioma. These patients underwent aggressive surgical resection before the correct diagnosis was made (10, 11).

This case demonstrates interesting radiographic findings and the classic histopathologic findings in angiolymphoid hyperplasia with eosinophilia of the head and neck. The neuroradiologist should be aware of this entity, because the angiographic and histologic findings could suggest a more aggressive angiomatous neoplasm (9, 10).

## References

1. Enzinger FW, Weiss SW. *Soft Tissue Tumors*. 2nd ed. St Louis: CV Mosby, 1988:502–508.
2. Kandil E. Dermal angiolymphoid hyperplasia with eosinophilia versus pseudopyogenic granuloma. *Br J Dermatol* 1970;83:405–408.
3. Jones EW, Bleeher SS. Inflammatory angiomatous nodules with abnormal blood vessels occurring about the ears and scalp. *Br J Dermatol* 1969;81:804–816.
4. Menz J, Su WPD. Angiolymphoid hyperplasia with eosinophilia: monoclonal leukocyte antibody studies in two cases. *Arch Dermatol* 1987;123:866–867.
5. Googe PB, Harris NL, Mihn MC. Kimura's disease and angiolymphoid hyperplasia with eosinophilia: two distinct histopathological entities. *J Cutan Pathol* 1987;14:263–271.
6. Urabe A, Masazumi T, Munetomo E. Epithelioid hemangioma versus Kimura's disease: a comparative clinicopathologic study. *Am J Surg Pathol* 1987;11(10):758–766.
7. Rosai J, Gold J, Landy R. The histiocytoid hemangiomas. *Hum Pathol* 1979;10(6):707–730.
8. Calhoun KH, Newton RC, Sanchez RL. Angiolymphoid hyperplasia with eosinophilia. *Arch Otolaryngol Head Neck Surg* 1988;114:1474–1476.
9. Sharp JF, Rodgers MJC, MacGregor FB, Meehan CJ, McLaren K. Angiolymphoid hyperplasia with eosinophilia. *J Laryngol Otol* 1990;104:977–979.
10. Reed RJ, Terazakis N. Subcutaneous angioblastic lymphoid hyperplasia with eosinophilia. *Cancer* 1972;29:489–497.
11. Barnes L, Koss W, Nieland ML. Angiolymphoid hyperplasia with eosinophilia: a disease that may be confused with malignancy. *Head Neck Surg* 1980;May/June:425–434.
12. Grimwood R, Swinehart JM, Aeling JL. Angiolymphoid hyperplasia with eosinophilia. *Arch Dermatol* 1979;115:205–207.
13. Thompson JW, Colman M, Williamson C, Ward PH. Angiolymphoid hyperplasia with eosinophilia of the external ear canal. *Arch Otolaryngol* 1981;107:316–319.
14. Vallis RC, Davies DG. Angiolymphoid hyperplasia of the head and neck. *J Laryngol Otol* 1988;102(1):100–101.
15. Waldo E, Sidhu GS, Stahl R, Zolla-Pazner S. Histiocytoid hemangioma with features of angiolymphoid hyperplasia and Kaposi's sarcoma. *Am J Dermatopathol* 1983;5(6):525–538.