



Discover Generics

Cost-Effective CT & MRI Contrast Agents



FRESENIUS
KABI

WATCH VIDEO

AJNR

MR of neurologically symptomatic newborns after vacuum extraction delivery.

M Castillo and L A Fordham

AJNR Am J Neuroradiol 1995, 16 (4) 816-818

<http://www.ajnr.org/content/16/4/816>

This information is current as
of June 23, 2025.

MR of Neurologically Symptomatic Newborns after Vacuum Extraction Delivery

Mauricio Castillo and Lynn A. Fordham

Summary: We present the MR findings in three neurologically symptomatic newborns after vacuum extraction delivery. The lesions included subdural hematomas, one tentorial hematoma, and one intracerebellar hemorrhage. One patient had hydrocephalus that required shunting. We propose that the visualized abnormalities are probably the result of vertical stress leading to laceration of bridging veins, venous sinuses, and/or venous hemorrhagic infarctions.

Index terms: Infants, central nervous system; Infants, newborn; Magnetic resonance, in infants and children

The vertical stress induced by either forceps or vacuum extraction delivery can give rise to extraaxial hematomas, subarachnoid hemorrhage, and infarctions (1–4). Exact delineation of these abnormalities is highly desirable, especially if surgery is considered likely. We present magnetic resonance (MR) findings in three symptomatic newborns after vacuum extraction delivery.

Case Reports

Case 1

A boy weighing 3.2 kg was born at term via vaginal delivery with vacuum extraction using a soft synthetic cup because of fetal suffering. The patient was noted to have increased muscle tone and arching movements of the trunk. Ultrasound of the head showed a left grade II hemorrhage and a possible right grade III hemorrhage. MR on the second day of life showed right posterior subdural hematomas, both supratentorially and infratentorially (Fig 1A and B). Bilateral subependymal hemorrhage was seen. No retinal hemorrhages were present. During the next 7 days the patient's condition improved and he was discharged. Nine-month follow-up showed the patient to be asymptomatic and developmentally normal.

Case 2

A boy was born at 36 weeks of gestation via vaginal delivery after a pregnancy complicated by cholecystitis. Vacuum extraction with a soft cup was performed because of macrocephaly (head circumference, 40 cm [above 95th percentile]). Apgar scores were normal. No retinal hemorrhages were seen. Plain computed tomography of the head showed marked dilatation of the ventricles and a right cerebellar hemorrhage. Ultrasound of the head was not done. MR imaging was done for further delineation of the hemorrhage and showed the hydrocephalus to be secondary to a large hemorrhagic lesion in the right cerebellar hemisphere that deformed and compressed the aqueduct of sylvius and fourth ventricle (Fig 2A and B). The lesion did not enhance after gadolinium administration. Because of the isolated and atypical location of the hemorrhage, cerebral angiography was performed and showed normal findings. A left ventriculoperitoneal shunt was inserted. Plain computed tomography 3 days after surgery showed the ventricles to be almost normal in size. The patient was discharged; a 6-month follow-up visit showed the patient to be stable, with mild developmental delay.

Case 3

A girl weighing 2.85 kg at term birth had signs in utero of fetal distress. Vacuum extraction with a soft cup was performed. Apgar scores were normal. Head circumference was normal and no retinal hemorrhages were seen. Ultrasound of the head immediately after birth was interpreted as normal. An episode of apnea and staring occurred 1 day after birth. MR imaging showed a centrally located tentorial hemorrhage with mass effect on the aqueduct producing mild hydrocephalus (Fig 3A and B). A small right occipital subdural hematoma that extended into the falx and a small right infratentorial subdural hematoma were also present. The patient's clinical status improved, and she was discharged on day 11. She was unavailable for further follow-up.

Received April 13, 1993; accepted after revision August 25.

From the Section of Neuroradiology, Department of Radiology, University of North Carolina, Chapel Hill.

Address reprint requests to Mauricio Castillo, MD, Section of Neuroradiology, Department of Radiology, CB 7510, University of North Carolina, Chapel Hill, NC 27599-7510.

AJNR 16:816–818, Apr 1995 0195-6108/95/1604–0816 © American Society of Neuroradiology

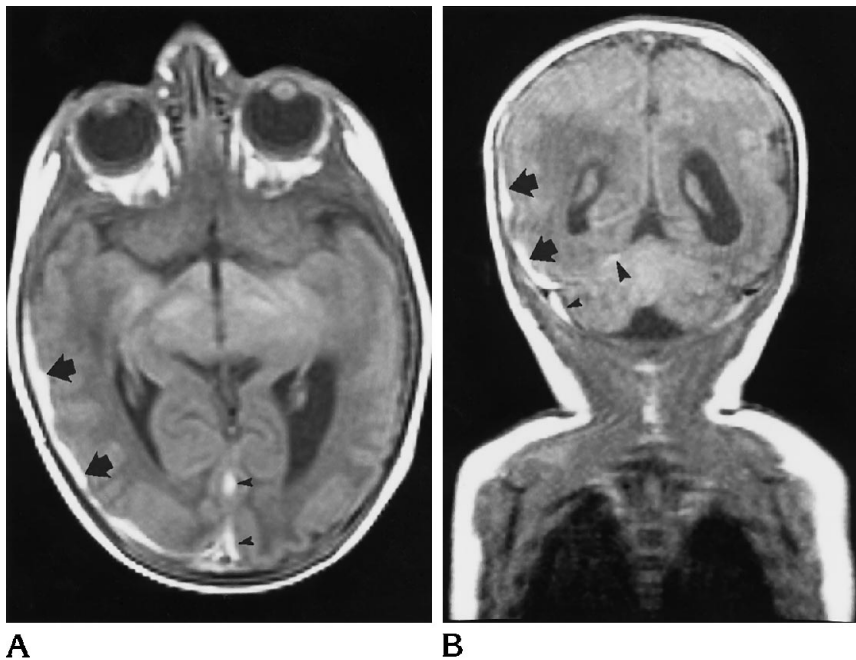


Fig 1. Case 1. A, Axial T1-weighted MR image shows a thin hyperintense subdural hematoma (arrows) along the right temporooccipital convexity with extension along the falx (arrowheads).

B, Coronal T1-weighted image confirms the presence of the right subdural hematoma (arrows) and shows a definite but small right posterior fossa subdural hematoma (small arrowhead), a probable small left posterior fossa subdural hematoma, and blood along the right tentorium (large arrowhead). A smaller extraaxial hemorrhage is seen along the left parietal convexity.

Discussion

Neurologic complications associated with vacuum extraction delivery include subdural hematomas, tentorial hematomas, infarctions (caused by arterial thrombosis secondary to stretching of the vessel walls), increased intracranial pressure, uncus herniation, and retinal hemorrhages (1–4). Depending on their size, location (especially those in the posterior fossa), and degree of mass effect, subdural hematomas might need prompt surgical drainage. The forces produced by vacuum extraction can be similar to those produced by forceps, which

is significant vertical stress (4). Vertical traction on the skull and brain may produce tentorial lacerations, rupture of bridging veins in the subdural compartment, laceration of the venous sinuses, and/or rupture of cortical veins as they enter the venous sinuses and/or vein of Galen. The latter may lead to subarachnoid blood, which in itself leads to vasospasm and may give rise to infarctions (3, 4). Occipital osteodiasis (separation of the posterior intraoccipital synchondrosis) may produce injury to the brain parenchyma that results in intracerebellar hemorrhages (5, 6). A review of the international

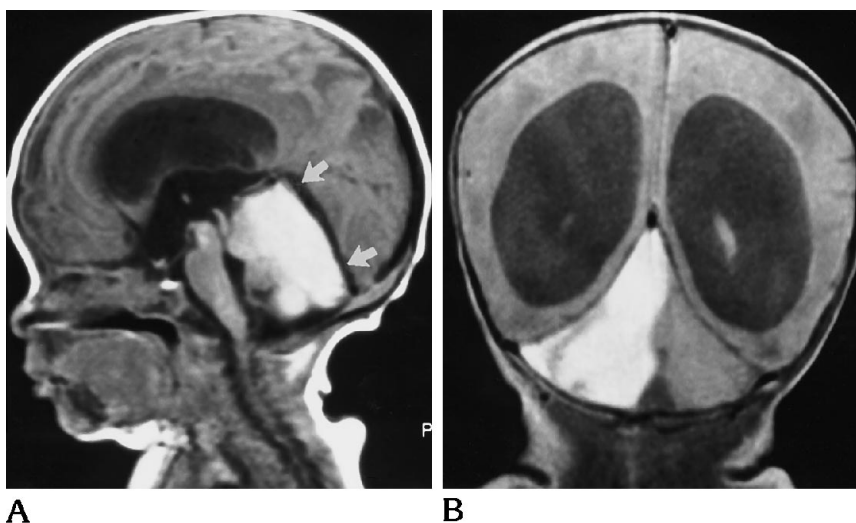
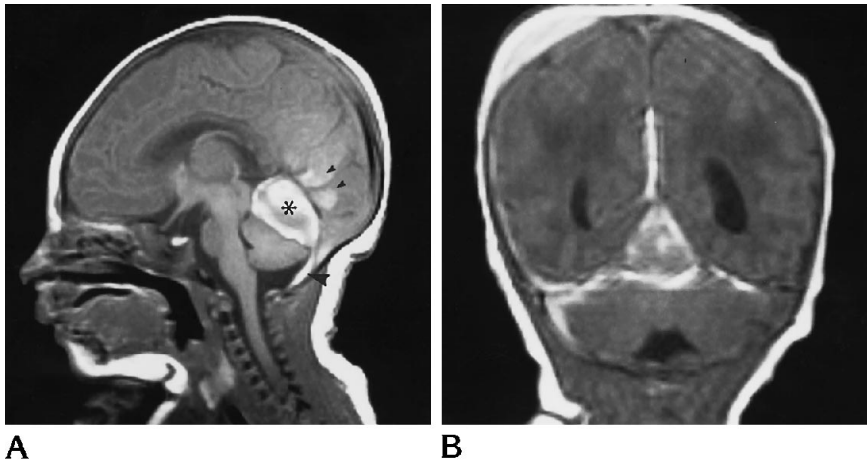


Fig 2. Case 2. A, Midsagittal T1-weighted image shows a large intracerebellar hemorrhage compressing the distal aqueduct of Sylvius and leading to noncommunicating hydrocephalus. Straight sinus (arrows) is slightly bowed dorsally and shows normal flow void indicating patency.

B, Coronal T1-weighted MR image clearly shows hemorrhage in right cerebellar hemisphere and crossing the midline superiorly. There is marked dilatation of the lateral ventricles.

Fig 3. Case 3. A, Midline sagittal T1-weighted image shows a well-demarcated hemorrhage (asterisk) believed to be contained within the leaves of the tentorium. There is a small subdural hematoma in the posterior fossa (large arrowhead). The straight sinus is small but patent, and there is hyperintensity (small arrowheads) in the occipital region related to a parafalcine blood collection (better seen in B).

B, Coronal T1-weighted image shows the central tentorial hematoma, blood layering along both leaves of the tentorium and along the posterior falx. The small right posterior fossa subdural hematoma is again seen. The blood in the right parietal region belongs to a cephalhematoma (better seen on axial images, not shown). The lateral ventricles are mildly prominent.



literature showed that the overall prevalence of intracranial hemorrhage was 0.72% of 14,276 vacuum extraction deliveries (7). During the period in which our patients were seen, 135 vacuum extractions were performed at our hospital.

Complications from vacuum extraction deliveries are usually seen in term neonates. They manifest clinically during the first 36 hours of life as a tense or bulging anterior fontanelle, apnea, bradycardia, seizures, vomiting, tonic posturing, lethargy, and decreased or absent reflexes (1). Lesser complications of vacuum extraction delivery include the formation of a chignon (area of edema and ecchymosis under the vacuum cup), superficial abrasions and lacerations, and cephalhematomas (1). One fourth to one half of the patients with vacuum extraction-related intracranial hemorrhages will have permanent neurologic damage and/or developmental delay (4).

Indications for vacuum extraction delivery are controversial, but are similar to those seen with the use of forceps, and include abnormalities of the second stage of labor (between full cervical dilatation and delivery), arrest of descent, maternal fatigue, and fetal distress.

All of our patients had what initially appeared to be uncomplicated vacuum extraction delivery. However, two neonates (cases 1 and 3) had neurologic symptoms during the first day of life. The most common underlying lesions were subdural hematomas, seen in two of our three cases (Figs 1A and B and 3A and B). These lesions are probably the result of ruptured bridging veins secondary to traction. In one instance, tentorial hemorrhage was present (Fig 3A). We

believe that vertical traction on the posterior falx leads either to "splitting" of the leaves of the tentorium with subsequent rupture of bridging veins or to laceration of the adjacent venous sinuses giving origin to tentorial hematomas. Because of the confined space in the posterior fossa, any mass lesion can lead to displacement of the structures and to development of hydrocephalus, or even death secondary to brain stem compression. Our third patient had a large hemorrhage involving the right cerebellar hemisphere (Fig 2A and B). Because this patient did not have occipital osteodiasis, we do not have a definite explanation for this finding.

In summary, computed tomography or preferably MR shows intracranial abnormalities related to vacuum extraction delivery. The hemorrhages seen in our cases probably resulted from vertical stress forces.

References

1. Lahat E, Schiffer J, Heyman E, Starinski R. Acute subdural hemorrhage: uncommon complication of vacuum extraction delivery. *Eur J Obstet Gynecol Reprod Biol* 1987;25:255-258
2. Huang CC, Shen EY. Tentorial subdural hemorrhage in term newborns: ultrasonographic diagnosis and clinical correlates. *Pediatr Neurol* 1991;7:171-177
3. Hanigan WC, Morgan AM, Stahlberg LK, Hiller JL. Tentorial hemorrhage associated with vacuum extraction. *Pediatrics* 1990;85:534-539
4. Govaert P, Vanhaesebrouck P, dePraeter C. Traumatic neonatal intracranial bleeding and stroke. *Arch Dis Child* 1992;67:840-845
5. Hemansanz J, Munoz F, Rodriguez D, et al. Subdural hematomas of the posterior fossa in normal-weight newborns. *J Neurosurg* 1984;61:972-974
6. Ravenel SD. Posterior fossa hemorrhage in the term newborn: report of two cases. *Pediatrics* 1979;64:39-42
7. Plauche WC. Fetal intracranial injuries related with the Malmstrom vacuum extractor. *Obstet Gynecol* 1979;53:750-757