



## Discover Generics

Cost-Effective CT & MRI Contrast Agents



WATCH VIDEO

# AJNR

### **High-flow, small-hole arteriovenous fistulas: treatment with electrodetachable coils.**

G Guglielmi, F ViÖ±uela, G Duckwiler, J Dion and A Stocker

*AJNR Am J Neuroradiol* 1995, 16 (2) 325-328

<http://www.ajnr.org/content/16/2/325>

This information is current as  
of June 6, 2025.

---

# High-Flow, Small-Hole Arteriovenous Fistulas: Treatment with Electrodetachable Coils

Guido Guglielmi, Fernando Viñuela, Gary Duckwiler, Jacques Dion, and Alfredo Stocker

**Summary:** We present one case of carotid-cavernous fistula caused by percutaneous treatment of trigeminal neuralgia and one case of vertebrovertebral fistula caused by percutaneous internal jugular vein cannulation. Each fistula had a small arteriovenous communication that prevented the use of detachable balloons. Endovascular transarterial treatment of these two iatrogenic fistulas with electrically detachable platinum coils was performed. Both fistulas were occluded with preservation of the parent artery, and the patients have fully recovered.

**Index terms:** Fistula, arteriovenous; Fistula, therapeutic blockade; Interventional instruments, coils

High-flow carotid-cavernous and vertebrovertebral fistulas are commonly treated with the endovascular approach with detachable balloons, preserving the parent artery (1–4). If the volume of the venous compartment of the fistula is too small to allow balloon inflation or if the fistulous communication is too small to allow entry of the balloon, transarterial or transvenous approaches using platinum coils have been advocated to occlude the venous compartment of the fistula, thereby preserving the arterial axis (5–7).

This paper reports one case of carotid-cavernous fistula and one case of vertebrovertebral fistula, both with small fistulous communications, that were treated with electrolytically detachable platinum coils via the transarterial approach.

## Case Reports

### Case 1

A 60-year-old woman had a percutaneous rizotomy (trigeminal block) for left trigeminal neuralgia. After the procedure, she experienced a pulsatile bruit in the left ear accompanied by discomfort and conjunctival injection. On

neurologic examination, the patient had no evidence of cranial nerve deficit, although the left eye showed slight conjunctival injection. An audible pulsatile bruit over the left eye was noticed. Because of the progressive increase of the ocular bruit during the next 3 months, the patient had a cerebral angiogram. It showed a “small-hole” left carotid-cavernous fistula draining into the ipsilateral inferior petrosal sinus and superior ophthalmic vein (Figs 1A and B).

Endovascular balloon occlusion of the fistula was attempted. Under systemic heparinization (3000 U bolus and 1000 U/h intravenously), a 7F guiding catheter was positioned in the left internal carotid artery. A detachable balloon was manipulated at the fistula site. Despite several attempts, we were unable to guide the balloon through the fistulous communication because of the small size of the opening. Subsequently, a Tracker-18 microcatheter was advanced superselectively through the fistulous communication into the left cavernous sinus. Initially, an attempt was made to position a 5-mm circular-memory, 15-cm-long, 0.015-in-diameter platinum detachable coil (Guglielmi detachable coil [GDC]; Target Therapeutics, Fremont, Calif) in the cavernous sinus; however, this proved technically impossible because of recoiling of the microcatheter. A second attempt, using a  $5 \times 15 \times 0.010$  coil, was unsuccessful for the same reason. Finally, a 3-mm coil, 8 cm long and 0.010 in in diameter, was advanced through the fistula and delivered into a small venous compartment of the cavernous sinus. This coil was electrolytically detached by applying a 0.7-mA, 2.5-V positive direct electric current to the delivery wire. An immediate postembolization angiogram demonstrated slow residual flow through the fistula. While attempting to perform a transvenous embolization of the residual arteriovenous fistula, it was noted that further thrombosis had occurred and the fistula was no longer visible (Fig 1C). A 6 weeks' follow-up angiogram confirmed complete obliteration of the fistula as well as patency of the left internal carotid artery. The patient had full clinical recovery.

---

Received November 30, 1992; accepted after revision March 31, 1993.

This work was supported by grant RO1 HL46286-01 from the National Institutes of Health and by Target Therapeutics, Fremont, Calif.

From the Department of Radiological Sciences, Endovascular Therapy Section, University of California at Los Angeles.

Address reprint requests to Guido Guglielmi, MD, Department of Radiology, University of California at Los Angeles, 10833 Le Conte Ave, Los Angeles, CA 90024-1721.




Fig 1. Case 1. A, Left internal carotid angiogram, early arterial phase, lateral view. A left carotid-cavernous fistula with a small fistulous communication (*arrow*) is visible.

B, The drainage of the fistula is through the superior ophthalmic vein (*short arrow*) and the inferior petrosal sinus (*long arrow*).

C, Postembolization angiogram showing occlusion of the fistula with one GDC (*arrows*). The parent vessel is preserved.

#### Case 2

A 66-year-old man had suffered an acute myocardial infarction at the age of 55. Nine years later, coronary artery bypass surgery was performed. On a clinical examination performed several months after surgery, he was found to have a bruit on the right side of his neck, synchronous with the pulse. The question of whether this was an iatrogenic arteriovenous fistula related to jugular vein puncture for placement of a Swan-Ganz catheter at the time of surgery was raised. A transfemoral angiogram demonstrated the presence of a high-flow, small-hole fistula between the right vertebral artery and the perivertebral and perimedullary veins (Figs 2A and B). The size of the shunt was considered too small to be safely closed with a detachable balloon. Under systemic heparinization (3000 U bolus and 1000 U/h intravenously) and after transarterial catheterization of the venous side of the fistula with a Tracker-10 microcatheter (Fig 2C), two GDCs (2 mm in circular memory, 4 cm long and 0.010 in in diameter) were delivered and detached in the proximal venous pouch.

The immediate postembolization angiogram showed some flow through the fistula. However, complete occlusion of the abnormal arteriovenous communication with preservation of the parent vessel was observed 15 minutes later (Fig 2D). The patient remained neurologically intact after the procedure.

#### Discussion

Traumatic high-flow, single-hole, carotid-cavernous and vertebrovertebral arteriovenous fistulas are treated classically with detachable balloons via the endovascular transarterial approach (1-4).

Intravascular coils with smaller diameters than balloons may be used when the orifice of the fistula is smaller than the uninflated diameter of the balloon or when the venous compartment of the fistulous communication is too small to allow safe inflation of the detachable balloon (5, 6).

However, intravascular coils may present some disadvantages. They may not produce occlusion of the fistula because of poor thrombogenicity and the difficulty of achieving dense and compact packing into the fistula (7). Coils may migrate intracranially if displacement and/or recoiling of the tip of the microcatheter occurs during coil placement. Untoward coil embolization of the draining veins (5) may also occur. When a conventional coil is placed in the delivery microcatheter, it may obstruct the microcatheter while being pushed and may not be retrieved. If such a coil appears to be unsuitable for a particular vascular territory, it can not be retrieved, and it may be deposited accidentally in the arterial side of the fistula. This portion may become a source of distal arterial thromboembolism (6).

The recent development of GDCs, soft platinum coils soldered to a stainless steel delivery wire and electrolytically detachable (10, 11), may overcome some of the above-mentioned problems. During the last 3 years, GDCs have been used for treatment of high-risk intracranial aneurysms with encouraging results (8, 9). Currently (December 1994) more than 4000 pa-




Fig 2. Case 2. A, Right vertebral artery injection, early arterial phase, lateral view. A vertebral arteriovenous fistula with a small communication (*arrow*) is visible.

B, The right vertebral artery (*two arrows*), the fistula orifice (*arrow*), and the perivertebral perimedullary veins (*arrowheads*) are visible.

C, The catheterization of the proximal venous compartment of the fistula with a Tracker-10 microcatheter is shown. The tip of the microcatheter (*arrow*) is visible.

D, Postembolization angiogram showing occlusion of the fistula with two GDCs (*arrow*). The parent vessel is preserved.

tients have been treated in a worldwide protocol with this technique. GDCs allowed complete treatment of these two "small-hole" arteriovenous fistulas with preservation of the parent artery.

In case 1 balloon treatment failed because of the impossibility of passing a balloon through the narrow orifice of the fistula. In case 2 this kind of treatment was not attempted for the same reason. Standard coils were not used because it was thought that GDCs would have better safety and efficacy.

A Food and Drug Administration protocol orients the use of GDCs to intracranial aneurysms. Therefore these two patients with arteriovenous fistulas were treated under a deviation of this protocol. An informed consent to the use of GDC was obtained from both patients.

GDCs appear to be thrombogenic. Experimental and clinical studies have shown that they may lead to progressive thrombosis with no recanalization caused by thrombolysis (9, 12).

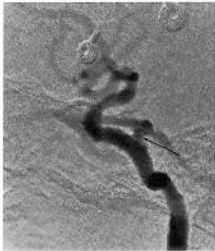
Both fistulas occluded while the patients were under systemic heparinization. Electrothrombosis (10) and/or the significant alteration of the flow through the fistulas (caused by dense coil packing) may have played significant roles in the success of the treatment. It is difficult to assess the role of electrically induced thrombosis in these two cases and whether heparin alters (lessens) the process of electrothrombosis. In the past, *in vitro* experiments on electrothrombosis were always performed using heparinized or citrated blood. *In vivo* experiments were performed with or without heparin, but the authors did not specify the effect of heparin in their experiments. However, Araki was able to ascertain with an experimental animal protocol that heparin markedly reduced electrothrombus formation (13).

GDCs are retrievable; therefore there is less risk of depositing them in untoward locations. If an unsatisfactory position is observed, GDCs can be withdrawn into the microcatheter and repositioned. If an inappropriate size of the

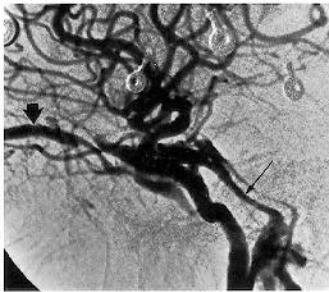GDC has been chosen, it is possible to withdraw it completely and exchange it for a more suitably sized one. This maneuver had to be performed twice in case 1. The decreased risk of suboptimal positioning (ie, retrievability) allowed denser coil packing than standard coils would have in these two cases of arteriovenous fistulas.

## References

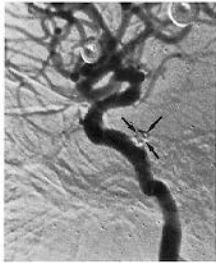1. Debrun GM, Lacour P, Viñuela F, et al. Treatment of 54 traumatic carotid-cavernous fistulas. *J Neurosurg* 1981;55:678-692
2. Debrun G, Legre J, Karbarian M, et al. Endovascular occlusion of vertebral fistulae by detachable balloons with conservation of the vertebral blood flow. *Radiology* 1979;130:141-147
3. Halbach VV, Higashida RT, Hieshima GB. Treatment of vertebral arteriovenous fistulas. *AJNR Am J Neuroradiol* 1987;8:1121-1128
4. Halbach VV, Hieshima GB, Higashida RT, et al. Carotid cavernous sinus fistula: indications for urgent therapy. *AJNR Am J Neuroradiol* 1987;8:627-633
5. Halbach VV, Higashida RT, Hieshima GB, et al. Transvenous embolization of direct carotid-cavernous fistulas. *AJNR Am J Neuroradiol* 1988;9:741-747
6. Halbach VV, Higashida RT, Barnwell SL, et al. Transarterial platinum coil embolization of carotid-cavernous fistulas. *AJNR Am J Neuroradiol* 1991;12:429-433
7. Yang PG, Halbach VV, Higashida RT, et al. Platinum wire: a new transvascular embolic agent. *AJNR Am J Neuroradiol* 1989;9:447-450
8. Guglielmi G, Viñuela F, Dion J, et al. Electrothrombosis of saccular aneurysms via endovascular approach, 2: preliminary clinical experience. *J Neurosurg* 1991;75:8-14
9. Guglielmi G, Viñuela F, Duckwiler G, et al. Endovascular treatment of posterior circulation aneurysms by electrothrombosis using electrically detachable coils. *J Neurosurg* 1992;77:515-524
10. Guglielmi G, Viñuela F, Sepetka I, et al. Electrothrombosis of saccular aneurysms via endovascular approach, 1: electrochemical basis, technique and experimental results. *J Neurosurg* 1991;75:1-7
11. Guglielmi G. Embolization of intracranial aneurysms with detachable coils and electrothrombosis. In: Viñuela F, Halbach VV, Dion J, eds. *Interventional Neuroradiology*. New York: Raven Press, 1992:63-75
12. Guglielmi G, Viñuela F, Briganti F, et al. Carotid-cavernous fistula caused by a ruptured intracavernous aneurysm: endovascular treatment by electrothrombosis with detachable coils. *Neurosurgery* 1992;31:591-597
13. Araki C, Handa H, Yoshida K, et al: Electrically induced thrombosis for the treatment of intracranial aneurysms and angiomas. In: de Vet AC, ed. *Proceedings of the Third International Congress of Neurological Surgery, Copenhagen, 1965*. Amsterdam: Excerpta Medica, 1966 (Vol 110):651-654



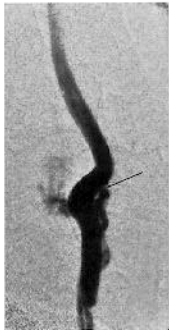
**A**



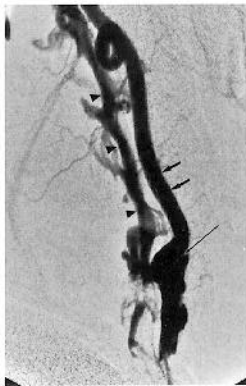**B**



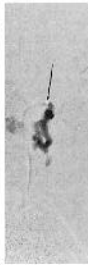**C**



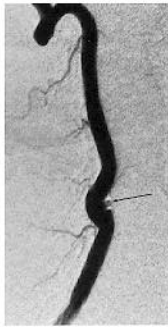A



B



C



D