



Hyperdense middle cerebral arteries identified on CT as a false sign of vascular occlusion.

R A Rauch, C Bazan, 3rd, E M Larsson and J R Jenkins

AJNR Am J Neuroradiol 1993, 14 (3) 669-673

<http://www.ajnr.org/content/14/3/669>

This information is current as
of July 31, 2025.

Hyperdense Middle Cerebral Arteries Identified on CT as a False Sign of Vascular Occlusion

Ronald A. Rauch,¹ Carlos Bazan III,¹ Elna-Marie Larsson,² and J. Randy Jenkins¹

PURPOSE: To evaluate the middle cerebral artery (MCA) on CT, including its relationship to cerebral infarction. **METHODS:** Thirteen patients with either a unilateral or bilateral hyperdense M1 segment of the MCA were evaluated. History of hypertension, diabetes, and hematocrit were obtained and compared with a control group of patients without a hyperdense MCA. **RESULTS:** None of the patients had a unilateral hyperdense MCA ipsilateral to a clinically identifiable stroke. Patients with a hyperdense MCA had a statistically higher hematocrit and also a higher prevalence of hypertension and diabetes mellitus than patients without a hyperdense MCA. The higher hematocrit may have increased the density of the blood, while both diabetes and hypertension are associated with calcification within blood vessel walls. **CONCLUSION:** A hyperdense MCA is not a reliable indicator of occlusion of this vessel or subsequent infarction.

Index terms: Arteries, cerebral, middle (MCA); Arteries, abnormalities and anomalies; Arteries, computed tomography; Brain, infarction

AJNR 14:669–673, May/June 1993

Early diagnosis of stroke is important to clinicians who wish to manage patients optimally through the first stages of this neurologic illness. Using computed tomography (CT) images obtained early in the course of suspected stroke, one can usually rule out other competing diagnoses, such as intraparenchymal hemorrhage, subdural hematoma, subarachnoid hemorrhage, neoplasm, or abscess. However, the typical CT changes in brain tissue associated with stroke are not visible for 24 to 48 hours or more beyond the onset of symptoms (1, 2).

In an effort to find a visual CT correlate with early cerebral infarction, a number of authors have looked at hyperacute findings in stroke (3–13). One of the hyperacute changes frequently described is an increase in the density within the occluded vessel. The earliest report, by Yock et

al, was limited to punctate foci of extremely high density within the involved vessel. This was felt to represent calcified embolic material that had lodged within the occluded vessel. Subsequent articles have used the term hyperdense vessel to mean a vessel that appears more dense than it should be. These hyperdense vessels have been found in patients with acute vessel occlusion and have been thought to be associated with a clot within the visualized vessel.

The cerebral vessel that has most frequently been associated with this hyperdense vessel sign is the middle cerebral artery (MCA). This probably reflects both that occlusion of this vessel is almost never silent (owing to the clinical importance of the region of the brain this vessel supplies) and that the M1 segment of this vessel is typically visible over a long portion of its course on a single CT image. This latter fact results in a striking image of a dense vessel appearing in a hemisphere that is known to be ischemic. At times the ipsilateral hemisphere may become hypodense due to the ischemia. The presence of increased density on CT within a cerebral vessel (and especially the MCA) has been described in patients with angiographically proved occlusion by either thrombosis or embolization (11). These studies have reported an incidence of observation

Received January 23, 1992; accepted after revision August 4.

Presented at the annual meeting of the American Society of Neuroradiology, Washington, DC, June 9–14, 1991.

¹Neuroradiology Section, Department of Radiology, The University of Texas Health Science Center at San Antonio, San Antonio, TX 78284–7800. Address reprint requests to Ronald A. Rauch.

²Present address: Department of Diagnostic Radiology, University Hospital S22185, Lund, Sweden.

AJNR 14:669–673, May/June 1993 0195-6108/93/1403-0669

© American Society of Neuroradiology

of hyperdense MCAs ranging between 1% (3) and 50% (10) in subjects with clinically acute MCA distribution infarction.

If finding a hyperdense vessel is to be helpful, it is important to understand whether false positive cases exist and attempt to understand the cause of these false positives. This study was initiated because of the relatively high frequency at which hyperdense vessels (particularly the MCA) are observed on noncontrast CT scans at our institution in the absence of clinical evidence of MCA occlusion. For the purpose of this study, a hyperdense vessel was defined as a vessel that appeared more dense than it "should," specifically more dense than the adjacent brain on CT. While this manuscript was in preparation, Tomsick et al defined a hyperdense MCA as a vessel that is more dense than the MCA on the other side or more dense than the vascular sinuses (14). This definition will be addressed in the Discussion.

Materials and Methods

The noncontrast CT scans of 375 patients referred to the radiology department over a 1-month period were prospectively evaluated for the presence of a hyperdense MCA. The portion of the MCA chosen was the region that corresponded to the angiographic M1 segment of the vessel (see Fig. 1). CT section thickness was 8 to 10 mm. All images were viewed at standard brain window settings. Scans were performed on a Philips Tomoscan 60/TX CT scanner (Philips, Shelton, CT), a Siemens DR 3 CT scanner (Siemens, Erlanger, Germany), or a GE 8800 CT scanner (General Electric, Milwaukee, WI) at one of our two institutions and were initially evaluated by one of four neuro-radiologists.

A hyperdense artery was defined as a vessel that was more dense than the adjacent brain tissue using the adjacent temporal and frontal lobes for comparison (Figs. 1 and 2). All hyperdense vessels initially identified were reviewed by at least three of the neuroradiologists and only those vessels that were definitely hyperdense to brain were accepted in the study group.

Clinical data, including the reason for referral of the patient to the CT scanner, the possibility of MCA infarction accounting for the clinical symptoms, the clinical diagnosis on follow-up examination, hematocrit at the time of the CT scan, and previous history of hypertension and diabetes mellitus were recorded for each patient with a hyperdense MCA. A control group of 75 patients referred for CT during this same period but who did not have a hyperdense MCA was used to compare hematocrit and prevalence of hypertension and diabetes mellitus.

Results

Thirteen patients were found who had at least one hyperdense MCA. Seven patients had bilat-

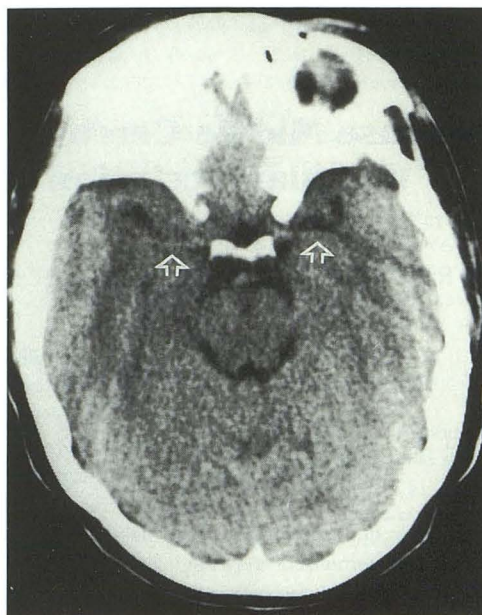


Fig. 1. Patient 12. Noncontrast CT scan through the region of the circle of Willis. The M1 segment of each MCA is more dense than the adjacent brain (arrows).

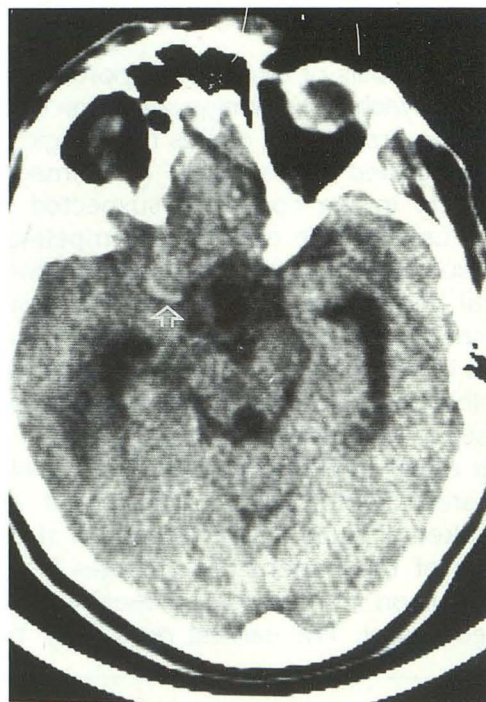


Fig. 2. Patient 5. Noncontrast CT scan through the region of the circle of Willis. The MCA on the right is hyperdense (arrow).

erally hyperdense MCAs; six patients had unilaterally hyperdense MCAs (three on the right and three on the left). The mean age of this group was 52.8 years with a range of 7 to 74 years. Ten of the 13 patients with a hyperdense MCA had a basilar artery that also appeared hyperdense. Of

these 13 patients with a hyperdense MCA, 12 had either an opposite hyperdense MCA or a hyperdense basilar artery. One patient had only a unilateral hyperdense MCA without a hyperdense basilar artery.

The control group consisted of 75 patients each with noncontrast CT scans that did not show evidence of a hyperdense MCA. They had a mean age of 48.5 years (range, newborn to 95 years). There was no statistically significant difference between the ages of these patients and those with hyperdense MCAs.

Of the 13 patients with a hyperdense MCA, five had no history even vaguely suggesting a cerebral infarct (see Table 1) and none of these five developed infarcts in the days following the initial CT scan. Two patients had altered mental status and one had dizziness. On follow-up examination, these three patients were shown to have a metabolic alkalosis and a hyperosmolar state causing mental status change, multiple contusions causing mental status change, and a cerebellar hematoma causing dizziness, respectively. Of the five remaining patients, two had hyperdense MCAs identified in the cerebral hemisphere opposite the side of the confirmed MCA strokes. One patient with bilaterally hyperdense MCAs had transient ischemic attack symptoms of one hemisphere and an old stroke in the opposite hemisphere. The final two patients had bilaterally hyperdense MCAs and confirmed acute unilateral MCA distribution infarcts.

Of the 13 patients with hyperdense MCAs, 10 had documented hypertension (77%); three did not. The control group had 60 patients with medical records adequate to confirm a history of

hypertension or diabetes. Thirteen of the control subjects had hypertension (22%). This difference in the prevalence of hypertension was significant ($p < .01$, using a two-tailed Student *t* test). Six of the patients having a hyperdense MCA had diabetes mellitus (46%). This compares with 11 out of the 60 control patients who had diabetes (18%). This difference was also statistically significant ($P < .05$, using a two-tailed Student *t* test).

Of the patients with hyperdense MCAs, 11 had a hematocrits drawn within 7 days of the CT scan. The mean hematocrit was 43.5% with a range of 36.4% to 52.0%. Of the control group, 65 had hematocrits available within 7 days of the CT scan. These patients had mean hematocrits of 38.8% with a range of 21.0% to 51.9%. This was significantly less than the patients with hyperdense MCAs ($P < .05$, using a two-tailed paired Student *t* test).

Discussion

Early positive identification of a clinically suspected disease is preferable to making a diagnosis by exclusion. This is true in cerebral infarction at present, and may become even more important if better therapeutic mechanisms are developed for treating the occluded vessel that has caused the stroke. Interest in the hyperdense MCA as an early sign of vascular occlusion has been raised by a number of authors who have shown that a hyperdense MCA may be present in early MCA infarction secondary to thrombosis (3, 12), embolism (13), and subintimal hemorrhage (6). However, the specificity of the sign has not been well

TABLE 1: Patients with hyperdense MCAs

Patient No.	Side of Hyperdense MCA	Presenting Symptoms	Vessel Possibly Involved Clinically	Final Diagnosis
1	Left	Headache	None	No stroke
2	Bilateral	Aphasia, right weakness	Left MCA	Left MCA stroke
3	Right	Aphasia	Left MCA	Left MCA stroke
4	Bilateral	Headache, dizzy	? VB	Cerebellar hematoma
5	Right	Mental status change, trauma	? VB	Multiple contusions
6	Bilateral	Left body tingling	Right MCA	TIA, no stroke
7	Bilateral	Right body weak	Left MCA	Left MCA stroke
8	Bilateral	Altered mental status	? VB	Alkalosis, no stroke
9	Left	V/P shunt malfunction	None	No stroke
10	Right	Right body weak	Left MCA	Left MCA stroke
11	Bilateral	Headache	None	No stroke
12	Bilateral	Trauma	None	No stroke
13	Left	Depression	None	No stroke

Note.—V/P = ventriculoperitoneal; TIA = transient ischemic attack; VB = vertebral basilar.

documented. The present study was designed to examine the clinical significance of a hyperdense MCA as identified on noncontrast CT scans as it related to evidence of an ipsilateral MCA infarct.

Studies that observed hyperdense MCAs in patients with known MCA infarcts noted that for the vessel to appear hyperdense the vessel generally has to be totally occluded by a clot. Such a total occlusion of the MCA would almost certainly be accompanied by the clinical manifestations of MCA infarction. Appropriate neurologic symptoms should be present at the time the hyperdense MCA was visible, if, in fact, the hyperdense appearance of the vessel was due to occlusion of that vessel. Based on this assumption, the clinical record of patients with hyperdense MCAs was evaluated for clinical evidence of MCA distribution infarction.

The data presented in Table 1 and in the Results section showed that no patient had a unilateral hyperdense MCA ipsilateral to an MCA stroke. There were three patients with bilaterally dense MCA infarcts and unilateral MCA acute strokes or transient ischemic attack symptoms. There were also two patients with unilateral hyperdense MCAs and opposite-side MCA infarcts. Thus in our series, we did not find a hyperdense MCA to be predictive of MCA occlusion.

We found that the hyperdense MCA was not specific for MCA occlusion, but we were not able to confirm the cause of the hyperdense MCA appearance on CT. There are at least three possible causes for the MCA to appear hyperdense when compared with the adjacent brain: 1) the contents of the vessel could be hyperdense when compared with the adjacent brain, 2) the walls of the vessel could be hyperdense, and 3) the brain could be hypodense, making the normally dense vessel appear hyperdense by comparison. Regarding the first hypothesis, there are several conditions that could cause the vessel contents to have increased density, including a clot within the vessel, polycythemia, and increased serum density. The possibility that the increased density could be due to a clot was discussed above and, at least in the group of patients studied here, rejected.

We did find that there was a significant difference between the hematocrit in patients with hyperdense MCAs and patients without hyperdense MCAs. However, there was a great deal of overlap in the hematocrit of patients with and without hyperdense MCAs, and many patients with a high hematocrit did not have hyperdense

MCAs. Furthermore, none of the patients was found to have true polycythemia. It was noted that no patient with a hematocrit below 36% had a hyperdense MCAs. These data might allow one to speculate that a higher hematocrit may contribute to the appearance of hyperdense MCAs and that in cases of significant anemia the MCAs are less likely to appear hyperdense. This is to be expected, because a higher hematocrit, with the attendant increase in both iron and protein within the vessel, might be expected to cause the blood to be more dense than blood with a lower hematocrit.

Another cause of increased blood density could be administration of some contrast agent such as iodine or xenon. All records were carefully checked to exclude the use of contrast agents in our patients. Patient ingestion of other substances might also act to raise the blood density. A recent report of a patient with hyperdense MCAs following cocaine abuse (15) shows that patients may take substances that can potentially alter serum density. Toxicology screens were not available for our patients but there was no evidence to suggest cocaine use in the clinical histories available.

Mural calcification certainly could increase the density of the walls of the vessel. Heavily calcified vessel walls should appear as tram track-like densities, clearly distinct from a typical uniform hyperdense vessel. Potentially, however, fine mural microcalcifications might simply give the vessel a more uniform hyperdense appearance. Inasmuch as both hypertension and diabetes mellitus have been implicated as a cause of vascular calcification, the prevalence of these diseases was compared in the patients with and without hyperdense MCAs. There was a statistically significantly higher prevalence of hypertension in patients with hyperdense MCAs (77%) compared with those without hyperdense MCAs (22%). The incidence of diabetes was also statistically significantly higher in patients with hyperdense MCAs (46%) than in those without hyperdense MCAs (18%). This correlation tended to support our belief that some of the hyperdense MCAs might have appeared hyperdense because of vascular calcification. However, not all patients with hyperdense MCAs had diabetes or hypertension, so calcification may not be the cause of hyperdense MCAs in all cases.

One must consider the possibility that the MCA appears hyperdense because the brain is hypodense. If there was an infarct involving the adja-

cent brain tissue, the brain might appear less dense. This might make the adjacent normally dense MCA appear hyperdense by comparison. However, as noted above, the patients in the present study with hyperdense MCAs did not have associated strokes to cause the brains to appear less dense. In addition, the observers were instructed to compare carefully the density of the MCA with brain tissue in several regions of the brain, not just with the nearby temporal lobe. Conceivably, simple atrophy might make the MCA stand out in relief because the vessel would then be surrounded more completely by cerebrospinal fluid than in brains without atrophy. However, each vessel was carefully compared with the density of brain to assure that the hyperdense vessel was truly more dense than the cerebrum.

Hyperdense vessels are seen from time to time in patients with acute occlusion. There are also cases in which serial scans are available that show the appearance and disappearance of a hyperdense vessel over time as the clot lyses and the vessel is recannalized. Recently, a more rigid definition of a hyperdense MCA has been proposed, requiring that the vessel appear not only brighter than adjacent brain, but also brighter than other intracerebral vessels (14). The most likely causes for hyperdense vessels in our patient population generally affect all vessels, and, accordingly, we did find that a number of patients had multiple vessels that were hyperdense. However, even by this more rigid criterion, one patient in our series had a hyperdense MCA (without other hyperdense vessels) and eight of the remaining 12 either had basilar or opposite MCAs that did not appear hyperdense. We feel that this reinforces the importance of considering causes other than occlusion when one observes a hyperdense vessel.

In summary, an occluded vessel, particularly one occluded by a calcified thrombus or embolus, can appear hyperdense on CT. The purpose of this study was to show that there may be causes other than occlusion for the MCA to appear very dense. In our patient population, there were sta-

tistically significant differences between groups of patients with and without hyperdense MCAs in terms of hematocrit and history of hypertension and diabetes.

Acknowledgments

We would like to thank Cono Farias for assistance in photographic reproduction.

References

1. Bryan RN, Levy LM, Whitlow WD, Killian JM, Preziosi TJ, Rosario JA. Diagnosis of acute cerebral infarction: comparison of CT and MR imaging. *AJNR: Am J Neuroradiol* 1991;12:611-620
2. Inoue Y, Takemoto K, Miyamoto T, et al. Sequential computed tomography scans in acute cerebral infarction. *Radiology* 1980;135:655-662
3. Gacs G, Fox AJ, Barnett HJM, Vinuela F. CT visualization of intracranial arterial thromboembolism. *Stroke* 1983;14:756-762
4. Tomsick TA, Brott TG, Olinger CP, et al. Hyperdense middle cerebral artery: incidence and quantitative significance. *Neuroradiology* 1989;31:312-315
5. Tomsick TA, Brott TG, Chambers AA, et al. Hyperdense middle cerebral artery sign on CT efficacy in detecting middle cerebral artery thrombosis. *AJNR: Am J Neuroradiol* 1990;11:473-477
6. Pressman BD, Tourje EJ, Thompson JR. An early sign of ischemic infarction: increased density in a cerebral artery. *AJNR: Am J Neuroradiol* 1987;8:645-648
7. Granstrom P. CT visualization of thrombus in cerebral artery. *J Comput Assist Tomogr* 1986;10:541-548
8. Schuere G, Huk W. The unilateral hyperdense middle cerebral artery: an early CT sign of embolism or thrombosis. *Neuroradiology* 1988;30:120-122
9. Schuknecht B, Ratzke M, Hofmann E. The dense artery sign—major cerebral artery thromboembolism demonstrated by computed tomography. *Neuroradiology* 1990;32:98-103
10. Bastianello S, Pierallini A, Colonnese C, et al. Hyperdense middle cerebral artery CT sign. *Neuroradiology* 1991;33:207-211
11. Yock DH. CT demonstration of cerebral emboli. *J Comput Assist Tomogr* 1981;5:190-196
12. Sasiadek M, Wasik A, Marciniak R. CT appearance of bilateral, acute thrombosis of the main cerebral arteries. *Comput Med Imaging Graphics* 1990;14:89-90
13. Tomura N, Inugami A, Kanno I, et al. Differentiation between cerebral embolism and thrombosis on sequential CT scans. *J Comput Assist Tomogr* 1990;14:26-31
14. Tomsick T, Brott T, Barsan W, Broderick J, Haley EC, Spilker J. Thrombus localization with emergency cerebral CT. *AJNR: Am J Neuroradiol* 1992;13:257-263
15. Hall A, Wagle V. CT enhancement after use of cocaine. *AJNR: Am J Neuroradiol* 1990;11:1083.