



Discover Generics

Cost-Effective CT & MRI Contrast Agents



WATCH VIDEO

AJNR

MR imaging of intraventricular cysticercosis.

B L Ginier and V C Poirier

AJNR Am J Neuroradiol 1992, 13 (4) 1247-1248

<http://www.ajnr.org/content/13/4/1247>

This information is current as
of June 22, 2025.

MR Imaging of Intraventricular Cysticercosis

Bruce L. Ginier¹ and Virginia C. Poirier^{1,2}

Summary: Intraventricular cysticercoses cysts can migrate through the ventricular system and produce hydrocephalus. MR is more sensitive than CT in the detection of these cysts.

Index terms: Brain, parasites; Cysticercosis

An unusual case of neurocysticercosis is presented in which there is magnetic resonance (MR) imaging documentation of an intraventricular cyst migrating from the lateral ventricle into the third and fourth ventricles. This cyst was not visible on the initial computed tomography (CT) exam. The patient experienced intermittent episodes of acute hydrocephalus during this 2-year period of observation and ultimately the cyst was surgically removed. In this instance, MR was more sensitive than CT in detecting the intraventricular cyst and prevented the potential serious risk of death from acute obstructive hydrocephalus due to cyst migration.

Case Report

A 30-year-old Hispanic man, who immigrated from Mexico 10 months earlier, awoke with headache, nausea, and vomiting. He presented to the Emergency Department at the UC Davis Medical Center (UCDMC) in August 1987 disoriented to place and time. No focal neurologic deficits were detected. An initial toxicology screen was negative. A CT brain scan revealed hydrocephalus with multiple round parenchymal hypodensities and scattered calcifications consistent with neurocysticercosis. No intraventricular cysts were identified. A ventriculostomy was performed. The patient was placed on a 10-day course of praziquantel for suspected neurocysticercosis that was later confirmed by serum titers. An MR exam of the brain performed 2 days after admission demonstrated a cyst in the anterior horn of the right lateral ventricle that was not visible on the previous CT scan. The patient was given a ventriculoperitoneal shunt, and his clinical status slowly improved over the next 3 weeks.

MR exam of the brain performed 1 month after initial presentation revealed migration of the cyst from the anterior horn of the right lateral ventricle into the third ventricle (Figures 1A and 1B). There was no hydrocephalus at this time and the patient was asymptomatic. The parenchymal cysts had diminished significantly in size.

The patient returned to UCDMC one week after this MR exam complaining of headache and gait disturbance. A CT brain scan demonstrated an interval increase in size of the lateral ventricles. The cysticercosis cyst remained in the third ventricle. A ventricular shunt revision was performed and the patient's symptoms subsided.

A follow-up MR examination performed 5 months later demonstrated a cyst in the fourth ventricle with no residual cyst in the third ventricle (Figure 2). The patient was asymptomatic and there was no evidence of hydrocephalus.

The patient did well for 2 years until March 1990 when he was admitted to UCDMC with persistent headaches. An MR exam of the brain now demonstrated a cysticercosis cyst within the fourth ventricle. No residual parenchymal cysts were present. The patient underwent a suboccipital craniotomy with excision of the fourth ventricular cyst and has had no further clinical manifestations of his neurocysticercosis for the past year.

Discussion

The CT and MR appearance of neurocysticercosis has been well documented (1–5). MR imaging plays a significant role in the early detection of intraventricular cysticercosis cysts. The T1-weighted images readily demonstrate the cyst wall and hyperintense scolex, even though the cyst fluid is usually isointense to cerebrospinal fluid (CSF). It is known that with cyst degeneration, cyst fluid becomes more gelatinous and proteinaceous, which is manifest as increased signal intensity of the cyst fluid on T1 and proton density sequences (4). The majority of intraventricular cysts are not readily demonstrable on T2-weighted MR images due to the similarity of cyst

Received June 12, 1991; revision requested July 17; revision received on October 21 and accepted on October 30.

¹ Department of Radiology, University of California Davis Medical Center, Sacramento, CA.

² Address reprint requests to Virginia C. Poirier, MD, University of California Davis Medical Center, Department of Radiology, 2516 Stockton Blvd., TICON II, Sacramento, CA 95817.

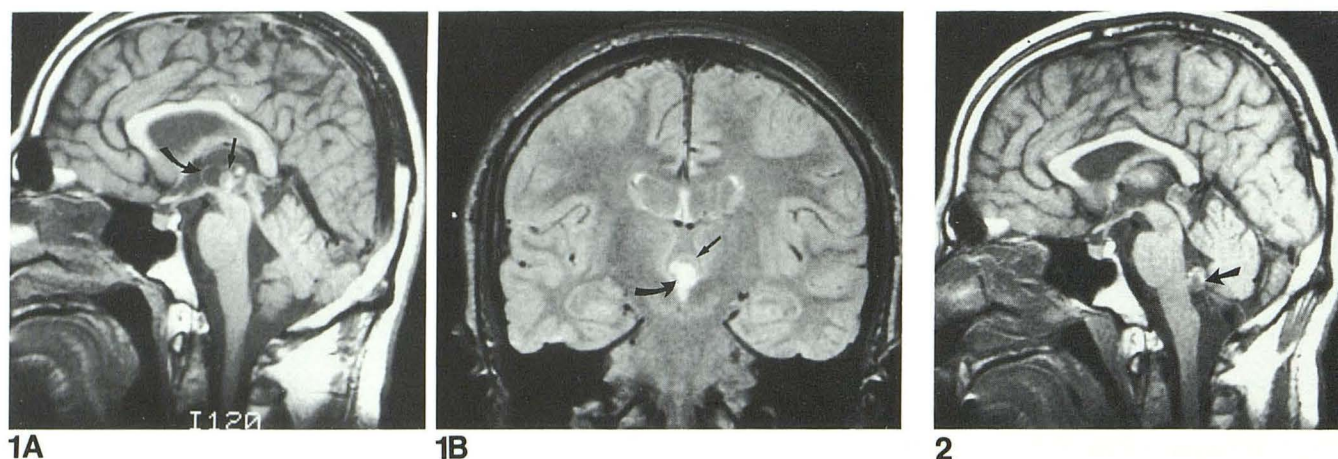


Fig. 1. A, Sagittal T1-weighted (500/20) (TR/TE) MR image demonstrates a neurocysticercosis cyst with a high-intensity mural nodule in the third ventricle. The cyst wall (*curved arrow*) and scolex (*straight arrow*) are identified.

B, Proton density-weighted (3000/30) (TR/TE) MR image in the coronal plane confirms the presence of a cyst in the third ventricle. The cyst wall (*straight arrow*) and the scolex (*curved arrow*) are higher intensity than the ventricular CSF and the cyst fluid.

Fig. 2. T1-weighted midline sagittal MR image (600/20) (TR/TE) demonstrates migration of the neurocysticercosis cyst into the fourth ventricle. The high intensity scolex (*arrow*) is easily identified in the floor of the fourth ventricle.

fluid and CSF, but are readily demonstrated on the proton density images.

Prior to the advent of MR imaging, intraventricular cysticercosis cysts were difficult to visualize noninvasively. The cysts are isodense to CSF with CT imaging and the thin wall and scolex are seldom visualized. Intraventricular cysts were found in 54% of 26 patients studied with MR in a recent series (4). The fourth ventricle is a favored location for intraventricular cysticercosis cysts. The cysts may remain clinically silent until they degenerate, or until they cause obstructive hydrocephalus.

Reports in the surgical literature prior to the advent of praziquantel therapy generally advocated removal of intraventricular cysts in order to prevent acute hydrocephalus and death (6). Six patients with free-floating fourth ventricular cysts reported by McCormick et al (7) had recurrent episodes of abrupt positional headache accompanied by sudden ataxia, vertigo, or drop attacks. Zee reported six deaths due to acute obstructive hydrocephalus in a group of 46 patients with intraventricular cysticercosis cysts (8).

None of the 14 patients with intraventricular cysts reported by Teitelbaum et al (4) showed appreciable changes on repeat MR exams 6 weeks to 6 months post full course of praziquantel therapy. This suggests that the concentration of praziquantel in the CSF was not sufficiently

high to destroy the viable larvae despite concurrent degeneration of some parenchymal cysts. Intraventricular shunts seem to remain patent more frequently in praziquantel-treated patients. If the intraventricular cyst is not mobile or there is associated ventricular ependymitis, removal of the cyst proved to be more difficult and dangerous. Thus, the current surgical operation of choice is merely ventricular shunting. In patients where there is imaging documentation of ventricular cyst migration without associated ependymitis, as in the case presented here, surgical removal should be seriously considered.

References

1. Byrd SE, Locke GE, Biggers SK, et al. The computed tomographic appearance of cerebral cysticercosis in adults and children. *Radiology* 1982;144:819-823
2. Kramer LD, Locke GE, Byrd SE, et al. Cerebral cysticercosis: documentation of natural history with CT. *Radiology* 1989;174:459-462
3. Suh DC, Chang KH, Han MH, et al. Unusual MR manifestations of neurocysticercosis. *Neuroradiology* 1989;31:396-402
4. Teitelbaum GP, Otto RJ, Lin M, et al. MR imaging of neurocysticercosis. *AJR* 1989;153:857-866
5. Zee C-S, Segall HD, Boswell W, et al. MR imaging of neurocysticercosis. *J Comput Assist Tomogr* 1988;12:927-934
6. Keane JR. Death from cysticercosis: seven patients with unrecognized obstructive hydrocephalus. *West J Med* 1984;140:787-789
7. McCormick GF, Zee C-S, Heiden J. Cysticercosis cerebri: review of 127 cases. *Arch Neurol* 1982;39:534-539
8. Zee C-S, Segall HD, Apuzzo MLJ, et al. Intraventricular cysticercosis: further neuroradiologic observations and neurosurgical implications. *AJNR* 1984;5:727-730