



Discover Generics

Cost-Effective CT & MRI Contrast Agents



WATCH VIDEO

AJNR

Crossed cerebellar diaschisis: occurrence and resolution demonstrated with PET during carotid temporary balloon occlusion.

J A Brunberg, K A Frey, J A Horton and D E Kuhl

AJNR Am J Neuroradiol 1992, 13 (1) 58-61

<http://www.ajnr.org/content/13/1/58.citation>

This information is current as
of June 26, 2025.

Crossed Cerebellar Diaschisis: Occurrence and Resolution Demonstrated with PET During Carotid Temporary Balloon Occlusion

James A. Brunberg,¹⁻³ Kirk A. Frey,^{2,4} Joseph A. Horton,¹ and David E. Kuhl,^{1,4}

Summary: The authors describe the early occurrence and quick resolution of crossed cerebellar diaschisis in 54-year-old woman undergoing test occlusion of a carotid artery.

Index terms: Positron emission tomography (PET); Cerebral blood flow; Arteries, carotid; Interventional neuroradiology, complications of

Diaschisis is the depression of regional neuronal metabolism and cerebral blood flow (CBF) caused by dysfunction in an anatomically separate but functionally related neuronal region. It is most commonly recognized in association with stroke. Over 50% of patients with well-defined cerebral hemispheric lesions demonstrate crossed cerebellar diaschisis (CCD) as diminished CBF, oxygen consumption ($CMRO_2$), or glucose consumption ($CMRGlu$) in the opposite cerebellar hemisphere (1-3); or demonstrate diminished $CMRGlu$ in the ipsilateral thalamus or visual cortex (4). CCD has also been demonstrated with malignant hemispheric glioma (5) and following the injection of intracarotid sodium Amytal (6). Diaschisis can occur at the cortical surface of a hemisphere that contains a deep lesion (4, 7) and can involve the intact cerebral hemisphere opposite the side of a supratentorial lesion (8). Although clinical signs of cerebellar dysfunction may be difficult to differentiate in CCD because of associated limb paresis (9), cortical diaschisis occurring with deep hemispheric lesions can be

clearly manifested as language or neuropsychologic dysfunction (10).

Diaschisis is postulated to result from diminished excitatory afferent trans-synaptic neuronal input into otherwise normal neurologic tissue. The duration of time required for diaschisis to be manifested and to resolve has been incompletely studied. The purpose of this report is to describe the early occurrence and prompt resolution of CCD in a patient undergoing positron emission tomography (PET) measurements of CBF during and after balloon test occlusion of the right internal carotid artery.

Case Report

A 54-year-old right-handed woman with a 3-cm unclipable wide-necked aneurysm of the supraclinoid right internal carotid artery (ICA) underwent temporary balloon occlusion of the right ICA to determine whether permanent occlusion could be safely accomplished. Assessment was performed with quantitative PET (Siemens 931/08-12 tomograph, Siemens Gammasonics, Inc, Hoffman Estates, IL) CBF determination using bolus injection of [^{15}O]H $_2$ O and clinical determination of patient response. With ICA occlusion and intravenous injection of [^{15}O]H $_2$ O, the patient developed a left hemiparesis in approximately 60 sec. Her symptoms promptly resolved with balloon deflation. CBF determination during occlusion (Fig. 1) indicated cortical flow to the right hemisphere in the distribution of the anterior and middle cerebral arteries to be approximately 10 mL/100 gm per min. CBF in the cortex of the left cerebellar hemisphere was diminished at 45 cc/100 gm

Received March 27, 1991; revision requested May 31; revision received June 28; final acceptance August 2.

¹ Department of Radiology, UH B2 B311, University of Michigan Hospitals, Ann Arbor, MI 48109-0030.

Address reprint requests to J. A. Brunberg.

² Department of Neurology, University of Michigan Hospitals, Ann Arbor, MI 48109-0030.

³ Department of Surgery, University of Michigan Hospitals, Ann Arbor, MI 48109-0030.

⁴ Department of Internal Medicine, University of Michigan Hospitals, Ann Arbor, MI 48109-0030.

⁵ Present address: University of Pittsburgh, Pittsburgh, PA 15260-0001.

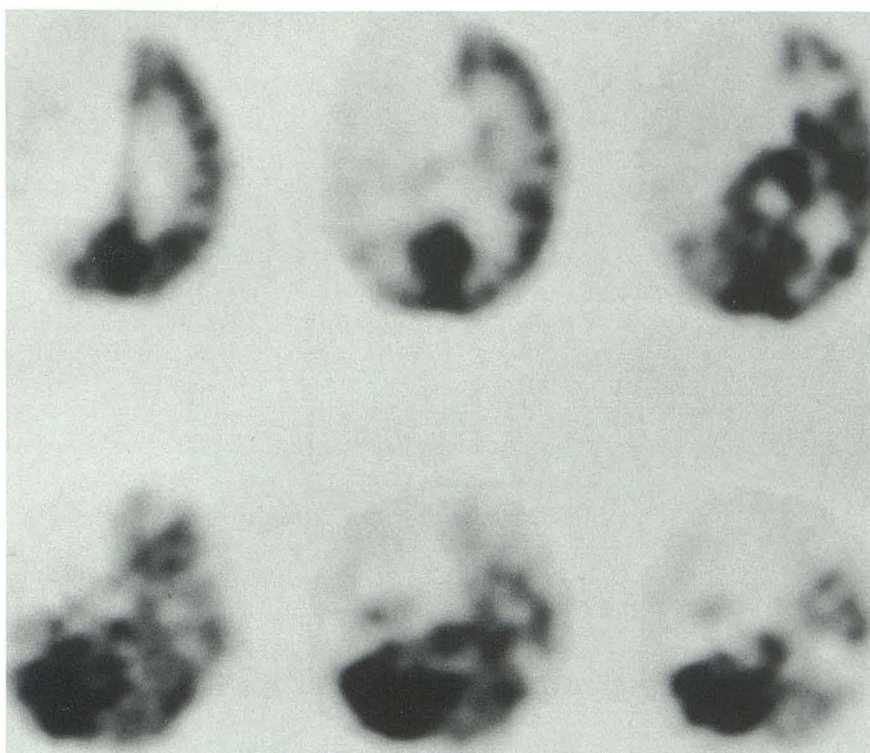


Fig. 1. PET [^{15}O]H $_2$ O determination of CBF with temporary balloon occlusion of the right ICA. Axial 6.75-mm thick contiguous images parallel to the canthomeatal line through the posterior fossa demonstrate diminished CBF in the left cerebellar hemisphere. Selected images of the cerebral hemispheres show decreased CBF in the distribution of the right middle and anterior cerebral arteries.

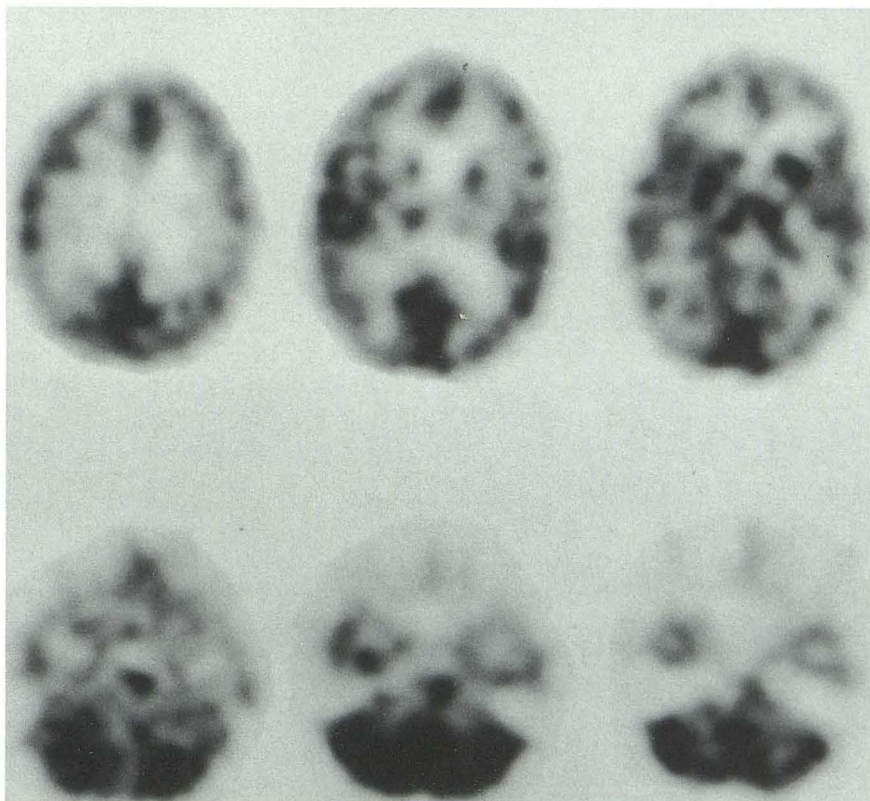


Fig. 2. Repeat PET [^{15}O]H $_2$ O determination of CBF 15 min after right ICA balloon deflation. There is normal right cerebral and left cerebellar hemisphere CBF.

per min, with right cerebellar CBF normal at 71 cc/100 gm per min. After 15 min, a repeat PET study without ICA occlusion showed CBF in the cerebral and cerebellar hemispheres to be normal (Fig. 2).

Discussion

Crossed cerebellar diaschisis, the metabolic depression of the cerebellar hemisphere contralateral to a supratentorial lesion, has been shown to occur in association with infarction (1, 2), tumor (5) and intraarterial bolus of Amytal (6). Such functional depression has been measured with PET as diminished CBF (1, 11), CMRO₂ (1, 7), and CMRGlu (5, 7); and as diminished [¹²³I] HIPDM uptake with planar (12) or single photon emission computed tomography (SPECT) nuclear imaging (2, 3, 5, 6). CCD is postulated to occur secondary to the interruption of extensive polysynaptic, crossed, predominantly excitatory cortico-ponto-cerebellar pathways terminating in the cerebellar granular cell layer; or secondary to the interruption of ascending spinocerebellar pathway input associated with hemiparesis. The reduced cerebellar blood flow associated with CCD appears to be due to functional parenchymal deactivation rather than primary vascular dysfunction. Vascular reactivity remains intact to acetazolamide (11), though exaggerated to hypercarbia (13).

The duration of time required for the development and resolution of diaschisis has not been established. Although most studies of diaschisis have been conducted on patients with subacute or chronic lesions, SPECT studies after intracarotid sodium Amytal administration have demonstrated CCD when intravenous Tc99m-HMPAO is injected as early as 20 sec after intracarotid Amytal administration (6). CCD manifest by a fall of CBF in the left cerebellar hemisphere in the subject of this report was seen to develop within the 60-sec period of ICA balloon occlusion. The rapid development of CCD with transient right hemisphere ischemia suggests an almost instantaneous response to diminished cortico-ponto-cerebellar and/or spinocerebellar pathway excitatory input.

The development of diaschisis in the patient described in this report was associated with obvious cerebral hemispheric alterations in blood flow and with clinical hemiparesis as indicators of the patient's inability to tolerate ICA occlusion. In continuing PET studies of CBF response to temporary cerebral arterial balloon occlusion, the

occurrence of diaschisis may be a useful indicator of remote neuronal dysfunction. Even in the absence of clinical neurologic alteration, it may be predictive of the inability of the tested cerebral hemisphere to tolerate permanent vessel occlusion.

Although CCD associated with cerebral hemispheric infarction has been thought to persist or to worsen with time (14), reports of spontaneous resolution following stroke are available (1, 3, 15), and CCD has been noted to resolve following successful extra-intracranial bypass (3). The immediate development of PET findings of CCD in the patient reported above and in patients undergoing intraarterial Amytal administration would indicate that transneuronal loss of excitatory afferent input is sufficient for the development of CCD and that transneuronal degeneration need not occur. The complete resolution of CCD and of clinical symptoms on a repeat PET CBF study done within 15 min of balloon deflation would confirm impressions that CCD is initially reversible and unassociated with structural change.

The occurrence of cerebellar volume loss opposite to the side of a chronic cerebral lesion has been attributed to antegrade transneuronal degeneration and to residua of cerebellar neuronal exhaustion when seizures occur secondary to a contralateral cerebral insult (16). Crossed cerebellar atrophy, like CCD, is most commonly seen with infarction in the middle cerebral artery distribution, and is most evident in patients with a history of early childhood infarction or hemorrhage. The role of CCD with associated diminished CBF, CMRGlu, and CMRO₂ in the development of crossed cerebellar atrophy can be postulated.

The fact that diaschisis is not initially demonstrated by computed tomography (CT) or magnetic resonance (MR) imaging may be responsible for the disparate results occasionally provided by functional and anatomic brain imaging (4, 7). Since diaschisis may be initially unassociated with neuronal injury or structural alteration, its occurrence may also provide an explanation for apparent discrepancies between positive clinical findings and negative anatomic imaging. The absence of CT or MR cortical findings in the presence of neurologic findings such as aphasia or other neuropsychologic defects associated with deep hemispheric lesions may relate to diaschisis rather than failure to image structural change.

Clinical manifestations of CCD are difficult to differentiate from those of the inciting lesion since there is generally an associated paretic limb. Clinical findings of contralateral limb dysfunction associated with prefrontal lesions may, therefore, relate in part to the effect of CCD on cerebellar function rather than being entirely secondary to frontal lobe dysfunction. Resolution of neurologic findings associated with cerebral lesions may thus relate to the resolution of diaschisis, as well as to redundancy of neurologic function, behavioral substitution, and the assumption of new function by undamaged tissue (14).

References

1. Pantano P, Baron JC, Samson Y, Bousser MG, DeRouesne C, Comar D. Crossed cerebellar diaschisis: further studies. *Brain* 1986;109:677-694
2. Brott TG, Gelfand MJ, Williams CC, Spilker JA, Hertzberg VS. Frequency and patterns of abnormality detected by iodine-123 armine emission CT after cerebral infarction. *Radiology* 1986;158:729-734
3. Pantano P, Lenzi GL, Guidetti B, et al. Crossed cerebellar diaschisis in patients with cerebral ischemia assessed by SPECT and ¹²³I-HIPDM. *Eur Neurol* 1987;27:142-148
4. Kuhl DE, Phelps ME, Kowell AP, Metter EJ, Selin C, Winter J. Effects of stroke on local cerebral metabolism and perfusion: mapping by emission computed tomography of ¹⁸FDG and ¹³NH₃. *Ann Neurol* 1980;8:47-60
5. Rozenthal JM, Levine RL, Nickles RJ, Dobkin JA, Hanson JM. Cerebral diaschisis in patients with malignant glioma. *J Neuro-Oncol* 1990;8:153-161
6. Kurthen M, Reichmann K, Linke DB, et al. Crossed cerebellar diaschisis in intracarotid sodium amyltal procedures: a SPECT study. *Acta Neurol Scand* 1990;81:416-422
7. Pappata S, Tran Dinh S, Baron JC, Cambon H, Syrota A. Remote metabolic effects of cerebrovascular lesions: magnetic resonance and positron tomography imaging. *Neuroradiology* 1987;29:1-6
8. Dobkin JA, Levine RL, Lagreze HL, Dulli DA, Nickles RJ, Rowe BR. Evidence for transhemispheric diaschisis in unilateral stroke. *Arch Neurol* 1989;46:1333-1336
9. DePiero V, Chollet F, Dolan RJ, Thomas DJ, Frackowiak R. The functional nature of cerebellar diaschisis. *Stroke* 1990;21:1365-1369
10. Demeurisse G, Capon A, Verhas M, Attig E. Pathogenesis of aphasia in deep-seated lesions: likely role of cortical diaschisis. *Eur Neurol* 1990;30:67-74
11. Boggsrud TV, Rootwelt D, Russell D, Nyberg-Hansen R. Acetazolamide effect on cerebellar blood flow in crossed cerebral-cerebellar diaschisis. *Stroke* 1990;21:52-55
12. Shig WJ, Coupal JJ, Magoun S, Pulmano C, Kung HF, Ryo YY. I-123 HIPDM planar brain images demonstrating crossed cerebellar diaschisis. *Clin Nucl Med* 1990;15:34-37
13. Takano T, Nagatsuka K, Ohnishi Y, et al. Vascular response to carbon dioxide in areas with and without diaschisis in patients with small, deep hemispheric infarction. *Stroke* 1988;19:842-845
14. Feeney DM, Baron JC. Diaschisis. *Stroke* 1986;86:817-830
15. Slater R, Reivich M, Goldberg H, Banka R, Greenberg J. Diaschisis with cerebral infarction. *Stroke* 1977;8:684-690
16. Streifling AM, Urich H. Crossed cerebellar atrophy: an old problem revisited. *Acta Neuropathol (Berl)* 1982;57:197-202

Please see the Commentary by Reivich on page 62 in this issue.