



Discover Generics

Cost-Effective CT & MRI Contrast Agents



WATCH VIDEO

AJNR

Selective catheterization and digital subtraction angiography of supraaortic arteries via the transcubital approach: a technical note.

B Tomac and A Hebrang

AJNR Am J Neuroradiol 1991, 12 (5) 843-844

<http://www.ajnr.org/content/12/5/843.citation>

This information is current as
of June 22, 2025.

Selective Catheterization and Digital Subtraction Angiography of Supraaortic Arteries via the Transcubital Approach: A Technical Note

Berislav Tomac¹ and Andrija Hebrang²

During transcubital selective digital subtraction angiography (DSA), difficulties in catheterization of the supraaortic branches may arise as a result of improper catheter design [1, 2]. The catheters used for transfemoral cerebral angiography may not be suited for such studies, and for this reason we designed a new catheter for both transcubital aortic arch angiography and selective or semiselective DSA of the supraaortic vessels. We present our experience with the selective catheterization of the supraaortic branches in 2000 patients.

Materials and Methods

In all cases the new type of Tomac catheter (William Cook Europe, Denmark; Cordis Europe, The Netherlands) and the Philips DSA system were used. Our initial experiences with this catheter have been published previously [3–5]. The polyethylene catheter, 4.5-French or 5.0-French, has two angled bends, the proximal right-angled and the distal sharp-angled. The Tomac catheter is made in three sizes (Fig. 1). The largest catheter (T-1) has a proximal hook length of 3.0 cm, and the smaller catheter (T-2) has a proximal hook length of 2.0 cm. The T-1 catheter has two side holes at the proximal hook and four holes at the distal hook. This catheter is suitable for both initial arch angiography and selective catheterization of all branches in patients with elongated aortic arches. There are four side holes in the T-2 catheter. This catheter is suitable for the aortic arch and for selective DSA in patients with normal nonelongated arches.

The third catheter (T-3) has a shorter proximal and longer distal bend with four side holes near the tip of the catheter. This catheter is suitable for the selective catheterization of the left carotid artery when it originates from the aortic arch near the brachiocephalic trunk, and also makes the selective catheterization of the vertebral artery possible.

The majority of our intraarterial DSA examinations were performed via the right cubital approach. If the right subclavian artery could not be passed, the examination was conducted via the left cubital region. For initial DSA of the aortic arch, we used 12 ml of nonionic contrast medium (Solutrast 300, Byk Gulden) at the rate of 10 ml/sec. After the aortic arch injection was completed, the catheter was pulled back, introduced into the distal part of the aortic arch, and rotated until it reached, one by one, the supraaortic branches. Each of them was evaluated in two or more projections, including the extracranial and intracranial parts (Fig. 2). If selective catheterization was not possible, semiselective opacification of the vessels was performed. The right-sided arteries can be opacified selectively by introducing the tip of the catheter into the brachiocephalic trunk. In all patients with elongated supraaortic arteries (carotid or vertebral) selective opacification of the vessel with patients' heads rotated to the left and right side was performed. In total, we used 40–45 ml of nonionic contrast material for the aortic arch and all selective DSAs.

Good selective or semiselective opacification of the supraaortic branches in two or more projections was obtained. The selective introduction of the catheter into the vertebral artery via this approach was easier than by the transfemoral approach, even when the vertebral artery originated directly from the aortic arch (Fig. 3).

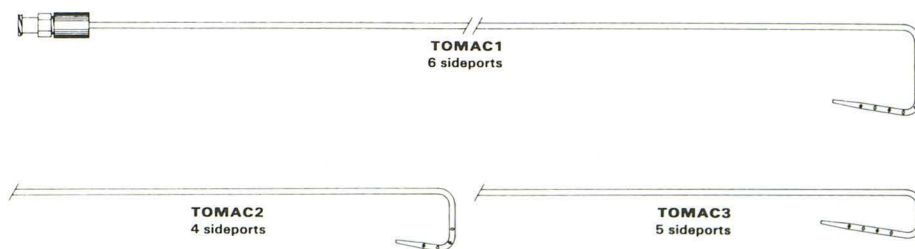


Fig. 1.—Tomac 1–3 catheters for transcubital intraarterial selective and semiselective DSA of supraaortic arteries.

Received October 4, 1989; revision requested December 28, 1989; revision received March 22, 1991; accepted March 22, 1991.

¹ Department of Neuroradiology, St. Johannes Hospital, Hagen, Germany. Address reprint requests to B. Tomac, Regerstr. 16, 5800 Hagen, Germany.

² Department of Radiology, Faculty of Medicine, University of Zagreb, Croatia.

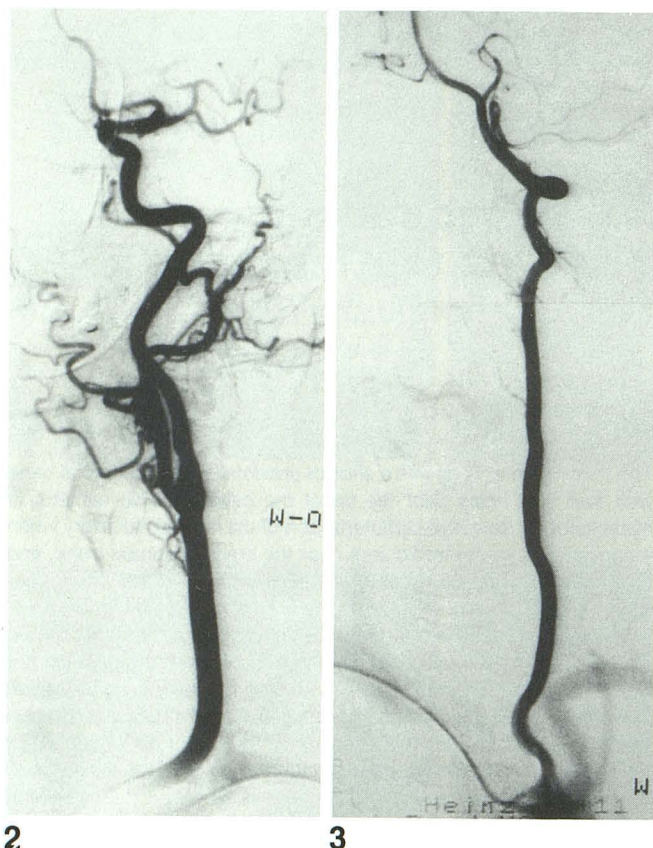


Fig. 2.—Selective transcubital opacification of left common carotid artery with use of Tomac-2 catheter. Minor atherosclerotic changes at proximal part of internal carotid artery are seen. (5 ml of contrast medium at flow rate of 7 ml/sec.)

Fig. 3.—Selective transcubital catheterization of a normal vertebral artery with use of Tomac-1 catheter. (3 ml of contrast medium at the flow rate of 5 ml/sec.) Vertebral artery originated from aortic arch.

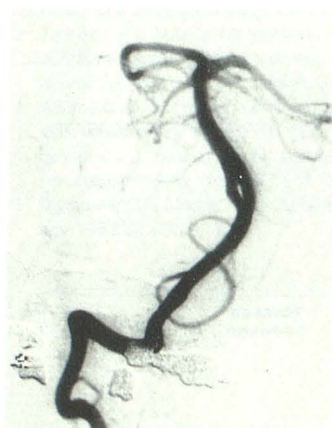

Fig. 4.—Intracranial vascular opacification after selective catheterization of right vertebral artery with use of Tomac-3 catheter. Good visualization of posterior inferior cerebellar artery, anterior inferior cerebellar artery, superior cerebellar arteries, and posterior cerebral arteries is achieved. (3 ml of contrast medium at flow rate of 5 ml/sec.)

The opacification of small intracranial branches of the carotid artery as well as that of the basilar artery can be attained (Fig. 4). We were able to selectively catheterize the left subclavian artery in 100% of the cases and the left carotid artery in 95% of the cases. Semiselective angiography of the left vertebral artery with the tip of the catheter positioned close to the vertebral origin was successful in all cases. The right carotid artery was selectively catheterized in 85%, and semiselectively in the other 15%. The right vertebral artery was selectively catheterized in 88% of the patients, while in 12% good opacification was achieved by the semiselective technique.

For the present purposes, "selective" means that the entire distal and proximal bends of the catheter were in the vessel, whereas "semiselective" means that although the distal end of the catheter did not engage the intended vessel, good opacification was achieved anyway.

Complications occurred in seven patients (0.35%), who had a loss of pulse. Four of them were successfully treated with vasodilatory drugs. In three patients anticoagulant therapy was used. In one (0.05%) of them therapy was unsuccessful and thromboembolectomy was performed. Transitory paresthesia in the area of the peripheral nerves in the hand of the catheterized artery occurred in five (0.25%) cases. There were no central neurologic complications.

Discussion

With our catheter designed especially for transcubital catheter introduction, we have succeeded in obtaining increasingly better visualization of the supraaortic vessels in their extra-cranial parts. The selective transcubital catheterization of the carotid, vertebral, and subclavian arteries has been, in our experience, more successful than use of the transfemoral approach [3]. The selective position of the catheter can be easily achieved in a significantly shorter time by using the transcubital route. If the selective position of the catheter is not possible, a semiselective DSA is recommended. The jet of the contrast medium through the side holes of the newly designed catheters facilitates the opacification of each vessel semiselectively.

On the basis of results obtained in 2000 examinations, we conclude that the newly designed catheter described here offers a very good, low-risk method for performing selective DSA of the supraaortic vessels and is especially suitable for outpatient examinations.

REFERENCES

1. Uchino A. Selective catheterization of the brachiocephalic arteries via the right brachial artery. *Neuroradiology* 1988;30:524-527
2. Morin ME, Williens BA, Kuss BA. Carotid artery: percutaneous transbrachial selective angiography with a 4-F catheter. *Radiology* 1989;171:868-870
3. Tomac B, Hebrang A. New catheter technique for transcubital intraarterial DSA of the aortic arch and the supraaortic vessels. *Neuroradiology* 1989;31:80-84
4. Tomac B, Hebrang A. Selektive ambulante transbrachiale intraarterielle DSA der supraaortalen Arterien. *Fortschr Röntgenstr* 1990;152:191-195
5. Tomac B, Hebrang A. Selektive ambulante transbrachiale intraarterielle DSA der supraaortalen Arterien bei atypischen Abgängen der supraaortalen Arterien. *Fortschr Röntgenstr* 1990;153:423-426