



Discover Generics

Cost-Effective CT & MRI Contrast Agents



WATCH VIDEO

AJNR

A comparison of normal intraarterial digital subtraction angiography with standard angiography in patients with symptomatic cerebrovascular ischemia.

E O Lipchik and M W Mewissen

This information is current as of June 22, 2025.

AJNR Am J Neuroradiol 1990, 11 (4) 837-838
<http://www.ajnr.org/content/11/4/837.citation>

A Comparison of Normal Intraarterial Digital Subtraction Angiography with Standard Angiography in Patients with Symptomatic Cerebrovascular Ischemia

Elliot O. Lipchik¹ and Mark W. Mewissen²

The association between carotid artery disease, transient ischemic attack (TIA), and stroke has been recognized for many years. There still appears to be some controversy over the accuracy of lesion detection with intraarterial digital subtraction angiography (IADSA) as compared with film screen technique. We describe a prospective study that took place over a period of nearly 4 years with 30 consecutive, symptomatic patients who were referred to us for angiography. We compared IADSA with film screen carotid angiograms of the implicated side.

Subjects and Methods

The 30 patients in our series included 15 men and 15 women, 50–81 years old, with most between the ages of 60 and 75 (17 patients). All had symptoms of cerebrovascular ischemia. Five had TIAs that manifested on the left side of the body, six had them on the right side, and one patient had TIA on both sides. One patient had a left temporary stroke with full recovery after 2 days. Seventeen had amaurosis fugax (10 on the right, seven on the left); five of the 17 had observed Hollenhorst plaques [1] (four on the right, one on the left). Seven patients were diabetic, and six had prior coronary artery bypass surgery. Duplex Doppler examinations were done or reported to us in 25 patients: five were entirely normal, 10 were reported as showing plaque but no flow disturbance or vessel narrowing, and 10 were reported as less than 50% narrowing. One in this last group had a question of an ulcer.

Our standard procedure for all patients referred to us for neck carotid angiography is to perform IADSA. Following percutaneous femoral artery catheterization and after arch aortography, a 5-French catheter is selectively introduced into each common carotid artery. Six milliliters of 30% Hypaque (meglumine diatrizoate) is injected over 1 sec for each view of the neck. Six to eight milliliters of the same contrast medium is used for the intracranial circulation. Films are taken at the rate of two to three frames per sec for the neck vessels. Two views of each carotid bifurcation and posteroanterior Towne and lateral views of the intracranial circulation are all standard protocol. For this study, film screen angiography (one view) was added

when the cervical carotid of the symptomatic side showed *no* abnormality on the IADSA study. Therefore, all patients with an abnormal IADSA were excluded. The added film screen angiogram view duplicated the IADSA view that best outlined the contour of the neck vessel in question, almost always the lateral. The contrast medium was changed to 60% Conray (iothalamate meglumine), the timing and volumes remained the same. We did not compare the intracranial angiograms.

All studies were performed on a GE DF5000 (General Electric Medical Systems, Milwaukee, WI) angiographic unit; the IADSA with the 15-cm mode of the image intensifier at 90 cm source-to-intensifier distance. The one-plane film screen studies were done with the same unit, substituting a Puck film changer. Magnification was not used. All films were reviewed by at least two observers.

Results

Only one vessel showed a probable small (1 mm) ulceration on the standard film studies not originally noted on the IADSA (Fig. 1). In retrospect, the small outpouching was shown on the DSA study. This patient did not have surgery so we have no proof of the diagnosis (his symptoms have not recurred). All the other angiographic examinations verified the IADSA and were judged equal in film quality and informational content. There was no difference in evaluation of vessel wall contour although calcium in the walls of the vessels was more clearly defined by IADSA.

Discussion

This study is a comparison of normal IADSA with film screen angiography in the evaluation of symptomatic cerebrovascular ischemia. It was not our purpose to add yet another study to the literature concerning the angiographic diagnosis of carotid artery disease but to compare the quality of IADSA and its true negatives with the "gold standard." Most of the studies were performed in the first 2 years of the 4-year-study be-

Received August 14, 1989; revision requested October 30, 1989; revision received December 13, 1989; accepted December 19, 1989.

¹ Department of Radiology, Medical College of Wisconsin, Milwaukee County Medical Complex, 8700 W. Wisconsin Ave., Milwaukee, WI 53226. Address reprint requests to E. O. Lipchik.

² Department of Radiology, Medical College of Wisconsin, Veterans Administration Medical Center, Milwaukee, WI 53295.

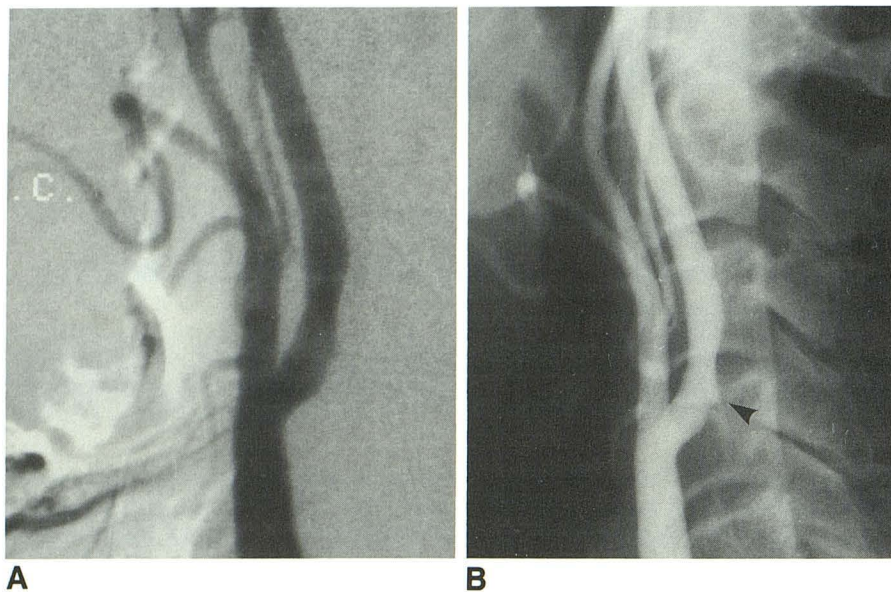


Fig. 1.—A, IADSA of left carotid artery, lateral projection. Mildly narrowing plaque and small outpouching were originally called normal.

B, Film screen technique angiogram of same left carotid artery. A probable small ulcer is noted (arrowhead). The narrowing of the vessel was calculated at 25% diameter. In retrospect, all the abnormal findings are visible on the IADSA but are more obvious on the standard angiogram.

cause of the greater reliance on higher-quality Doppler sonography screens at the present time. We believe we can ease the anxiety of clinicians that very little might be overlooked when presented with IADSA studies of the carotid system. Only one patient had a very small questionable ulcer (unproved) in the posterolateral wall of the proximal internal carotid artery, originally unnoticed on the DSA but seen during the review analysis for this study.

We did not address the issue of the importance of diagnosing ulceration in the absence of stenosis. Difficulties in the accurate diagnosis of ulcers are well known, whether by angiography or sonography [2, 3]. Small ulcers seem to be more benign than large ones [4], and their clinical management is still being argued.

The prognosis of patients with hemispheric TIAs and normal angiograms may not be quite benign [5, 6]. Thirty-five percent of patients in one study [7] had further, severe neurologic events, including severe stroke, in a 5-year follow-up. We believe that IADSA is equivalent to conventional film screen technique in its ability to detect significant lesions in the common carotid bifurcation.

ACKNOWLEDGMENTS

We thank Sylvia L. Bartz for her help in preparing this manuscript and Bernadette Raasch, Gail Morgan, and Carol Gadowski for their technical help.

REFERENCES

1. Hollenhorst RW. The ocular manifestations of internal carotid thrombosis. *Med Clin N Am* 1960;44:897-908
2. Croft RJ, Ellam LD, Harrison MJG. Accuracy of carotid angiography in the assessment of atheroma of the internal carotid artery. *Lancet* 1980;1:997-999
3. Bluth E, McVay LV III, Merritt CRB, Sullivan MA. The identification of ulcerative plaque with high resolution duplex carotid scanning. *J Ultrasound Med* 1988;7:73-76
4. Moore WS, Born C, Malone JM, et al. Natural history of nonstenotic, asymptomatic ulcerative lesions of the carotid artery. *Arch Surg* 1978;113:1352-1359
5. Marshall J, Wilkinson IMS. The prognosis of carotid transient ischemic attacks in patients with normal angiograms. *Brain* 1971;94:395-402
6. Toole JF, Yuson CP. Transient ischemic attacks with normal arteriograms: serious or benign prognosis? *Ann Neurol* 1977;1:100-102
7. Evans WE, Hayes JP. Life history of patients with transient ischemic attacks and essentially normal angiograms. *J Vasc Surg* 1987;6:548-552