



Discover Generics

Cost-Effective CT & MRI Contrast Agents



WATCH VIDEO

AJNR

Azygos Anterior Cerebral Artery Mimicking an Anterior Communicating Artery Aneurysm

Johnson B. Lightfoote, Ronald S. Grusd and Gail Ann Nalls

AJNR Am J Neuroradiol 1989, 10 (5 suppl) S74

http://www.ajnr.org/content/10/5_suppl/S74.citation

This information is current as
of June 8, 2025.

Azygos Anterior Cerebral Artery Mimicking an Anterior Communicating Artery Aneurysm

The CT appearance of intracranial aneurysms has been well described. Though a definitive diagnosis often requires angiography, the CT findings are often highly suggestive of these frequent, potentially lethal, and curable vascular lesions. We recently encountered a patient who had the typical CT findings of intracranial aneurysm but whose arteriographic findings showed a large azygos anterior cerebral artery.

Case Report

A 42-year-old man complained of headache of several months duration. He denied episodes of headache, diplopia, and loss of vision and had no personal or family history of intracranial aneurysm or polycystic kidney disease. High-resolution CT was performed with and without IV contrast material. A 4-mm densely enhancing soft-tissue mass was identified immediately anterior to the suprasellar cistern, in the expected position of the anterior communicating artery (Fig. 1). A punctate calcification was seen also. These findings were thought to be highly suggestive of a saccular unruptured aneurysm of the anterior communicating artery. Intraarterial digital subtraction angiography, with and without cross compression in multiple views, including magnification and transorbital projections, was used to image the right vertebral, left carotid, and right carotid arterial systems. A rather large (4 mm diameter, 1 cm long) azygos anterior cerebral artery was shown, which divided into four vessels (two pericallosal arteries and two callosomarginal arteries) in their typical positions. No intracranial aneurysm was seen.

Discussion

The classical CT findings of intracranial aneurysm include a basal soft-tissue mass, typically measuring up to 13 mm, associated with dense enhancement after administration of IV contrast material and often associated with a punctate or eggshell-type calcification. Such suggestive findings may be seen in as many as two-thirds of patients with angiographically confirmed unruptured aneurysm [1].

The azygos anterior cerebral artery is an uncommon anatomic variant, occurring in 0.3–2.0% of adults. The azygos (meaning “undivided”) artery is a large single midline anterior cerebral artery whose branches supply the medial aspects of both cerebral hemispheres. The artery may divide into single midline or into duplex bilateral parasagittal pericallosal and callosomarginal arteries over a variable distance, though typically this bifurcation occurs distal to the genu of the corpus callosum [2].

Our patient had the typical CT appearance of unruptured aneurysms of the circle of Willis, though this appearance was caused by a large azygos anterior cerebral artery. The punctate focus of calcification likely is an arteriosclerotic calcific plaque near the confluence of the two anterior cerebral artery A-1 segments. There are several literature reports of aneurysms of the azygos anterior cerebral artery [3–8]. Abnormal medial and intimal elements in the vessel wall of this developmental variant may account for the increased prevalence of associated saccular aneurysms and of atypical arteriosclerosis [9].

Though both the azygos anterior cerebral artery and this mimicked appearance are likely quite rare, neuroradiologists should be aware of this potential for misinterpretation, and this developmental variant should be included in the CT differential diagnosis of anterior cerebral and anterior communicating artery aneurysms.

Johnson B. Lightfoote

Ronald S. Grusd

Diagnostic Imaging of Southern California

Sherman Oaks, CA 91403

Gail Ann Nalls

Martin Luther King, Jr., General Hospital

Los Angeles, CA 90059

REFERENCES

1. Nehls DG, Flom RA, Carter LP, Spetzler RF. Multiple intracranial aneurysms: determining the site of rupture. *J Neurosurg* 1985;63(3):342–348
2. Kayemba KN, Sasahara M, Hazama F. Cerebral aneurysms and variations in the circle of Willis. *Stroke* 1984;15(5):846–850
3. Benedetti A, Curri D. Aneurysm of azygos anterior cerebral artery. *Neurochirurgia (Stuttgart)* 1983;26(2):56–58
4. Fujimoto K, Waga S, Kojima T, Shimozaka S. Aneurysm of distal anterior cerebral artery associated with azygos anterior cerebral artery. *Acta Neurochir (Wien)* 1981;59(1–2):65–69
5. Hayashi M, Kobayashi H, Kawano H, Handa Y, Kabuto M. Giant aneurysm of an azygos anterior cerebral artery: report of two cases and review of the literature. *Neurosurgery* 1985;17(2):341–344
6. Katz RW, Haroupan DS, Zingesser L. Aneurysm of azygos anterior cerebral artery: a case report. *J Neurosurg* 1978;48(5):804–808
7. Kondo A, Koyama T, Ishikawa J, Twaki K, Yamasaki T. Ruptured aneurysm of an azygos anterior cerebral artery. *Neuroradiology* 1979;17(4):227–229
8. Niizuma H, Kwak R, Uchida K, Suzuki J. Aneurysms of the azygos anterior cerebral artery. *Surg Neurol* 1981;15(3):225–228
9. Korosua K, Kuwamura K, Okuda Y, Tamaki N, Matsumoto S. Saccular aneurysm arising from a fenestrated anterior cerebral artery. *Surg Neurol* 1983;19(3):273–275

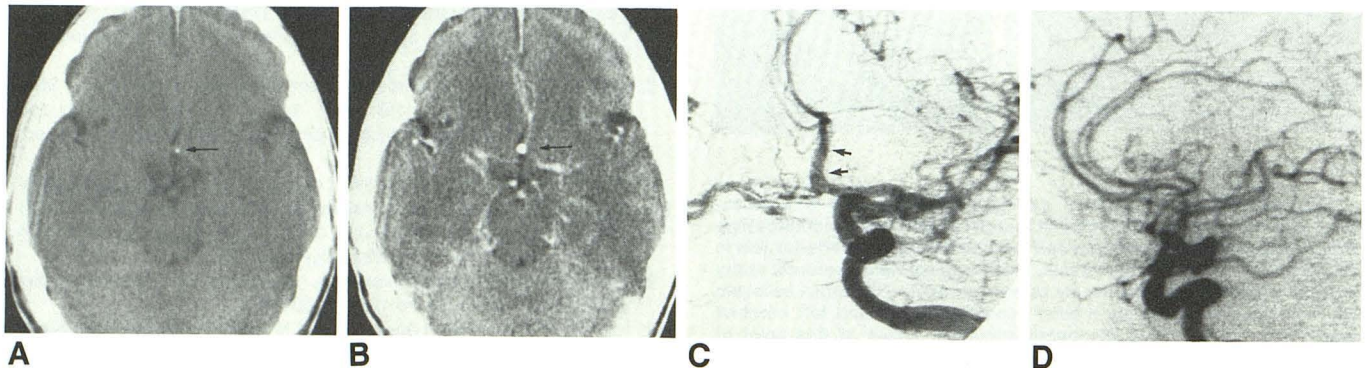


Fig. 1.—Azygos anterior cerebral artery mimicking an anterior communication artery aneurysm.

A, Unenhanced CT scan of brain shows punctate calcific focus in expected position of anterior communicating artery (arrow).

B, Contrast-enhanced CT scan shows a 4-mm mass in expected position of anterior communicating artery, with intense enhancement, highly suggestive of an aneurysm of anterior communicating artery (arrow).

C and D, Digital subtraction arteriograms of left common carotid artery. Transorbital view (C) with cross compression of right common carotid artery shows an azygos anterior cerebral artery supplied primarily by a large left anterior cerebral artery (arrows). Lateral projection (D) without cross compression shows two pericallosal and two callosomarginal arteries supplied by large azygos anterior cerebral artery. Multiple arteriographic projections showed no intracranial aneurysm.