



Discover Generics

Cost-Effective CT & MRI Contrast Agents



FRESENIUS
KABI

WATCH VIDEO

AJNR

Intracranial Osteochondroma: MR and CT Appearance

David W. Beck and Gregg N. Dyste

AJNR Am J Neuroradiol 1989, 10 (5 suppl) S7-S8

http://www.ajnr.org/content/10/5_suppl/S7.citation

This information is current as
of June 7, 2025.

Intracranial Osteochondroma: MR and CT Appearance

David W. Beck¹ and Gregg N. Dyste

Osteochondromas are rare intracranial lesions that have been reported to arise from the skull base and dura. We report a case of a midline osteochondroma arising from the inferior portion of the falx and replacing the midportion of the corpus callosum, and we describe the MR and CT appearances.

Case Report

A 48-year-old right-handed man presented to the University of Iowa for evaluation of unsteadiness of gait over the previous 6 months. He also reported a 1-year history of bifrontal headaches that were worse in the morning and improved during the day. He had experienced good health all his life, and his past history was unre-

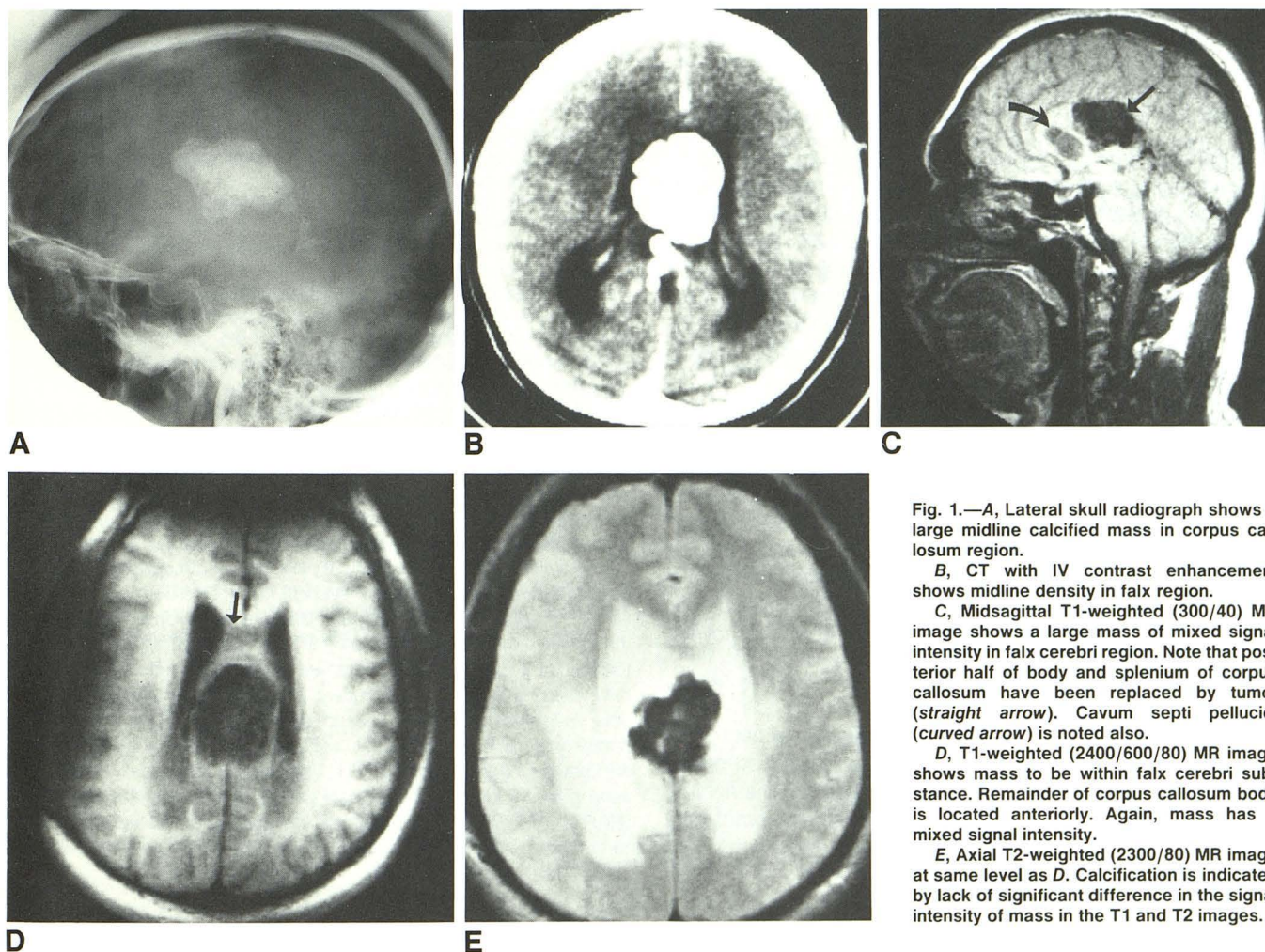


Fig. 1.—A, Lateral skull radiograph shows a large midline calcified mass in corpus callosum region.

B, CT with IV contrast enhancement shows midline density in falx region.

C, Midsagittal T1-weighted (300/40) MR image shows a large mass of mixed signal intensity in falx cerebri region. Note that posterior half of body and splenium of corpus callosum have been replaced by tumor (straight arrow). Cavum septi pellucidi (curved arrow) is noted also.

D, T1-weighted (2400/600/80) MR image shows mass to be within falx cerebri substance. Remainder of corpus callosum body is located anteriorly. Again, mass has a mixed signal intensity.

E, Axial T2-weighted (2300/80) MR image at same level as D. Calcification is indicated by lack of significant difference in the signal intensity of mass in the T1 and T2 images.

Received December 31, 1987; revision requested March 2, 1988; revision received March 18, 1988; accepted April 13, 1988.

¹ Both authors: Division of Neurosurgery, Department of Surgery, University of Iowa Hospitals, Iowa City, IA 52242. Address reprint requests to D. W. Beck.

markable. His general physical examination was normal. His neurologic examination revealed a wide-based, unsteady gait. He had no other neurologic findings. Neuropsychological testing revealed left-hand tactile anomia and a mild alexia and agraphia. In addition, he had a mild left ear extinction on dichotic listening.

Skull radiographs revealed a large calcified mass in the region of the corpus callosum (Fig. 1A). On CT, the mass did not enhance with contrast infusion. The mass was somewhat asymmetric with a larger portion of the tumor on the left side (Fig. 1B). MR imaging localized the mass to the region of the distal body and splenium of the corpus callosum (Fig. 1C). The MR appearance did not change between T1 and T2 images, consistent with the calcification within the tumor (Figs. 1D and 1E).

The patient underwent a left frontoparietal craniotomy with total excision of the tumor via an interhemispheric approach. At surgery, the mass was very hard and required a CO₂ laser for excision. The tumor appeared to rise from the inferior portion of the falx. No corpus callosum was seen in the area of tumor, and it appeared that the mass had completely replaced the posterior body of the corpus callosum. After surgery, the patient had a mild weakness in his right foot, which improved to normal over the next 6 weeks. His neuropsychologic testing 3 months after surgery revealed improvement of his left hand anomia. He had a mildly impaired left-handed agraphia, but this also was improved from preoperative testing. His gait at 3 months was normal.

Discussion

Osteochondroma is the most common benign bone tumor, accounting for 40% of the benign lesions in the Mayo Clinic series [1]. Intracranial osteochondromas are rare. In Cushing's series of 2023 intracranial tumors, only three were osteochondromas [2]. Most of these tumors arise from bones that are embryologically derived from cartilage [3, 4], which accounts for their predilection for the base of the skull [5, 6]. Only some 15% of intracranial cartilaginous tumors have a parafalcine dural attachment as seen in this case.

The radiologic appearance of this tumor is fairly typical but not diagnostic. Skull radiographs show evidence of bony changes caused by local tumor growth, increased intracranial pressure, and areas of tumor calcification [5, 7]. The skull radiographs in this case showed the midline location of the tumor well. The CT appearance of these tumors is variable. Matz et al. [8] reported a large frontoparietal osteochondroma demonstrating a high-density mass with foci of lower densities, producing a honeycomb appearance. The lesion showed

a modest degree of enhancement after contrast infusion. Ikeda [9] reported a middle fossa osteochondroma that demonstrated a high-density, irregularly shaped mass on CT. These findings are similar to those of the present case, in which the mass did not enhance after contrast infusion. The MR appearance of an intracranial osteochondroma has not been reported previously. The appearance of extracranial osteochondromas consists of a mixed signal intensity on both T1- and T2-weighted images [10], which is similar to the MR appearance in this case. The honeycomb appearance on MR conformed well to the findings at surgery of a mixture of soft tumor alternating with prominent areas of calcification. MR was clearly superior to CT in this case in respect to delineation of the local anatomy; this shows the importance of MR in preoperative surgical planning.

Surgical resection is the treatment of choice for cartilaginous falcine tumors [11, 12], and long-term survival is expected [11, 13].

REFERENCES

1. Dahlin DC. *Bone tumors. General aspects and data on 6,221 cases*, 3rd ed. Springfield: Charles C Thomas, 1978:18
2. Cushing H. *Intracranial tumours. Notes upon a series of two thousand verified cases with surgical-mortality percentages pertaining thereto*. Springfield: Charles C Thomas, 1932:8, 133
3. Ettore G, Benedittis G, Bernasconi V. Tumors of the fifth cranial nerve. *Acta Neurochir* 1977;38:37-64
4. Sarwar M, Swischuk LE, Schechter MM. Intracranial chondromas. *AJR* 1976;127:973-977
5. Berkmen YM, Blatt ES. Cranial and intracranial cartilaginous tumours. *Clin Radiol* 1968;19:327-333
6. Gabrielsen TO, Kingman AF Jr. Osteocartilaginous tumors of the base of the skull. Report of a unique case and review of the literature. *AJR* 1964;91:1016-1023
7. Minagi H, Newton TH. Cartilaginous tumors of the base of the skull. *AJR* 1969;105:308-313
8. Matz S, Isreali Y, Shalit MN. Computed tomography in intracranial supratentorial osteochondroma. *J Comput Assist Tomogr* 1981;1:109-115
9. Ikeda Y. Intracranial osteochondroma. *No Shinkei Geka* 1980;3:263-269
10. Hudson TM, Hamlin DJ, Enneking WF, Pettersson H. Magnetic resonance imaging of bone and soft tissue tumors. *Skeletal Radiol* 1984;13:134-136
11. Ozgen T, Necmettin P, Akalan N, Berta V, Onol B. Intracranial solitary chondroma. Case report. *J Neurosurg* 1984;61:399-401
12. Yang PJ, Seeger JR, Carmody RF, Fleischer AS. Chondroma of falx: CT findings. *J Comput Assist Tomogr* 1986;10:1075-1076
13. Hardy RW Jr, Benjamin SP, Gardner WJ. Prolonged survival following excision of dural chondroma. Case report. *J Neurosurg* 1978;48:125-127