



Discover Generics

Cost-Effective CT & MRI Contrast Agents



FRESENIUS
KABI

WATCH VIDEO

AJNR

Fetal Intracranial Hemorrhage and Periventricular Leukomalacia: Complications of Twin-Twin Transfusion

Robert W. Hurst and Patricia L. Abbitt

AJNR Am J Neuroradiol 1989, 10 (5 suppl) S62-S63

http://www.ajnr.org/content/10/5_suppl/S62.citation

This information is current as
of June 6, 2025.

Fetal Intracranial Hemorrhage and Periventricular Leukomalacia: Complications of Twin-Twin Transfusion

We report neurologic damage in twins that was associated with twin-twin transfusion syndrome. Intracranial hemorrhage, detected prenatally, was seen in the larger twin, and periventricular leukomalacia was identified on the first day of life in the smaller twin. Recognition of fetal intracerebral hemorrhage on prenatal sonograms is uncommon; it has been reported only three times [1-3]. The particular neurologic lesions identified in each of these twins can be explained by the pathophysiology present during the fetofetal transfusion syndrome. The combination of findings in association with twin-twin transfusion has not been reported before.

Case Report

A 26-year-old woman, gravida 2, para 1, was evaluated for inappropriate uterine size in the 30th week of pregnancy. Sonography showed a twin gestation with a single placental mass. One twin had polyhydramnios and fetal measurements consistent with 30 weeks of gestation. The other twin, compressed and distorted against the right side of the uterus, did not move and had measurements consistent with 25 weeks of gestation. The diagnosis was twin-twin transfusion. Sonographic evaluation of the larger twin's intracranial contents showed moderate ventricular enlargement with a large hemorrhage in one of the lateral ventricles and hemorrhagic extension into the parenchyma (Fig. 1). Details of the donor twin's head could not be seen because of the absence of amniotic fluid around that twin.

The twins were delivered 1 week later after spontaneous premature rupture of membranes. The larger twin weighed 1360 g and had an initial hematocrit of 49% (0.49). The smaller twin weighed 730 g and had an initial hematocrit of 30% (0.30). Cranial sonography of the larger twin performed the day after delivery showed ventricular enlargement with clot in the right lateral ventricle and extension into the right cerebral hemisphere. The clot was undergoing changes consistent with chronicity. The smaller twin had mild ventricular enlargement and cystic changes in the periventricular regions adjacent to the occipital horns of the ventricles (Fig. 2). This appearance was consistent with periventricular leukomalacia. The larger twin

initially required ventilator support and gradually was weaned to room air. Increasing head circumference and ventricular dilatation led to the placement of a reservoir for ventricular decompression.

The smaller twin died of multiple system failure at 3 weeks of age.

Discussion

Twin-twin transfusion syndrome results from a shunting of blood from one twin to the other through arteriovenous connections in the shared placenta of monozygotic twins. Pathologic studies have shown the presence of such connections in up to 85% of monozygotic twin pairs, which in turn account for approximately 20% of all twins [4]. Often fatal to one or both twins, twin-twin transfusion has been associated with excess neurologic damage in twin pregnancies when compared with singleton pregnancies [5].

In twin-twin transfusion, blood is shunted from one twin to the other, leaving the donor twin anemic and growth retarded while the recipient has polycythemia and increased blood volume. The smaller twin described here had neurologic damage compatible with periventricular leukomalacia, a condition representing infarction in the periventricular area. The development of periventricular leukomalacia requires the presence of two conditions: (1) hypoxic-ischemic damage to produce infarction superimposed on (2) the peculiar vascular anatomic structures of the premature infant.

At gestational ages less than 32 weeks, deep structures of the brain are supplied by the choroidal vessels as well as by penetrating branches of the middle cerebral and posterior communicating arteries. Cortical vessels lead from the surface deep toward the periventricular region. The distal arterial field of the premature brain, therefore, is the periventricular area, and it is here that the first effects of hypoxic-ischemic damage will be manifested [6]. The damage in our case was severe blood loss in the premature donor twin with CNS hypoperfusion. The periventricular watershed areas were the ones affected most severely, and periventricular leukomalacia resulted.

The larger recipient twin had intracranial hemorrhage. The sonographic features were identical to those seen in intraventricular hemorrhage occurring postnatally in premature infants and suggested the germinal matrix as the origin of the hemorrhage.

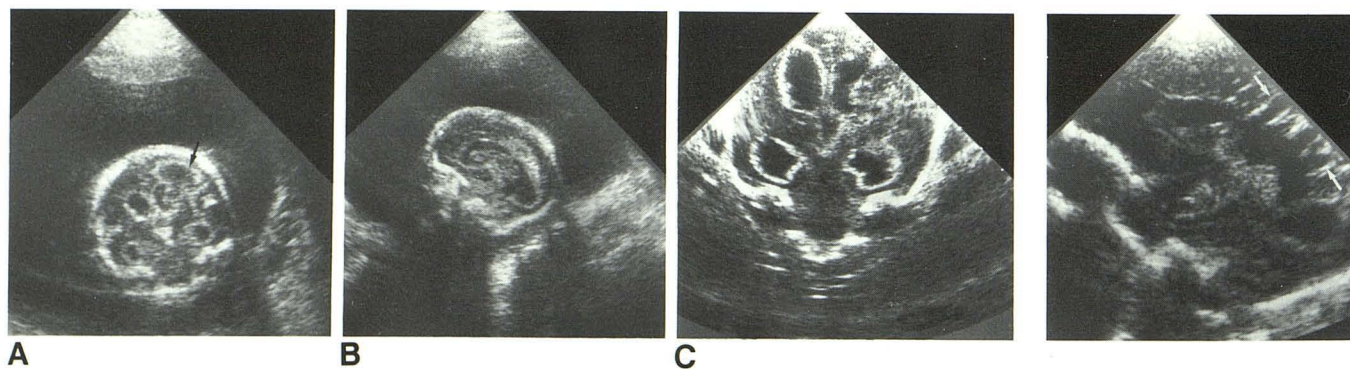


Fig. 1.—A-B, Recipient twin. In utero coronal (A) and sagittal (B) sonograms show ventricular dilatation with intraparenchymal extension of hemorrhage (arrow).

C, Sonogram obtained 1 day after birth confirms presence of prenatal findings.

Fig. 2.—Donor twin. Sagittal sonogram obtained 1 day after birth shows cystic changes of periventricular leukomalacia (arrows).

Germinal matrix hemorrhage, like periventricular leukomalacia, is a distinctive lesion arising from CNS damage superimposed on the anatomic structures of the premature infant. Prominent from 24 to 32 weeks of gestation, the germinal matrix contains extensive immature vessels that are especially susceptible to rupture. Rupture, however, requires some damage, most often of a hypoxic-ischemic nature. Factors that may mediate hypoxic-ischemic damage to the delicate vessels of the germinal matrix include increased blood flow, increased blood volume, increased venous pressure, and endothelial injury [6, 7]. Such conditions appear to be most unusual in utero, occurring instead in the early postnatal period [8].

In the larger twin, the twin-twin transfusion resulted in an increase in circulatory volume. This in turn caused an increase in brain blood flow with subsequent hemorrhage from the germinal matrix.

Robert W. Hurst
Patricia L. Abbitt
University of Virginia Medical Center
Charlottesville, VA 22908

REFERENCES

1. Kim MS, Elyaderani MK. Sonographic diagnosis of cerebroventricular hemorrhage *in utero*. *Radiology* **1982**;142:479-480
2. Lustig-Gillman I, Young BK, Silverman F, et al. Fetal intraventricular hemorrhage: sonographic diagnosis and clinical implications. *JCU* **1983**; 11:277-280
3. McGahan JP, Haesslein HC, Meyers M, Ford KB. Sonographic recognition of in utero intraventricular hemorrhage. *AJR* **1984**;142:171-173
4. Galea P, Scott JM, Goel KM. Feto-fetal transfusion syndrome. *Arch Dis Child* **1982**;57:781-794
5. McCulloch K. Neonatal problems in twins. *Clin Perinatol* **1988**;15(1): 141-158
6. Volpe JJ. *Neurology of the newborn*. Philadelphia: Saunders, **1981**:180-203, 262-289
7. Goldberg RN, Chung D, Goldman SI, Bancalari E. The association of rapid volume expansion and intraventricular hemorrhage in the preterm infant. *J Pediatr* **1980**;96:1060-1063
8. Tsiantos A, Victorin L, Relier JP, et al. Intracranial hemorrhage in the prematurely born infant: timing of clots and evaluation of clinical signs and symptoms. *J Pediatr* **1974**;85:854-859