



**Providing Choice & Value**

Generic CT and MRI Contrast Agents



**FRESENIUS  
KABI**

**CONTACT REP**

**AJNR**

## **MR of Hydranencephaly**

Larry B. Poe and Linda Coleman

*AJNR Am J Neuroradiol* 1989, 10 (5 suppl) S61

[http://www.ajnr.org/content/10/5\\_suppl/S61.citation](http://www.ajnr.org/content/10/5_suppl/S61.citation)

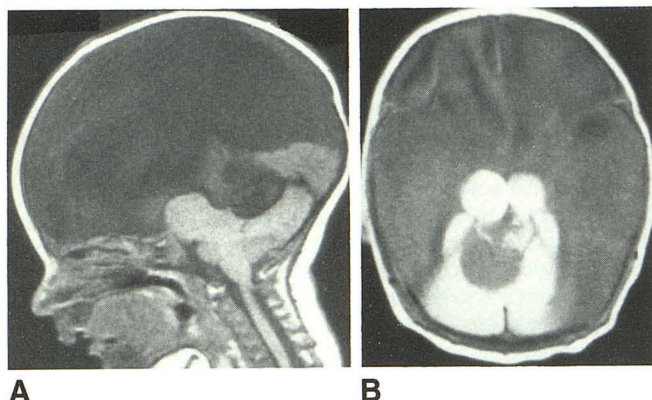
This information is current as  
of July 14, 2025.

## MR of Hydranencephaly

Hydranencephaly is an encephaloclastic disorder characterized by destruction of the cerebral hemispheres and replacement by a thin membranous sac filled with CSF and necrotic debris [1, 2]. We report on MR imaging of a patient with this disorder.

### Case Report

MR imaging (at 1.5 T) was performed on a 6-week-old girl whose history included irritability, retarded motor development, macrocephaly, and recent onset of diabetes insipidus. T1-weighted (spin-echo 600/20 [TR/TE]) and spin-density (1400/20) images in the sagittal and axial planes revealed a fluid-filled supratentorial space with persistence of the falx and relative sparing of posterior fossa structures (Fig. 1).



**Fig. 1.**—MR images of 6-week-old girl with hydranencephaly.  
**A**, SE 600/20. Sagittal image reveals fluid-filled supratentorial space; relative preservation of brainstem and a portion of occipital lobe; hypoplastic cerebellum; anterior thalamic masses.  
**B**, SE 1400/20. Axial image reveals characteristic round unfused thalamic masses with relatively preserved cerebellum. Note anterior interhemispheric fissure and falx, as well as straight sinus posteriorly.

### Discussion

Hydranencephaly is a global CNS encephaloclastic disorder manifested by replacement of the cerebral hemispheres by a thin membranous sac filled with CSF and necrotic debris. The sac represents the relatively intact leptomeninges. Angiography, if performed, confirms the absence or severe hypoplasia of the anterior and middle cerebral arteries and the structures they supply.

The vertebral artery system is intact because there is usually significant preservation of posterior fossa structures and the inferior, posterior portions of the temporal and occipital lobes. Characteristically, small round unfused thalamic remnants are seen [3, 4].

This entity probably reflects infarction of the supraclinoid internal carotid arteries with or without concomitant encephalitis. There are a multitude of reported responsible agents associated with hydranencephaly including maternal syphilis, herpes simplex, toxoplasmosis, and ionizing radiation [5]. The noxious event apparently affects the brain after normal fetal CNS development and neuronal migration (3–6 months). This would account for the presence of the falx, which indicates prior cleavage of the telencephalic vesicles into cerebral hemispheres and is also consistent with the presence of some residual cerebral cortex [3, 5]. T1-weighted MR imaging is the most sensitive method available for examining congenital structural anomalies.

Larry B. Poe  
 Linda Coleman  
 Geisinger Medical Center  
 Danville, PA 17822

### REFERENCES

1. Crome L. Hydranencephaly. *Dev Med Neurol* 1972;14:224–234
2. Halsey J, Allen N, Chamberlin HR. Morphogenesis of hydranencephaly. *J Neurol Sci* 1971;12:187–217
3. Raybaud C. Destructive lesions of the brain. *Neuroradiology* 1983;25:265–291
4. Dublin AB, French BN. Diagnostic image evaluation of hydranencephaly and pictorially similar images, with emphasis on computed tomography. *Radiology* 1980;137:81–91
5. Faerber EN. Congenital anomalies. In: *Cranial computed tomography in infants and children*. Philadelphia: Blackwell Scientific, 1986:42–81