



Providing Choice & Value
Generic CT and MRI Contrast Agents

**FRESENIUS
KABI**

CONTACT REP

AJNR

MR Imaging of AIDS Myelitis

Debra Shabas, Gary Gerard, Burke Cunha, Vidya Malhotra and Norman Leeds

AJNR Am J Neuroradiol 1989, 10 (5 suppl) S51-S52
http://www.ajnr.org/content/10/5_suppl/S51.citation

This information is current as
of July 30, 2025.

MR Imaging of AIDS Myelitis

Debra Shabas,¹ Gary Gerard,² Burke Cunha,² Vidya Malhotra,³ and Norman Leeds³

AIDS myelitis can be difficult to diagnose clinically in the face of a concomitant peripheral polyradiculoneuropathy. Both entities may be caused by viral agents [1, 2]. In this case report, we describe the MR appearance of the initial spinal cord lesion and the subsequently demonstrated resolution of the lesion. To our knowledge, AIDS myelitis has not been demonstrated radiographically in the literature. We have found MR a sensitive and valuable tool in the assessment of spinal cord disease in a patient with AIDS.

Case Report

The patient was a 27-year-old homosexual man with a known diagnosis of AIDS for 17 months. After recovering from *Pneumocystis carinii* pneumonia, two episodes of herpes zoster, cerebral toxoplasmosis abscess, and cytomegalovirus (CMV) chorioretinitis, he was in stable health and doing fairly well until June 1986. At that time, the patient began complaining of right foot paresthesias that gradually (over about 2 weeks) ascended his leg to the groin. Several days later, he noted left toe and sole paresthesias. During the first week in July, the patient noted decreased sensation perirectally and paresthesias in the fourth and fifth digits of the right hand. He denied any weakness, back pain, or incontinence. His neurologic examination was consistent with a polyneuropathy/polyradiculopathy. Nerve conduction studies revealed diffuse, marked slowing compatible with a diagnosis of peripheral polyneuropathy.

Lumbar puncture was done and revealed no WBCs; protein, 77 mg/dl; glucose, 44 mg/dl (peripheral, 90); lactic acid, 1.4; and an elevated IgG/albumin ratio, 0.37. Viral, bacterial, and fungal cultures were negative, as was cytology.

Over the next 10 days, the patient complained of a progressive increase in the paresthesias, extending up to the sternum bilaterally. A sensory level to pin up to approximately T2 was noted. MR of the cervical spine was done at this point and revealed a hyperintense lesion posteriorly at C6–C7 without edema or cord distortion (Fig. 1).

Complete cervical myelography was normal. The CSF revealed four WBCs (100% granulocytes); glucose, 63 mg/dl (134); and protein, 56 mg/dl. Fungal and bacterial cultures were negative. The patient developed a maculopapular thoracic rash, and biopsy was refused. Acyclovir was started for a presumed viral myelitis, thought to represent herpes zoster or herpes simplex; 1 week later, the patient's sensory level progressively descended. Over the next few weeks, his paresthesias resolved to a residual distal stocking and glove sensory loss.

CMV, herpes, and human-T-cell-lymphotropic-virus-III (HTLV III) cultures from CSF were negative, although CSF cultures from a lumbar puncture 1 month later were positive for HTLV III. Repeat MR (after discharge) was normal.

Discussion

Peripheral polyneuropathy in AIDS has been discussed by several investigators [1–5]. Descriptions of the neuropathy in the literature are variable and include (1) a distal, symmetric, predominantly sensory type, (2) an asymmetric, distal, sensorimotor type, (3) a mononeuritis multiplex, and (4) a polyradiculopathy. Electrical studies are usually compatible with a demyelinating neuropathy. The course is variable, ranging from progressive quadriparesis and respiratory failure to total resolution [5]. The precise etiology and pathophysiology are not known, but herpes viruses and HTLV III have been implicated [1, 2, 4].

At the onset, it appeared that our patient had developed the asymmetric, distal, peripheral polyradiculoneuropathy. However, as his symptoms progressed, he developed a sensory level, and a myelitis was indicated. It then became difficult in later stages to determine whether new symptoms were peripheral to or caused by myelitis.

The myelopathies reported in AIDS patients have been caused by cord-compressing lesions, as well as by the direct or indirect effects of viral infection. Two cases of thoracic epidural cord compression were reported in a series of 50 AIDS patients with neurologic involvement, and these cases were found to be due to neoplasms (immunoblastic sarcoma and plasmacytoma) [1]. Burkitt-like lymphoma also has been reported as a cause of cord compression [6]. Myelopathies due to viruses may be caused by primary or secondary mechanisms. Direct cord invasion by virus has been reported to occur with varicella-zoster virus; herpes simplex virus [4, 7, 8]; and recently HTLV III [2] (as documented on postmortem studies). It is not completely clear whether CMV also causes a primary myelitis or is a superinfection [5, 7, 9]. Parainfectious consequences of these viruses include a post-infectious immune-mediated demyelination of the spinal cord, and a parainfectious vasculitis with subsequent cord infarction [4, 7].

Received December 14, 1987; revision requested February 8, 1988; revision received July 21, 1988; accepted August 22, 1988.

¹ Department of Neurology, Beth Israel Medical Center, First Ave. at 16th St., New York, NY 10003. Address reprint requests to D. Shabas.

² Department of Neurology and Department of Infectious Diseases, Winthrop University Hospital, 259 First St., Mineola, NY 11501.

³ Department of Neuroradiology, Beth Israel Medical Center, First Ave. at 16th St., New York, NY 10003.

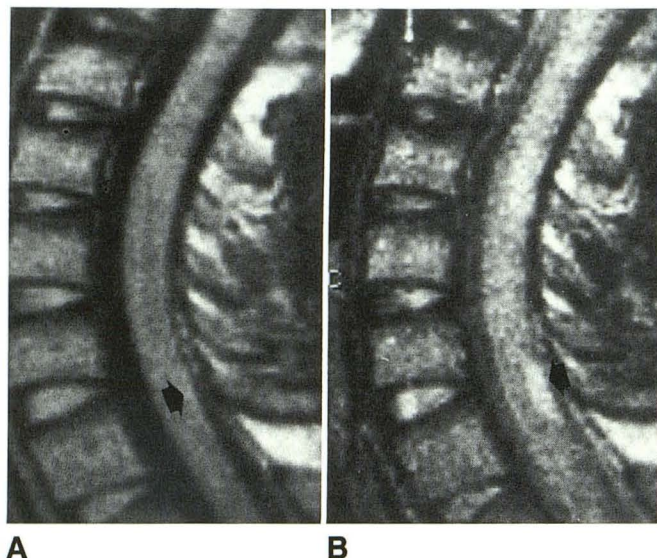


Fig. 1.—A, T1-weighted sagittal MR examination (1000/40) shows an ill-defined, subtle increased signal intensity (arrow).
B, More T2-weighted sequence (1000/80) shows a definite area of increased signal intensity (arrow) in posterior cord over one segment.

The CSF findings in cases of viral myelitis are nonspecific. The virus is not always cultured, and secondary infections are common [4]. Myelography is nearly always negative, and the definitive diagnosis is usually made after death. There are no data on effective therapy for viral myelitis. However, antiviral therapy has been suggested if there is evidence of cutaneous lesions [4].

The case of myelitis in this report was suspected clinically and documented by MR. Whether the abnormalities noted on MR were due to viral infection or to a parainfectious process is not known. A similar MR appearance has been reported in the demyelination of multiple sclerosis, as well as in cord ischemia [10].

The association of polyradiculoneuropathy and myelopathy, as in this patient, has been noted previously and can make precise localization of neurologic deficits difficult [7, 11]. Infections with viruses of the herpes group have been associated with ascending radiculomyelitis and polyneuritis, as well as with myelitis [11].

MR provides documentation of cord disease before death,

which is particularly important when peripheral symptoms may tend to obscure some of the myelopathic signs. Both clinical and radiologic signs can be monitored to evaluate efficacy for therapy, and the diagnosis of cord disease can be made before extensive signs of myelopathy. The differential diagnosis of this MR appearance includes the delayed effects of radiation and the sequelae of trauma, both of which can be ruled out by history. In addition, the possibility of intramedullary neoplasm requires further evaluation. In our patient, myelography was negative and there was complete clinical and MR resolution.

Our patient received antiviral therapy. Whether his clinical recovery was spontaneous or due to treatment is unclear, but the lesion shown on MR resolved completely. The relationship of clinical and radiographic resolution to antiviral therapy needs to be evaluated in controlled studies. In this case, MR was a useful test in assessing the efficacy of viral therapy in an AIDS patient with viral myelitis.

REFERENCES

1. Snider WD, Simpson DM, Nielsen S, et al. Neurological complications of acquired immune deficiency syndrome: analysis of 50 patients. *Ann Neurol* 1983;14:403-418
2. Ho DD, Rota TR, Schooley RT, et al. Isolation of HTLV-III from cerebrospinal fluid and neural tissues of patients with neurologic syndromes related to the acquired immunodeficiency syndrome. *N Engl J Med* 1985;24:313;1493-1497
3. Eidelberg D, Sotrel A, Vogel H, et al. Progressive polyradiculopathy in acquired immune deficiency syndrome. *Neurology* 1986;36:912-916
4. Britton CB, Miller JR. Neurologic complications in acquired immunodeficiency syndrome (AIDS). *Neurol Clin* 1984;2(2):315-335
5. Levy RM, Bredesen DE, Rosenblum ML. Neurological manifestations of the acquired immunodeficiency syndrome (AIDS): experience at UCSF and review of the literature. *J Neurosurg* 1985;62:475-479
6. Ziegler JL, Miner RC, Rosenbaum E. Outbreak of Burkitt's-like lymphoma in homosexual men. *Lancet* 1982;2:631-633
7. Britton CB, Mesa-Tejada R, Fenoglio CM, et al. A new complication of AIDS: thoracic myelitis caused by herpes simplex virus. *Neurology* 1985;35:1071-1074
8. Hogan EL, Krigman MR. Herpes zoster myelitis. *Arch Neurol* 1973;29:309-313
9. Tucker T, Dix RD, Katzen C, et al. Cytomegalovirus and herpes simplex virus ascending myelitis in a patient with acquired immune deficiency syndrome. *Ann Neurol* 1985;18:74-79
10. Edwards MK, Farlow MR, Stevens JC. Cranial MR in spinal cord MS: diagnosing patients with isolated spinal cord symptoms. *AJNR* 1986;7:1003-1005
11. Kabins S, Keller R, Naraqi S, Peitchel R. Viral ascending radiculomyelitis with severe hypoglycorrachia. *Arch Intern Med* 1976;36:933-935