



## Discover Generics

Cost-Effective CT & MRI Contrast Agents

 FRESENIUS  
KABI

[WATCH VIDEO](#)

# AJNR

## Dual-surface-coil MR imaging of bilateral temporomandibular joints: improvements in the imaging protocol.

F G Shellock and B D Pressman

*AJNR Am J Neuroradiol* 1989, 10 (3) 595-598

<http://www.ajnr.org/content/10/3/595.citation>

This information is current as  
of June 23, 2025.

# Dual-Surface-Coil MR Imaging of Bilateral Temporomandibular Joints: Improvements in the Imaging Protocol

Frank G. Shellock<sup>1</sup> and Barry D. Pressman

Surface-coil MR imaging is considered to be an efficacious technique for evaluating temporomandibular joint (TMJ) dysfunction [1–4]. However, several problems are associated with the clinical implementation of MR imaging for TMJ examination. These include (1) the long procedure time required to image both joints with surface coils (this is necessary because of the large number of bilateral abnormalities in patients with internal derangements [5, 6]); (2) the inability or failure to obtain images in standardized perpendicular and parallel planes relative to the long axis of the condylar head (this is difficult to accomplish by using conventional positioning techniques and external landmarks because the angulation of the joint is highly variable [7, 8]); and (3) the lack of diagnostic information concerning motion of the TMJ. Although there have been attempts to address some of these issues [5, 6, 8, 9], not all of the solutions have been entirely satisfactory nor have the various techniques been used together to optimize the imaging protocol. Therefore, in this report we describe the application of recent technological advances that were combined to provide answers to the above-mentioned problems in order to improve the MR imaging technique for examination of the TMJ.

## Materials and Methods

MR imaging was performed with a 1.5-T MR Signa scanner\* using a quadrature body coil as the transmitter and two 6.5-cm receive-only surface coils. The dual surface coils were factory-tuned to 50 ohm and combined with a special RF matching network that matched the output in phase to a 50-ohm impedance. This resulted in a configuration that did not require additional tuning or modification of the surface coils. The dual surface coils were positioned over the right and left TMJs by means of a commercially available surface-coil positioning device\* that allowed the coils to be placed firmly against

the patient's face. This stabilized the patient's head and reduced the potential for motion-related artifacts.

After reviewing the literature, we conducted a pilot project to devise a protocol for static closed-mouth MR imaging of bilateral TMJs in order to optimize (i.e., good diagnostic image quality, proper orientation of imaging planes, etc.) the procedure while keeping imaging time to a clinically acceptable minimum. The imaging protocol we developed is displayed in Table 1 and Figures 1–4.

To obtain diagnostic information related to the motion of the TMJ, kinematic ("kinematic" refers to the motion of a body without reference to force or mass) MR imaging was performed using a TMJ positioning device† to passively open the patient's mouth [9]. Sequential MR images were acquired at the following mouth positions: (1) closed mouth without the positioning device in place, (2) closed mouth with the positioning device placed in between the front incisors, and (3) repeatedly with the mouth open at 20% increments of the maximum, based on a precalculated range of motion for the patient. In this manner, seven positions were typically imaged.

The range of motion was determined by having the patients maximally open their mouths with the positioning device in place to a position that was not forced and did not cause pain. This procedure was repeated three times and the average range of motion was calculated for each patient. The above procedure permitted a standardized assessment of mandibular range of motion and was useful for determining the relationship between the menisci and condyles at specific increments of mouth opening during MR imaging. The protocol used for kinematic MR imaging of bilateral TMJs is described in Table 1.

The kinematic motion display of the MR images was accomplished by using commercially available software\* to produce a cine-loop format [9, 10]. Slices obtained through each of the TMJs were inspected separately, and images at the same location that best depicted the meniscus, condyle, glenoid fossa, and articular eminence were selected (usually a mid-condylar slice) and displayed at a speed that was controlled by a computer track ball [10]. A special VCR interface\* was used to record and archive the kinematic MR images on 1/2-in. VHS video cassettes.

\* General Electric, Milwaukee, WI.

† Medrad, Pittsburgh, PA.

Received June 24, 1988; accepted after revision September 27, 1988.

This work was supported in part by a grant from the General Electric Co., Milwaukee, WI.

<sup>1</sup> Both authors: Department of Diagnostic Radiology, Sections of Magnetic Resonance Imaging and Neuroradiology, Cedars-Sinai Medical Center, Los Angeles, CA 90048. Address reprint requests to F. G. Shellock.



**TABLE 1: Dual-Surface-Coil MR Imaging of Bilateral TMJs: Imaging Protocol**

Series	Plane	TR (msec)	TE (msec)	Matrix	FOV (cm)	Slice Thickness (mm)	Gap (mm)	NEX	No. of Slices	Time (min)
Static closed-mouth views										
1	Axial <sup>a</sup>	400	20	128 × 256	14	3	1	1/2 <sup>b</sup>	9	0:42
2	Obliqued sagittal <sup>c</sup>	800	20	256 × 256	10	3	0.5	2	8	6:57
3	Obliqued coronal <sup>d</sup>	600	20	128 × 256	10	3	0.5	1	8	1:37
Kinematic study										
4	Obliqued sagittal <sup>c</sup>	600	20	128 × 256	10	3	0.5	1	6	1:37

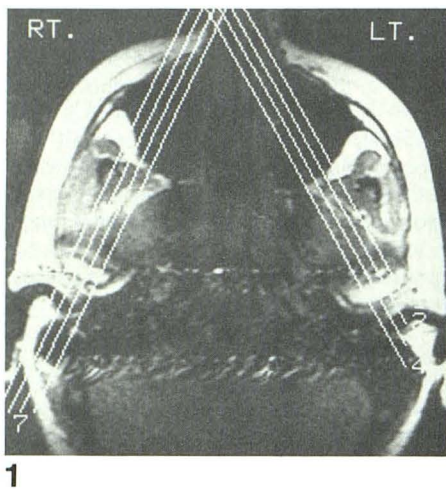
Note.—TR = repetition time, TE = echo time, FOV = field of view, NEX = number of excitations.

<sup>a</sup> Localizer scan.

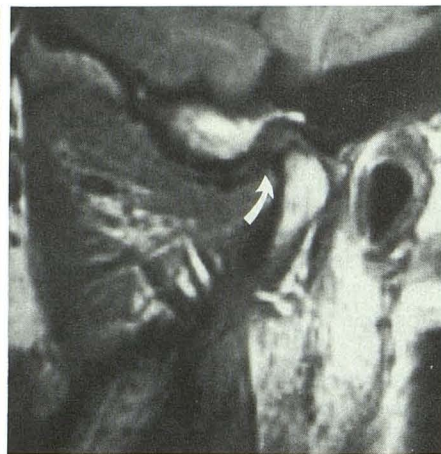<sup>b</sup> Fractional NEX images were acquired from symmetrically conjugated data obtained about the field of view with overscanning in the phase-encoding direction to provide consistent data.

<sup>c</sup> Obliqued sagittal plane images obtained by viewing axial plane localizer and selecting four slice locations by means of graphic prescription software that were perpendicular to the long axis of each of the condylar heads (see examples in Figs. 1 and 2).

<sup>d</sup> Obliqued coronal plane images obtained by viewing axial plane localizer and selecting four slice locations by means of graphic prescription software that were parallel to the long axis of each of the condylar heads (see examples in Figs. 3 and 4).



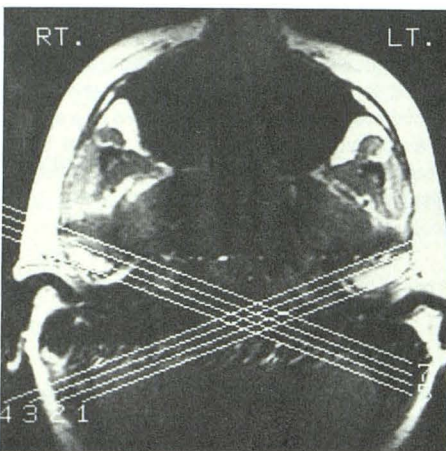
1



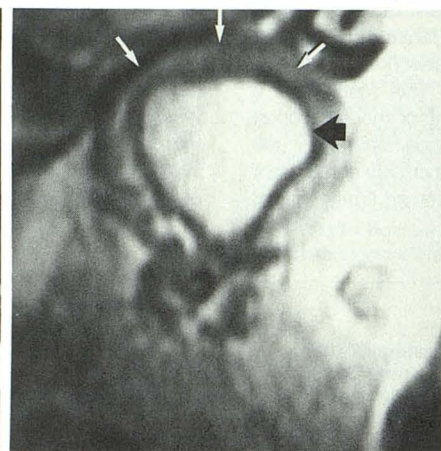
2

Fig. 1.—3-mm-thick axial slice shows eight slice locations selected in a perpendicular orientation to long axis of each condylar head.

Fig. 2.—3-mm-thick obliqued sagittal slice, closed-mouth view. Posterior band of meniscus (arrow) is in an anterior position relative to condyle.



3



4

Fig. 3.—3-mm-thick axial slice shows eight slice locations selected in a parallel orientation to long axis of each condylar head.

Fig. 4.—3-mm-thick obliqued coronal slice. Meniscus (white arrows) is in a normal position relative to condylar head (black arrow).



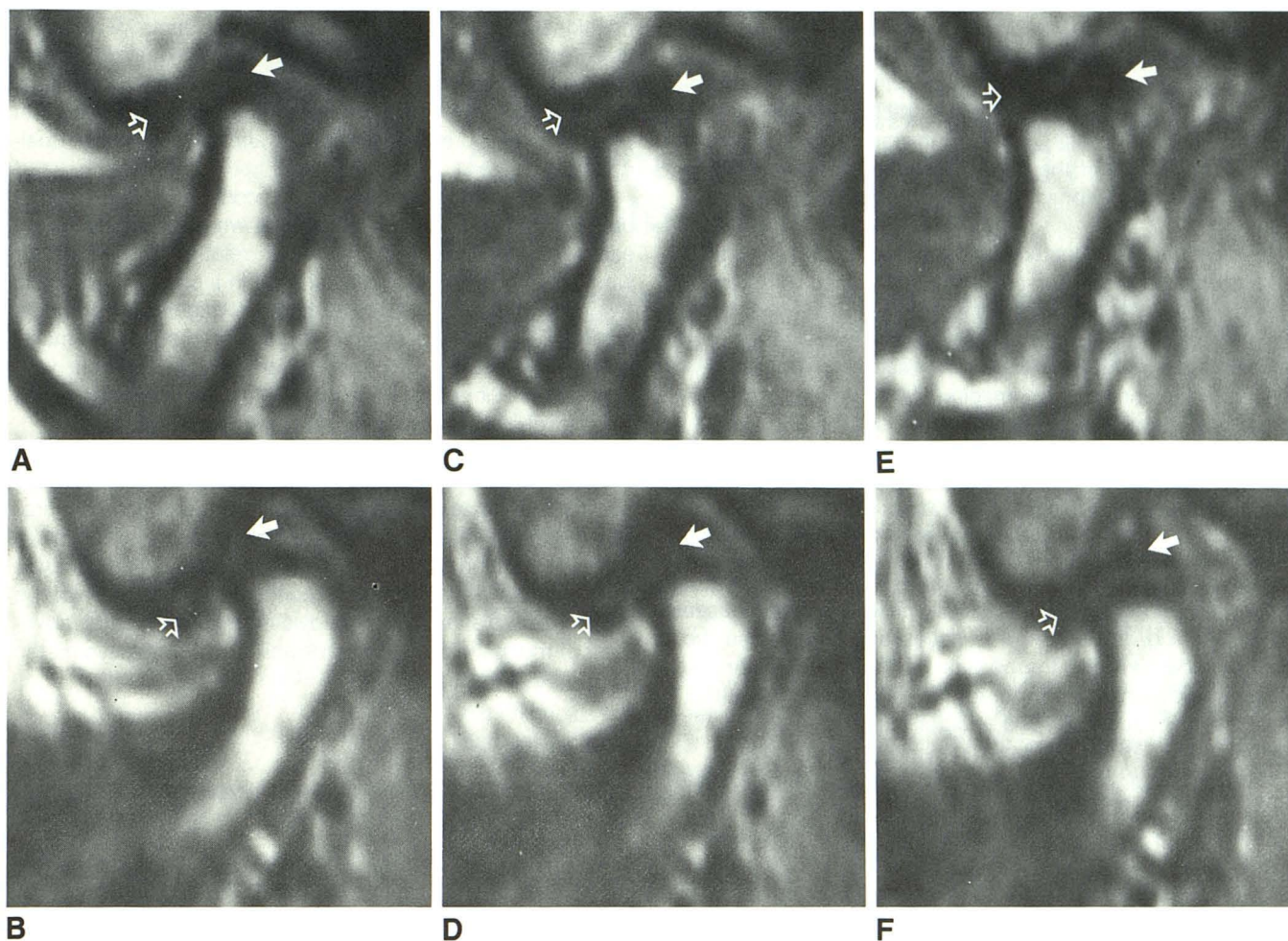


Fig. 5.—A–F, 3-mm-thick oblique sagittal mid-condylar slices obtained simultaneously from the right (top images, A, C, E) and left (bottom images, B, D, F) show TMJs with the mouth closed, 40% opened, and fully opened. The meniscus (anterior band = open arrows, posterior band = closed arrows) of the right TMJ is in a normal position in the closed-mouth view and the 40%-opened-mouth view. The fully opened mouth position shows a posterior displacement of the meniscus (anterior band = open arrow, posterior band = closed arrow).

The meniscus (anterior band = open arrows, posterior band = closed arrows) of the left TMJ in the closed-mouth position is in a slightly anterior position relative to the condyle compared with the meniscus of the right TMJ, but it is within normal limits. The meniscus (anterior band = open arrows, posterior band = closed arrows) translates with the condyle on the 40%-opened and fully opened mouth views. Note the difference in translation of the right compared with the left condyle relative to each articular eminence in the 40%-opened and fully opened mouth positions. Markedly disordered motion of the left TMJ was readily apparent by viewing the cine-loop display of the seven images acquired for the kinematic study. The patient had asymmetric mandibular motion with a right to left deviation during mouth opening.

## Results and Discussion

The technical quality of the images sufficiently depicted the meniscus, condyle, glenoid fossa, and articular eminence of the TMJ to provide a conclusive diagnosis in 53 of the 53 patients studied to date.

### Dual-Coil MR Imaging of Bilateral TMJs

Two major advantages to using dual surface coils were evident. First, there was a reduction in time of approximately 50% for the overall set-up and data acquisition. Second, the use of dual surface coils allowed images to be obtained simultaneously from the right and left TMJs so that a direct comparison could be made between the two joints at the

same degree of mouth opening. This was especially important for the detection of mandibular motion-related abnormalities [11] (see Fig. 5).

### Optimal Imaging Planes for Viewing the TMJ

The condyle of the TMJ is a relatively small structure that is situated in oblique angles in both sagittal and coronal planes [7]. Studies have indicated that the optimal orientation for images of the TMJ should be with reference to the long axis of the condylar head because a significant number of both normal subjects and patients have condyles that are asymmetric with respect to their size and orientation [4, 7, 8]. Using a cephalostat to position the patient's head, Laurell



et al. [8] demonstrated that consistent, standardized images of the TMJ could be obtained if selected at locations relative to the position of the condylar head. With the current availability of MR imaging graphic prescription software,\* image slice locations are easily obtained in any imaging plane so that optimal views of the TMJ can be acquired without the need for special anatomic positioning or the use of a cephalostat.

A recent study conducted by Westesson et al. [3] indicated that coronal plane imaging of the TMJ combined with sagittal views improved the accuracy of MR imaging for determining displacement of the meniscus. Medial or lateral displacement of the meniscus can be easily identified on coronal plane images [3]. In addition, this imaging plane is useful for evaluating bony anatomy and muscles of mastication [3].

#### *Kinematic MR Imaging of Bilateral TMJs*

There are several reasons why it is important to perform motion imaging of the TMJ. For example, in order to treat a patient with an anteriorly displaced meniscus that reduces during opening of the jaw, it is necessary to ascertain the point of recapture and the position of the mandible for the proper application of splint therapy [12]. If incorrectly initiated, splint therapy can actually be a factor in progression of TMJ dysfunction or, at the very least, may not correct it [12].

Examination of the TMJ by arthrography has demonstrated the importance of studying the motion aspects of the TMJ because of the similarity between normal variants and internal derangements that are observed on static closed-mouth studies [11]. Therefore, motion studies of the TMJ may also be useful for avoiding inaccurate diagnoses [11].

Since the mandible has a bilateral articulation with the cranium, both TMJs must function in synchrony and any asymmetric movement is regarded as an abnormality [7]. Therefore, the determination of asymmetric motion abnormalities also requires motion imaging. Considering all the above, the necessity of imaging the TMJ with a technique that shows the relationship between the meniscus and condyle through a range of motion of the mandible is obvious.

The inability of MR imaging to provide a functional assessment of jaw biomechanics and meniscus-condyle coordination was initially seen as a limitation of this imaging technique for evaluation of the TMJ [1-3]. Recently, Burnett et al. [9] made a significant contribution to MR imaging of the TMJ by using the partial flip angle technique to obtain images at multiple phases of mouth opening. However, because of the intrinsically poor spatial resolution of partial flip angle imaging, the meniscus appeared less prominent when compared with standard clinical pulse sequences (i.e., T1-weighted) used for imaging the TMJ [9]. Therefore, images acquired for the motion display lacked the resolution to clearly define the meniscus at each level of mouth opening. The technique described by Burnett et al. [9] frequently required time-consuming modifications of the flip angle for each procedure and only provided one slice location through the condyle. Of

additional concern is the fact that partial flip angle MR imaging is more likely to produce unacceptable image quality because it is particularly sensitive to background field inhomogeneities, such as those caused by metallic dental materials, and can produce other potentially misleading alterations in image quality [9].

Owing to the above problems and concerns, we elected to use T1-weighted, spin-echo imaging, which effectively delineated the meniscus and its position relative to the condyle whether or not the study was viewed in a static or kinematic MR imaging mode. Of note is that these images were acquired within a clinically acceptable length of time. Furthermore, asymmetric motion abnormalities are readily apparent with kinematic MR imaging, since both TMJs can be viewed at the same level of mouth opening [11] (see Fig. 5).

In conclusion, this MR imaging technique for examination of bilateral TMJs provided several advantages over previously described imaging protocols, including (1) a reduction in procedure time, (2) a decreased likelihood of motion artifacts, (3) a standardization of imaging planes oriented to the condylar head, (4) diagnostic information concerning the position of the meniscus in relation to the condyle during incremental movement of the mandible, and (5) the ability to detect asymmetric motion abnormalities.

#### REFERENCES

1. Harms SE, Wilk RM, Wolford LM, Chiles DG, Milam SB. The temporomandibular joint: magnetic resonance imaging using surface coils. *Radiology* 1985;157:133-136
2. Katzberg RW, Bessette RW, Tallents RH, et al. Normal and abnormal temporomandibular joint: MR imaging with surface coil. *Radiology* 1986;158:183-189
3. Westesson P-L, Katzberg RW, Tallents RH, Sanchez-Woodworth RE, Svensson SA. CT and MR of the temporomandibular joint: comparison with autopsy specimens. *AJR* 1987;148:1165-1171
4. Schellhas KP, Wilkes CH, Fritts HM, Omlie MR, Heithoff KB, Jahn JA. Temporomandibular joint: MR imaging of internal derangements and post-operative changes. *AJNR* 1987;8:1093-1101
5. Harms SE, Wilk RM. Bilateral surface coils for temporomandibular joint imaging. *Magn Reson Med Book of Abstracts* 1987;1:139
6. Sanchez-Woodworth RE, Tallents RH, Katzberg RW, Guay JA. Bilateral internal derangements of temporomandibular joint: evaluation by magnetic resonance imaging. *Oral Surg Oral Med Oral Pathol* 1988;65:281-285
7. Helms CA, Katzberg RW, Dolwick MF. *Internal derangements of the temporomandibular joint*. San Francisco: Radiology Research and Education Foundation, University of California Printing Department, 1983
8. Laurell KA, Tootle R, Cunningham R, Beltran J, Simon D. Magnetic resonance imaging of the temporomandibular joint. Part III: Use of a cephalostat for clinical imaging. *J Prosthet Dent* 1987;58:355-359
9. Burnett KR, Davis CL, Read J. Dynamic display of the temporomandibular joint meniscus by using "fast-scan" MR imaging. *AJR* 1987;149:959-962
10. Shellock FG, Mink JH, Fox J. Patellofemoral joint: kinematic MR imaging to assess tracking abnormalities. *Radiology* 1988;168:551-553
11. Pressman BD, Shellock FG, Tourje JE. Dual-coil MR imaging of temporomandibular joints: value in assessment of asymmetric motion abnormalities (abstr) *AJNR* (in press)
12. Manzione JV, Tallents RH, Katzberg RW, Oster C, Miller TL. Arthrographically guided therapy for recapturing the temporomandibular joint meniscus. *Oral Surg Oral Med Oral Pathol* 1984;57:235-240
13. Kaplan PA, Tu HK, Sleder PR, Lydiatt DD, Laney TJ. Inferior joint space arthrography of normal temporomandibular joints: reassessment of diagnostic criteria. *Radiology* 1986;159:585-589